

Finger clubbing, cirrhosis and portal hypertension in a sarcoidosis patient

Halil Yanardag¹, Cuneyt Tetikkurt², Muammer Bilir¹

¹Department of Internal Medicine Medicine, Cerrahpasa Medical Faculty, Istanbul Cerrahpasa University, Istanbul;

²Department of Pulmonary Medicine, Cerrahpasa Medical Faculty, Istanbul Cerrahpasa University, Istanbul, Turkey

Abstract

Sarcoidosis is a multisystem granulomatous inflammatory disorder frequently affecting the lungs, but also the liver, along with cirrhosis and portal hypertension occurring in less than 1% of the patients. A 56-year-old female presented with dyspnea, abdominal and leg swelling. Physical examination revealed finger clubbing, ascites and pretibial edema. Chest CT revealed diffuse micronodular opacities in both lungs without any enlarged thoracic lymph nodes. PFTs and DLCO/VA were moderately decreased. Transbronchial biopsy revealed non-caseified granulomas compatible with sarcoidosis. Serologic markers for infectious and autoimmune hepatitis were negative. Liver biopsy showed non-caseating granulomas, severe hepatitis and fibrosis. Stool, urinary analysis and antibodies for Schistosoma infection were negative. Final diagnosis was cirrhosis associated with stage III sarcoidosis. We report a case of sarcoidosis complicated by cirrhosis and portal hypertension with finger clubbing. Clinicians should bear in mind

that cirrhosis, portal hypertension and clubbing may arise as the initial manifestations of sarcoidosis.

Introduction

Sarcoidosis is a chronic disease of unknown origin characterized by the presence of non-caseating granulomas that can involve all organ systems to a varying extent and degree. Sarcoidosis affects the lungs in approximately 90% to 95% of the patients [1-3]. Liver is the third most commonly involved organ after the lungs and the lymph nodes [4-6]. Cirrhosis and portal hypertension are unusual manifestations of sarcoidosis occurring in less than 1% of the sarcoidosis patients [1,4]. Sarcoidosis presenting as chronic liver disease is uncommon, although hepatic granulomas can be identified in approximately two thirds of the patients with systemic sarcoidosis. Liver involvement in sarcoidosis is usually asymptomatic and follows a benign course in most of the patients. Diagnosis frequently poses difficulties because the laboratory tests or the clinical manifestations are not definitively pathognomonic. On the other hand, cirrhosis is a very rare complication emerging in less than 1% of the patients with only a few patients developing portal hypertension [4,6,7].

Cirrhosis with portal hypertension due to liver sarcoidosis may come out as a diagnostic challenge for the clinician. We present a case of liver sarcoidosis presenting with finger clubbing, cirrhosis and portal hypertension as the initial manifestations of the disease along with review of the literature.

Case Report

A 56-year-old Caucasian woman was admitted for the evaluation of finger clubbing, abdominal swelling, bilateral pretibial and ankle edema. Personal and family history were excellent. The patient did not have any exposure to drugs or occupational agents. She was a non-smoker. Physical examination revealed finger clubbing (Figure 1), ascites, hepatomegaly of 2 cm below the costal margin, bilateral pretibial and ankle edema. Blood pressure was 120/80 mmHg. Chest examination was normal with a respiratory rate of 16/min. Laboratory revealed a normal blood count (WBC: 5.8×10^3 cells/mm³, Hgb: 12.6 g/dl, ESR: 24 mm/h, AST: 82 U/l, ALT: 52 U/l, ALP: 188 U/l, GGT: 52 U/l, total bilirubin: 1.84 mg/dl, direct bilirubin: 0.80 mg/dl, total protein: 7.54 g/dl, albumin: 2.56 g/dl, and PT: 14.8 seconds. Serum ACE was 160 U/l. Tuberculin test was negative.

Chest X-ray (Figure 2a) and thorax CT revealed diffuse micronodules (Figure 2b) and there was no detectable thoracic lymph node

Correspondence: Prof. Cuneyt Tetikkurt, Department of Pulmonary Medicine, Cerrahpasa Medical Faculty, Istanbul Cerrahpasa University, Tanzimat Sok. Serkan Apt. No:8/16, 34728 Caddebostan, Istanbul, Turkey.
Tel. +90.216.3601977 - Fax: +90.212.5870217.
E-mail: tetikkurt@gmail.com

Conflict of interest: the authors declare no conflict of interest.

Contributions: HY, case report design and data preparation; CT, case report data organization, manuscript drafting; MB, literature search. All the authors gave substantial intellectual contribution, read and approved the final version to be published and are accountable for all aspects.

Key words: Cirrhosis; liver failure; finger clubbing; sarcoidosis; portal hypertension.

Received for publication: 1 August 2019.
Accepted for publication: 6 October 2019.

©Copyright: the Author(s), 2019
Licensee PAGEPress, Italy
Monaldi Archives for Chest Disease 2019; 89:1141
doi: 10.4081/monaldi.2019.1141

This article is distributed under the terms of the Creative Commons Attribution Noncommercial License (by-nc 4.0) which permits any noncommercial use, distribution, and reproduction in any medium, provided the original author(s) and source are credited.

enlargement. Transbronchial and bronchial biopsies revealed non-caseating granulomatous inflammation. BAL culture for bacteria, fungus and mycobacteria was negative. Abdomen CT revealed hepatomegaly and ascites. The ascites was transudative with a 1.8 serum-ascites albumin gradient. Liver biopsy revealed loose epithelioid non-caseating granulomas and fibrosis compatible with sarcoidosis. Serologic markers for viral hepatitis HBC, HCV and HDV did not reveal infection. Serologic markers of KLM, ANA, ASMA, AKLM-1, ALC-1 for autoimmune hepatitis were negative. Pulmonary function tests were within normal limits (FEV1:106%,

lioid non-caseating granulomas and fibrosis compatible with sarcoidosis. Serologic markers for viral hepatitis HBC, HCV and HDV did not reveal infection. Serologic markers of KLM, ANA, ASMA, AKLM-1, ALC-1 for autoimmune hepatitis were negative. Pulmonary function tests were within normal limits (FEV1:106%,

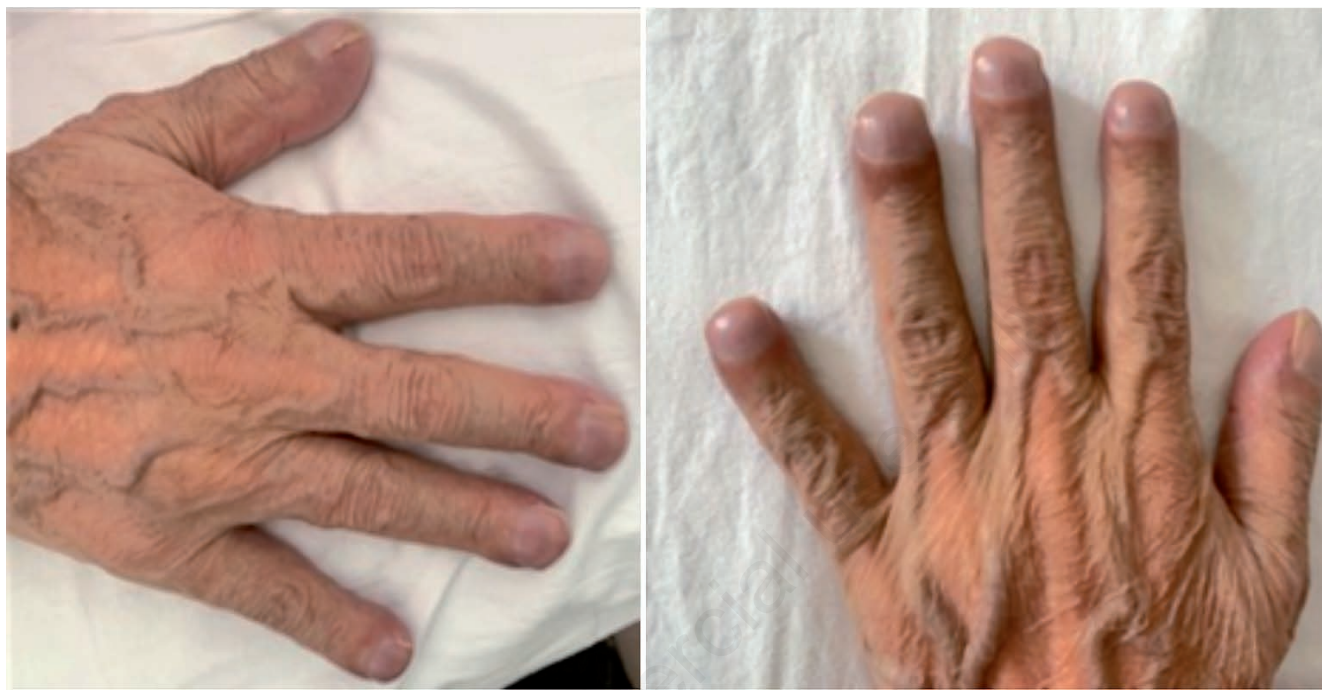

Figure 1. Finger clubbing.

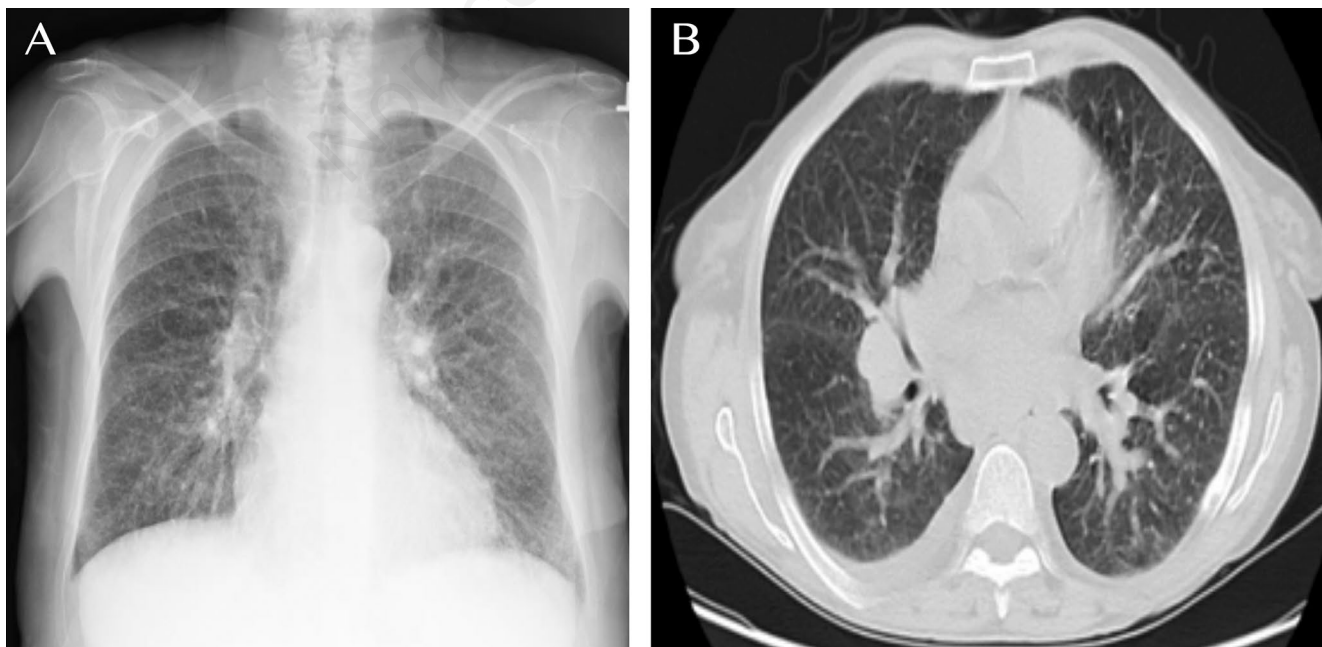


Figure 2. Chest X-ray (a) and thorax CT (b) revealing diffuse micronodules in both lungs.

FVC: 96%, FEV1/FVC: 94%, DLCO: 86%, and DLCO/VA:82%). Screening for systemic rheumatologic disease with ANA, RF, Anti-ds-DNA, Anti-Sm, Anti-SSA, Anti-Scl-70, and, Anti-Jo-1 was negative. Endoscopic examination revealed grade I varices in the esophagus. Stool, urinary analysis and detection of antibodies to *Schistosoma mansoni*, *S. haematobium*, and *S. japonicum* adult worm microsomal antigens by ELISA revealed negative results for infection. The final diagnosis was sarcoidosis stage III complicated by cirrhosis and portal hypertension. The patient was commenced on oral methylprednisolone and furosemide.

Discussion

Sarcoidosis is a systemic granulomatous disease characterized by the presence of non-caseating granulomas that may involve any organ. Liver involvement is frequent (35%) ranging from asymptomatic incidental hepatic granulomas with mild liver function abnormalities to severe hepatic disease. Liver sarcoidosis may lead to portal hypertension due to the granulomas in the portal triad but cirrhosis is a rare complication of sarcoidosis [4,5,8]. After the first two cases were described in 1949 by Mino and by Katskin in 1950 [9,10], sarcoidosis with cirrhosis has been increasingly reported [4,7,11,12]. Our patient presented with finger clubbing, cirrhosis and portal hypertension as the preliminary manifestations of sarcoidosis at the initial setting. Personal history did not reveal any other previous diseases. The high serum ACE supported the diagnosis of sarcoidosis. Diseases that may cause cirrhosis including infectious and autoimmune hepatitis were excluded in the differential diagnosis while there was no history of exposure to drugs or occupational agents. Sarcoidosis presenting with cirrhosis, portal hypertension and finger clubbing has not been reported previously. As far as we know, this is the first case in literature presenting with these manifestations.

The patient did not have any pulmonary or extrapulmonary symptoms or manifestations associated with sarcoidosis. The only laboratory finding relevant to sarcoidosis was the high serum ACE level. The liver failure dominated the clinical picture as finger clubbing, cirrhosis and portal hypertension arose as the initial manifestations of sarcoidosis in this patient. High serum ACE was the only clue to the sarcoidosis diagnosis as an indirect laboratory evidence of the disease. It is well known that cirrhosis and many other diseases may also lead to elevated ACE levels. Consequently, high serum ACE level was an equivocal finding from the diagnostic point of view in our patient as finger clubbing, ascites and portal hypertension dominated the clinical picture thereby indicating a differential diagnosis for liver failure which is extremely rare in sarcoidosis, especially as the presenting manifestation of the disease. On the other hand, the pathogenesis of finger clubbing in our patient is unknown, which may be due to sarcoidosis, cirrhosis or both.

At presentation, 90% to 95% of sarcoidosis patients have pulmonary disease and up to 50% of the cases have skin, liver, peripheral lymph node or eye involvement. Conversely only 2% of the cases have extrapulmonary disease without pulmonary involvement [1,3]. Cirrhosis occurs in less than 1% of the patients that may lead to portal hypertension in 3% of the patients [6-10,13]. Due to the absence of any specific clinical or laboratory findings and its variable manifestations, diagnosis of liver sarcoidosis poses diagnostic difficulties for the clinician. The final diagnosis of sarcoidosis was confirmed by the presence of sarcoid granulomas in the histopathologic examination of the transbronchial lung and liver biopsy specimens. Advanced liver disease presenting with cirrhosis, ascites and

portal hypertension as the initial clinical findings in sarcoidosis is extremely rare in literature [7,14,15]. Our patient presented with cirrhosis and portal hypertension as the preliminary manifestations that pointed out to more common liver disorders than sarcoidosis causing a diagnostic dilemma for the clinician.

Liver sarcoidosis is often difficult to diagnose considering the absence of any specific laboratory or radiologic findings, and its variable manifestations, especially when the lungs are uninvolved. No precise guidelines are available for the diagnosis of hepatic sarcoidosis to date. Diagnosis is achieved by clinical and radiologic findings suggestive of sarcoidosis, supported by the presence of non-caseating granulomas in the liver biopsy specimens with exclusion of other etiologies for granuloma formation [10]. Histopathologic examination of the liver biopsy samples was compatible with sarcoidosis and cirrhosis leading to the final diagnosis in our patient. After a literature search and as far as we know, this is the fourth case of sarcoidosis complicated by cirrhosis and portal hypertension as the initial findings of the disease [7,14,15]. Diagnosis of liver involvement in sarcoidosis may be difficult because it may be asymptomatic, may cause only mild symptoms or may have a wide spectrum of presentations since there are no definitively pathognomonic laboratory or imaging findings [15]. Presence of finger clubbing, cirrhosis and portal hypertension presenting as the initial clinical manifestations of sarcoidosis is a challenge for the clinician. This patient is the first case in literature revealing three extremely unusual and rare manifestations of sarcoidosis.

Conclusions

Liver sarcoidosis is usually a self-limiting disorder that usually ensues with mild enzyme elevation causing no further comorbidities. Sarcoidosis leading to cirrhosis and portal hypertension occurs hardly, if ever. Clinicians should bear in mind that although liver sarcoidosis usually follows a benign and a self-limiting course, it may lead to severe liver involvement with cirrhosis, portal hypertension and along with finger clubbing as the initial manifestations.

References

- Thomas KW, Hunninghake GW. Sarcoidosis. JAMA 2003; 289:3300.
- Baughman RP, Lower EE, du Bois RM. Sarcoidosis. Lancet 2003;361:1111- 8.
- Baughman RP, Teirstein AS, Judson MA, et al. Clinical characteristics of patients in a case control study of sarcoidosis. Am J Respir Crit Care Med 2001;164:1885-9.
- Blich M, Edoute Y. Clinical manifestations of sarcoid liver disease. J Gastroenterol Hepatol 2004;19:732-7.
- Ebert EC, Kierson M, Hagspiel KD. Gastrointestinal and hepatic manifestations of sarcoidosis. Am J Gastroenterol 2008;103: 3184-92.
- Blich M, Edoute Y. Clinical manifestations of sarcoid liver disease. J Gastroenterol Hepatol 2004;19:732-7.
- Tan CB, Rashid S, Rajan D, et al. Hepatic sarcoidosis presenting as portal hypertension and liver cirrhosis; case report and review of the literature. Case Rep Gastroenterol 2012;6:183-9.
- J Cremers, M Drent, A Driessen, et al. Liver test abnormalities in sarcoidosis. Eur J Gastroenterol Hepatol 2012;24:17-24.
- Mino RA, Murphy AI, Livingstone RG. Sarcoidosis producing

- portal hypertension: Treatment by splenectomy and splenorenal shunt. *Ann Surg* 1949;130:951-7.
- Klatskin G, Yesner R. Hepatic manifestations of sarcoidosis and other granulomatous diseases; a study based on histological examination of tissue obtained by needle biopsy of the liver. *Yale J Biol Med* 1950;23:207-48.
- Gavilan F, Pereda T, Sousa JM et al. Hepatic sarcoidosis with sarcoid granulomas. Differential diagnosis and liver transplantation: A case report. *Transplant Proc* 2003;35:713-4.
- Bass NM, AK Burroughs, PJ Scheuer, et al. Chronic intrahepatic cholestasis due to sarcoidosis. *Gut* 1982;23:417-21.
- Devaney K, Goodman ZD, Epstein MS, et al. Hepatic sarcoidosis. Clinicopathologic features in 100 patients. *Am J Sur Pathol* 1993;17:1272-80.
- Gupta S, Faughman ME, Prudhomme GJ, et al. Sarcoidosis complicated by cirrhosis and hepatopulmonary syndrome. *Can Respir Jour* 2008;15:124-6.
- Yanardag H, Tetikkurt C, Bilir M, et al. A case of sarcoidosis presenting as cirrhosis and portal hypertension. *Brit J Med Medical Res* 2014;4:4272-7.

Non-commercial use only