

# Tuberculous pancreatitis complicated by ruptured splenic artery pseudoaneurysm

M. Irfan<sup>1</sup>, F. Thiavalappil<sup>1</sup>, J. Nagaraj<sup>1</sup>, T.H. Brown<sup>2,4</sup>,  
D. Roberts<sup>3</sup>, L. Mcknight<sup>3,4</sup>, N.K. Harrison<sup>1,4</sup>

**ABSTRACT:** *Tuberculous pancreatitis complicated by ruptured splenic artery pseudoaneurysm. M. Irfan, F. Thiavalappil, J. Nagaraj, T.H. Brown, D. Roberts, L. Mcknight, N.K. Harrison.*

Tuberculosis involving the pancreas is rare. We report a patient with pancreatic tuberculosis complicated by haemorrhage from a splenic artery pseudoaneurysm. As

far as we are aware, the development of a splenic artery pseudoaneurysm in association with a large caseating mass of tuberculous pancreatic lymph nodes has not been reported previously. We review the literature and discuss the varied presentations of tuberculosis involving the pancreas or the pancreatic bed and its draining lymph nodes. *Monaldi Arch Chest Dis 2013; 79: 3-4, 134-135.*

**Keywords:** *Tuberculosis, Pancreatitis, Splenic artery pseudoaneurysm.*

<sup>1</sup> Respiratory Unit, Morriston Hospital, Swansea;

<sup>2</sup> Department of Surgery, Morriston Hospital, Swansea;

<sup>3</sup> Department of Radiology, Morriston Hospital, Swansea;

<sup>4</sup> College of Medicine, Swansea University, Singleton Park, Swansea, UK.

Correspondence: Dr M. Irfan, Specialty training registrar, Dept of Respiratory Medicine, Room 1021, First floor, Glan Clwyd Hospital, Rhyl, Wales, UK, LL18 5UJ; e-mail: mujammil76@doctors.org.uk

Tuberculosis involving the pancreas is rare. We report a patient with pancreatic tuberculosis complicated by haemorrhage from a splenic artery pseudoaneurysm.

A 33-yr-old Eritrean man was admitted with abdominal pain and fever. He gave a six month history of anorexia, weight loss of 37 kg, vomiting and drenching night sweats. Three days before admission he had developed unsteadiness of gait. He had lived in the UK for six years. He was an ex-smoker of five cigarettes per day and worked in a warehouse. His past medical history included malaria aged 25. Three months before admission he had been investigated at another hospital for similar symptoms. A computed tomography (CT) scan at that time revealed mediastinal and intra-abdominal lymphadenopathy (figure 1a). Whilst it was suspected he might have a lymphoma, microscopic examination of a bone marrow aspirate and a CT scan guided core biopsy of an intra-abdominal node showed caseating granulomata and in the latter, acid fast bacilli (AFB) were demonstrated by Ziel-Nielsen stain although samples had not been cultured for mycobacteria. He was referred to a chest clinic but defaulted and was lost to follow-up.

At the time he re-presented, physical examination revealed an emaciated man with a temperature of 38.5°C. He had palpable, non tender posterior cervical lymphadenopathy and mild epigastric tenderness on palpation of the abdomen but physical examination was otherwise unremarkable.

Investigations revealed a haemoglobin of 11.9 g/dl and white cell count of 8.2x 10<sup>3</sup>/µl. His renal

function was normal. Liver function tests showed alkaline phosphatase of 245 U/l (normal range 40-129 U/l) and alanine aminotransferase of 16 U/l (<41 U/l). His serum amylase was 102 U/l (<100 U/l) and a human immunodeficiency virus (HIV) screen was negative. A CT scan of the brain showed a ring enhancing lesion in the mid-brain and possible meningeal enhancement. These findings were later confirmed by magnetic resonance imaging. An upper gastrointestinal endoscopy revealed normal gastric and duodenal mucosa but there was evidence of extrinsic compression of the pylorus.

As the earlier biopsies strongly suggested a diagnosis of mycobacterial infection a needle aspirate of a cervical lymph node was performed and cultured for AFB. He was then treated with quadruple therapy using appropriate doses of rifampicin, isoniazid, ethambutol and pyrazinamide together with and pyridoxine 10 mg daily and dexamethasone 4mg twice daily.

He continued to complain of severe abdominal pain. Repeat serum amylase was elevated at 620 U/l and alkaline phosphatase at 303 U/l. A CT scan revealed the abdominal lymph nodes had increased in size and in close proximity there was a large mass. The latter had the appearance of a retroperitoneal haematoma with intense central enhancement suggestive of a splenic artery pseudoaneurysm (figure 1b).

This pseudoaneurysm was embolised with coils but it was only possible to occlude the aneurysm and not the artery beyond it.

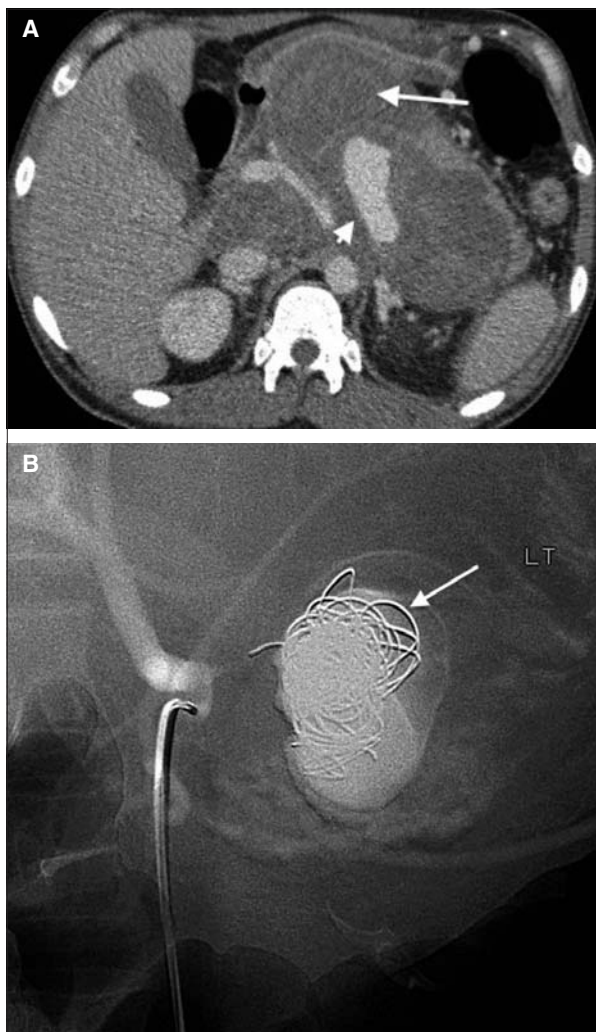


Fig. 1. - A) A large haematoma lies between the aorta and left lobe of liver extending to the spleen (arrow) with central enhancement of the pseudoaneurysm (arrow head). B) A coeliac axis angiogram showing normal flow in the hepatic artery and coils in the aneurysm (arrow).

His abdominal pain initially improved but recurred 20 days into treatment. Repeat abdominal CT scan confirmed further bleeding into the pseudoaneurysm. An emergency laparotomy showed a large haematoma pushing the stomach forward. The lesser sac was opened with careful dissection onto the tail of pancreas and splenic hilum. The feeding vessels were ligated by passing sutures just distal to the tail of pancreas to surround the splenic artery and vein at the splenic hilum. The proximal coeliac vessels were not explored as the coeliac axis was impossible to access without entering the haematoma.

Thereafter, the patient made a steady recovery regaining his appetite and weight. Culture of the lymph node aspirate subsequently grew *Mycobacterium tuberculosis* which was fully sensitive to all first line drugs.

### Discussion

Tuberculosis (TB) involving the pancreas or the pancreatic bed and its draining lymph nodes is rare and the majority of cases have been described in patients infected with human immunodeficiency

virus [1]. There are several ways in which the pancreas may be affected by tuberculosis [2]. These are; haematogenous spread following primary infection; physical encroachment by adjacent caseating pancreatic lymph nodes and a toxic allergic reaction of the pancreas to generalised TB – so called ‘concomitant pancreatitis’. Furthermore, isoniazid – induced pancreatitis has also been described during treatment of TB [3].

Pancreatic and peri-pancreatic nodal TB can present with a wide spectrum of symptoms including upper abdominal pain with elevated serum amylase, obstructive jaundice mimicking pancreatic carcinoma, pancreatic abscess refractory to conventional antibiotic therapy, massive gastrointestinal haemorrhage due to duodenal wall erosion, splenic vein thrombosis and chronic pancreatitis [4-6].

As far as we are aware, the development of a splenic artery pseudoaneurysm in association with a large caseating mass of tuberculous pancreatic lymph nodes has not been reported previously. Indeed, there has been only one reported case of splenic artery pseudoaneurysm caused by tuberculosis and this was associated with tuberculous gastritis [7].

Tuberculous involvement of blood vessels may manifest as miliary TB of the intima, tubercular polyps attached to the intima, infiltration of all layers of the arterial wall, aneurysm formation, and arterial stenosis [8]. Tubercular aneurysms are mostly pseudoaneurysms (87%) and only rarely, true (9%) or dissecting (4%) aneurysms [8]. Unlike the aorta or peripheral arteries, aneurysms and pseudoaneurysms of the splanchnic arteries are very rare and when caused by infection, arise as a result of septic emboli or infiltration from an adjacent infectious organ or lymph node mass as in the case here described.

### References

1. Meesiri S. Pancreatic tuberculosis with acquired immunodeficiency syndrome: a case report and systematic review. *World J Gastroenterol* 2012; 18: 720-6.
2. Stock KP, Riemann JF, Stadler W, Rösch W. Tuberculosis of the pancreas. *Endoscopy* 1981; 13: 178-80.
3. Mattioni S, Zamy M, Mechai F, et al. Isoniazid-induced recurrent pancreatitis. *JOP* 2012; 13: 314-6.
4. Woodfield JC, Windsor JA, Godfrey CC, Orr DA, Officer NM. Diagnosis and management of isolated pancreatic tuberculosis: recent experience and literature review. *ANZ J Surg* 2004; 74: 368-371.
5. Raghavan P, Rajan D. Isolated pancreatic tuberculosis mimicking malignancy in an immunocompetent host. *Case Rep Med* 2012; 2012: 501246.
6. Xia F, Poon RT, Wang SG, Bie P, Huang XQ, Dong JH. Tuberculosis of pancreas and peripancreatic lymph nodes in immunocompetent patients: experience from China. *World J Gastroenterol* 2003; 9: 1361-4.
7. Jae Kyu Kim, Seok Kyun Chung, Woong Yoon, Yong Yeon Jeong, Heoung Keun Kang. Hematemesis due to a Pseudoaneurysm of the Splenic Artery Secondary to Gastric Tuberculosis. *Cardiovasc Intervent Radiol* 2005; 28: 506-508.
8. Choudhary SK, Bhan A, Talwar S, Goyal M, Sharma S, Venugopal P. Tubercular pseudoaneurysm of aorta. *Ann Thorac Surg* 2001; 72: 1239-1244.