

Chronic granulomatous 'Aspergillus lung mass'

Kavitha Venkatnarayan¹, Uma Devaraj¹, Uma Maheswari Krishnaswamy¹, Priya Ramachandran¹, Sreekar Balasundaram², Anuradha Ananthamurthy³, Jayanthi Savio⁴

¹Department of Pulmonary Medicine; ²Department of Cardiothoracic Surgery; ³Department of Pathology; ⁴Department of Microbiology, St. John's National Academy of Health Sciences, Bengaluru, India

Abstract

The diverse clinicopathological spectrum of pulmonary aspergillosis is a consequence of varying levels of invasiveness of this ubiquitous fungus, which largely depends on the host immune response and pre-existing lung disease. The clinical presentation

of pulmonary aspergillosis spans a wide spectrum from hypersensitivity to life threatening angio-invasive and disseminated disease.

We report the case of a young immunocompetent male with no underlying lung disease, who presented with an incidentally detected 'infective mass' lesion in the lung associated with minimal respiratory symptoms. The diagnostic challenges posed by the unusual clinical, radiological and histological picture as well as the therapeutic dilemmas faced are discussed in this report.

Correspondence: Dr Kavitha Venkatnarayan, Department of Pulmonary Medicine, 3rd floor, Oncology Block, St John's National Academy of Health Sciences, Sarjapur Road Bengaluru 560034, India.
Tel. +91.9013770826.
E-mail: kavaiiims@gmail.com

Keywords: Aspergillosis; lung lesion; lung resection.

Contributions: All the authors have contributed towards patient diagnosis and management and manuscript preparation and revision. All the authors have read and approved the final version of the manuscript and agreed to be accountable for all aspects of the work.

Ethics approval and consent to participate: No ethical committee approval was required for this case report by the Department, because this article does not contain any studies with human participants or animals.

Consent for publication: The patient gave his written consent to use his personal data for the publication of this case report and any accompanying images.

Conflict of interest: The authors have no conflicts of interest to disclose.

Funding: No funding obtained in relation to the above manuscript.

Acknowledgments: the authors would like to thank Dr. David Denning for his expert opinion on the case and suggesting the title of the article.

Received for publication: 11 May 2020.

Accepted for publication: 7 July 2020.

©Copyright: the Author(s), 2020

Licensee PAGEPress, Italy

Monaldi Archives for Chest Disease 2020; 90:1371

doi: 10.4081/monaldi.2020.1371

This article is distributed under the terms of the Creative Commons Attribution Noncommercial License (by-nc 4.0) which permits any noncommercial use, distribution, and reproduction in any medium, provided the original author(s) and source are credited.

Introduction

There has been an exponential increase in the burden of fungal infections in the recent years owing to an increase in the 'at-risk' population [1,2]. This is secondary to the global increase in people living with HIV-AIDS, advances in the medical care of patients with malignancies, increase in the number of transplants, increased use of immunosuppressants and steroids for various conditions and indiscriminate use of antibiotics in critical care [2]. Apart from the well-recognized manifestations including aspergilloma, chronic pulmonary aspergillosis (CPA), invasive pulmonary aspergillosis and allergic bronchopulmonary aspergillosis, advances in diagnostic modalities and increasing knowledge of fungal infections has led to the identification of unusual presentations of the same. This case report illustrates the expanding spectrum of CPA and the importance of identifying and appropriately managing unusual presentations of the same.

Case Report

A 34-year-old gentleman, who was a non-smoker with no comorbid illnesses, presented with right-sided chest pain for 1 month and 3 episodes of streaky hemoptysis. He had no fever, breathlessness, anorexia or weight loss. However, he had been informed of an abnormality in his chest radiogram during a pre-employment health check 4 months earlier, for which he sought no medical attention as he had no symptoms at that time.

On examination, he was afebrile with stable vital parameters. Respiratory examination revealed a leftward shift of the trachea and a visible bulge in the right infraclavicular, suprascapular and upper interscapular regions. The above areas were dull to percuss with diminished intensity of breath sounds. Blood investigations were within the normal range. HIV serology was negative. Chest radiogram showed a homogeneous opacity with rounded, smooth margins in right upper and midzone (Figure 1). Chest CT scan revealed right upper lobe soft tissue lesion measuring

7.8x8.2x11.7 cm with few scattered areas of hypoattenuation. A similar hilar component measuring 5.3x5.9x7.2 cm was also noted. The lesion had a smooth interphase with adjacent lung parenchyma with erosion of posterior aspect of the 4th rib (Figure 2). Radiologically, a possibility of a solitary fibrous tumor of the pleura was considered.

An ultrasound guided biopsy was done which to our surprise showed necrosis with septate fungal hyphae with no evidence of malignancy. To confirm the findings another biopsy was per-

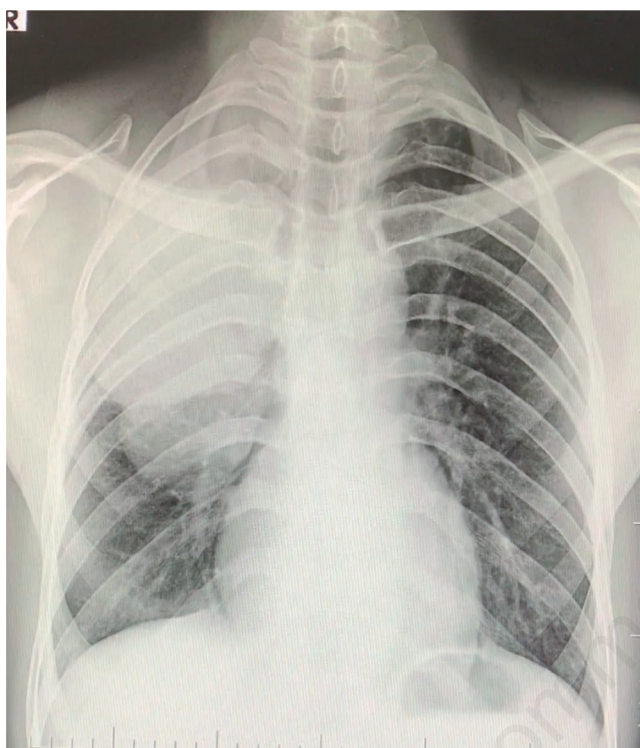


Figure 1. Chest radiograph showing a homogenous well-defined opacity in right upper and middle zone.

formed which also showed similar findings and grew *Aspergillus* species on culture. Serum galactomannan levels were 3.3. In view of discordance between the clinical presentation, radiological picture and histopathological findings, the patient was scheduled for surgical excision of the lesion. A bilobectomy was planned however, an informed consent was taken for right pneumonectomy also based on the intra-operative findings. Intra-operatively, there was a 10x8 cm hard, nodular mass involving the right upper and middle lobes which was adherent to the pleura, posterior aspect of the 3rd and 4th ribs and extended to the hilum, encasing the hilar vessels. Malignancy could not be conclusively ruled out on frozen sections from the lesion. A right pneumonectomy with partial resection of 3rd and 4th ribs and intrapericardial ligation of hilar vessels was performed. Histopathological examination of the specimen and surrounding pleura showed areas of necrosis with lymphoplasmacytic infiltrates with numerous multinucleate giant cells with septate hyphae. There was no evidence of vascular invasion or infiltration of the excised ribs (Figure 3). Post operatively, patient was started on oral voriconazole in view of the raised serum galactomannan. In view of extensive granulomatous inflammation on histopathology, a nitroblue-tetrazolium test was done which showed normal neutrophil oxidative function. *Aspergillus* specific IgG was 37U/ml. Though there was no evidence of surrounding tissue invasion, antifungal therapy was continued for 3 months as we were unsure of the nature and course of the disease process. On last follow up, 5 months after surgery patient is stable and asymptomatic.

Discussion

The key determinants of the spectrum of diseases caused by *Aspergillus* species are host immune response, pre-existing lung pathology and genetic predisposition [3]. The potentially life-threatening variant, invasive aspergillosis is seen in immunocompromised hosts. Chronic pulmonary aspergillosis (CPA), whose clinical presentation can vary from indolent symptoms to massive hemoptysis is commonly seen in immunocompetent individuals. The sub-types of CPA include aspergilloma, chronic cavitating and fibrosing aspergillosis. While aspergilloma forms in a pre-existing

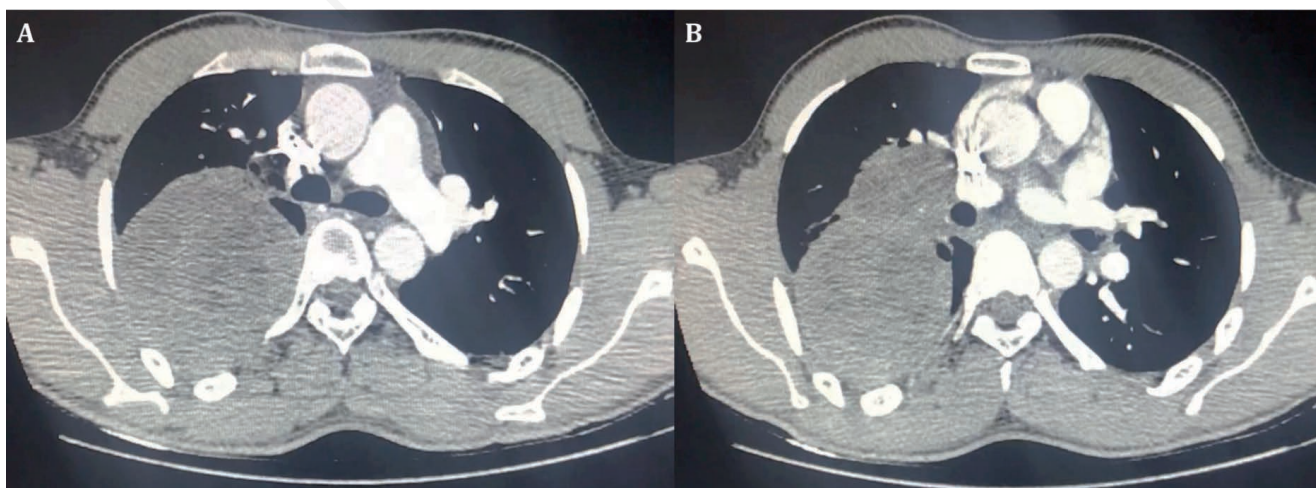


Figure 2. Chest CT images showing a right upper lobe soft tissue lesion with few areas of hypoattenuation.

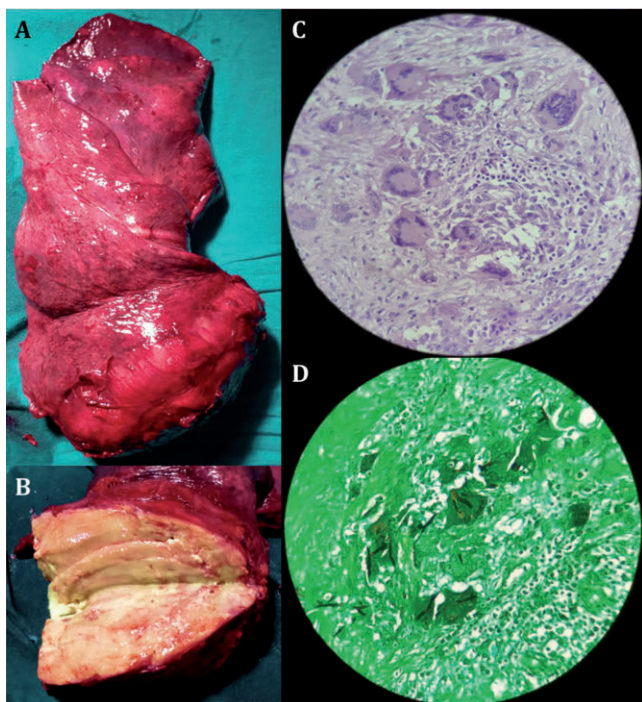


Figure 3. Gross and histopathology images showing pneumonectomy specimen with upper lobe mass lesion (A), cut section of the mass lesion (B), giant cell response on hematoxylin and eosin stain (C) (original magnification 40x), and Gomori methenamine silver stain showing branching fungal hyphae within the giant cells (D) (original magnification 40x).

cavity and can have no symptoms or progression over time, chronic cavitating and fibrosing aspergillosis present with pulmonary and systemic symptoms with pulmonary cavities and fibrosis respectively, with microbiological and serological evidence of *Aspergillus* infection [4]. An unusual form of CPA is an *Aspergillus* nodule (size range of 1-50mm) which presents with one or more lung nodules with necrosis and granulomatous inflammation on histopathology without tissue invasion. These nodules may be misdiagnosed as malignancy and are diagnosed as CPA only after a biopsy or lung resection [3,4].

There are anecdotal case reports of *Aspergillosis* presenting as a mass in immunocompetent as well as immunocompromised hosts. Some of the presentations described are mediastinal mass presenting as superior venacaval obstruction, fibrosing mediastinitis, post-operative mediastinitis and suture granulomas mimicking

recurrence of neoplastic growth [5-8].

Although a lot of complexity exists in the formation and function of aspergillosis related granulomas, the latter is postulated to be a protective phenomenon helping wall off infection. [9] Our patient presented with a lung mass with extensive granulomatous inflammation with no evidence of tissue or angioinvasion. Rib erosion was probably a pressure effect as there were no fungal elements identifiable on histological exam. This was unlikely to be an aspergilloma as fungal elements were seen in the granulomatous mass rather than in a pre-existing cavity. Although serum galactomannan levels were marginally elevated, invasive aspergillosis was also unlikely given the timeline of presentation and the patient being asymptomatic with no evidence of invasion on histopathology.

Thus, based on the clinico-pathological findings, we postulated that an exaggerated immune response to *Aspergillus* led to formation of the huge granulomatous mass lesion, which could be considered an unusual manifestation of CPA. Another speculation was if an *Aspergillus* nodule which is reported to have similar pathologic findings can form a mass of this size.

References

- Bongomin F, Gago S, Oladele RO, Denning DW. Global and multi-national prevalence of fungal diseases-estimate precision. *J Fungi (Basel)* 2017;3:57.
- Vallabhaneni S, Mody RK, Walker T, Chiller T. The global burden of fungal diseases. *Infect Dis Clin North Am* 2016;30:1-11.
- Muldoon EG, Sharman A, Page I, et al. *Aspergillus* nodules; another presentation of chronic pulmonary aspergillosis. *BMC Pulm Med* 2016;16:123.
- Denning DW, Cadranet J, Beigelman-Aubry C, et al. Chronic pulmonary aspergillosis: rationale and clinical guidelines for diagnosis and management. *Eur Respir J* 2016;47:45-68.
- Shlobin OA, Dropulic LK, Orens JB, et al. Mediastinal mass due to *aspergillus fumigatus* after lung transplantation: A case report. *J Heart Lung Transplant* 2005;24:1991-4.
- Rahim Y, Memon A, Khan JA. Invasive mediastinal aspergillosis presenting as superior vena cava syndrome in an immunocompetent patient. *BMJ Case Rep* 2018;2018:bcr2018225614.
- Wightman SC, Kim AW, Proia LA, et al. An unusual case of aspergillus fibrosing mediastinitis. *Ann Thorac Surg* 2009;88:1352-4.
- Pasqualotto AC, Denning DW. Post-operative aspergillosis. *Clin Microbiol Infect* 2006;12:1060-76.
- Pagán AJ, Ramakrishnan L. The formation and function of granulomas. *Annu Rev Immunol* 2018;36:639-65.