

Occult carcinoma penis presenting as malignant pleural effusion

Ramakant Dixit¹, Mukesh Goyal¹, Kamendra Singh Pawar², Neena Kasliwal³, Shreya Agarwal⁴

¹Department of Respiratory Medicine, Jawaharlal Nehru Medical College, Ajmer; ²Department of Respiratory Medicine, Sri Aurobindo Institute of Medical Sciences, Indore; ³Department of Pathology, Jawaharlal Nehru Medical College, Ajmer; ⁴Department of Pathology, Mahatma Gandhi Medical College, Jaipur, India

Abstract

A case of left sided malignant pleural effusion is described in a 41-year-old male, his initial workup for primary site of malignancy was unknown but later found to have hidden squamous cell carcinoma of penis which is one of the rarest site of malignancy that metastasise to pleura. Penile carcinoma manifesting with pleural metastasis and pleural effusion as initial presentation has not been reported previously.

Introduction

Pleural metastasis and malignant pleural effusion is one of the manifestations of advanced malignant disease. The most common

primary sites of malignancy to cause such condition are lung, breast, lymphoma, ovary and stomach [1]. These malignancies account for 80% of all malignant pleural effusion. In about 10% of malignant pleural effusions, the primary site still remains unidentified despite extensive workup [2]. Isolated pleural effusion as the presenting manifestation of cancer of unknown primary is very uncommon [3]. This communication describes a case of unilateral malignant pleural effusion where initial workup for primary site of malignancy was unknown but later this was identified as hidden squamous cell carcinoma of penis which is one of the rarest site of malignancy that metastasise to pleura.

Case Report

A 41-year-old male, farmer, presented with left sided chest pain and dry cough for last one month. He denied any history of fever, breathlessness, haemoptysis, *etc.* The past history was negative for significant medical illness or prolonged medication. He denied any trauma or instrumental procedure on him in recent or remote past. He was an average adult, vegetarian without any addiction habits. The general physical examination did not reveal any abnormality including clubbing or palpable lymphadenopathy. Respiratory system examination revealed dull percussion note with reduced intensity of breath sounds at left infra scapular and lower axillary areas. X-ray chest revealed moderate pleural effusion on left side (Figure 1). Other routine investigations *i.e.* complete blood counts, organ function tests, HIV serology, *etc.* were within normal limits.

Diagnostic pleurocentesis was performed and 20 cc of slightly haemorrhagic fluid was aspirated. Fluid examination revealed an exudate picture with adenosine deaminase (ADA) value of 12 IU. The cytological examination of pleural fluid revealed clusters of abnormal atypical cells with large hyperchromatic nuclei in the background of lymphocytes and red blood cells. A definitive histological typing of malignancy could not be made by the cytopathologist. CT scan chest revealed moderate pleural effusion without septations on left side and no abnormality in the underlying lung parenchyma or mediastinum. The visualized pleura also did not reveal any nodularity or focal thickening. Fibreoptic bronchoscopy did not show any endobronchial abnormality and bronchial lavage cytology was also negative for any abnormal cells. Ultrasound examination of abdomen was normal and additional studies of the thyroid and testes were also normal. For further evaluation, diagnostic thoracoscopy was performed with rigid thoracoscope under local anaesthesia. Multiple, small sized nodules were seen at the parietal pleura close to the diaphragm. Biopsy was taken from these nodules and drain was put in the pleural space that was subsequently removed after third day. The

Correspondence: Dr. Ramakant Dixit, Senior Professor & Head, Department of Respiratory Medicine, Jawaharlal Nehru Medical College, Ajmer 305001, Rajasthan, India.
Tel.+91.9413040257.
E-mail: dr.ramakantdixit@gmail.com

Key words: Malignant pleural effusion, carcinoma penis, occult carcinoma.

Contributions: RD, conception and design of the work, acquisition, analysis, or interpretation of data for the work, drafting the work and revising it critically for important intellectual content; MG, conception and design of the work, drafting the work and revising it critically for important intellectual content; KSP, NK, SA, conception and design of the work, accountable for all aspects of the work.

Conflict of interest: The authors declare that they have no competing interests, and all authors confirm accuracy.

Ethical approval: No Ethical Committee Approval was required for this case report by the Department, because this article does not contain any studies with human participants or animals.

Received for publication: 16 May 2020.
Accepted for publication: 22 July 2020.

©Copyright: the Author(s), 2020
Licensee PAGEPress, Italy
Monaldi Archives for Chest Disease 2020; 90:1384
doi: 10.4081/monaldi.2020.1384

This article is distributed under the terms of the Creative Commons Attribution Noncommercial License (by-nc 4.0) which permits any noncommercial use, distribution, and reproduction in any medium, provided the original author(s) and source are credited.

biopsy report of the pleura showed features of metastatic squamous cell carcinoma (Figure 2).

A repeat clinical examination and additional workup for identification of primary site including examination of oral cavity and ENT region by laryngoscopy, x-ray paranasal sinus, upper gastrointestinal tract scopy etc. was normal. Further workup with immunohistochemistry and PET CT could not be done due to lack of such facilities at our centre. The case was finally diagnosed as metastatic squamous cell carcinoma at pleura with unknown primary and was referred to the oncologist for further management. However, before a specific therapy could be planned, patient was again extensively enquired about any other significant symptom

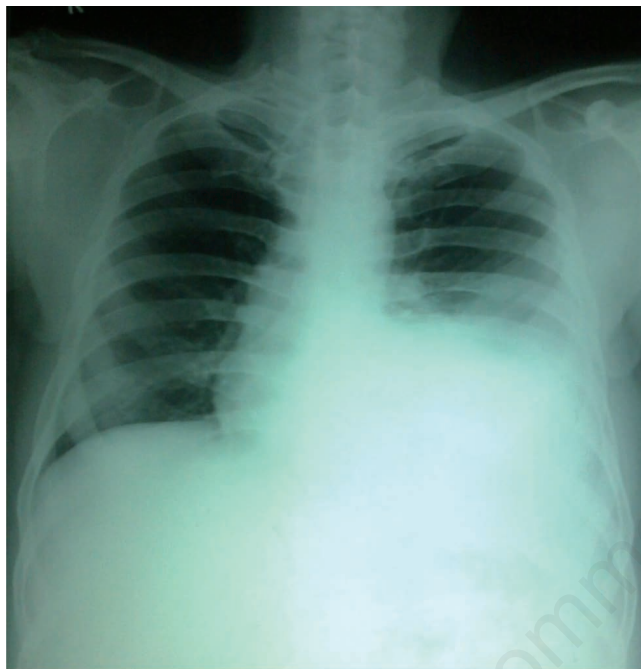

Figure 1. X-ray chest PA view showing left sided moderate pleural effusion.

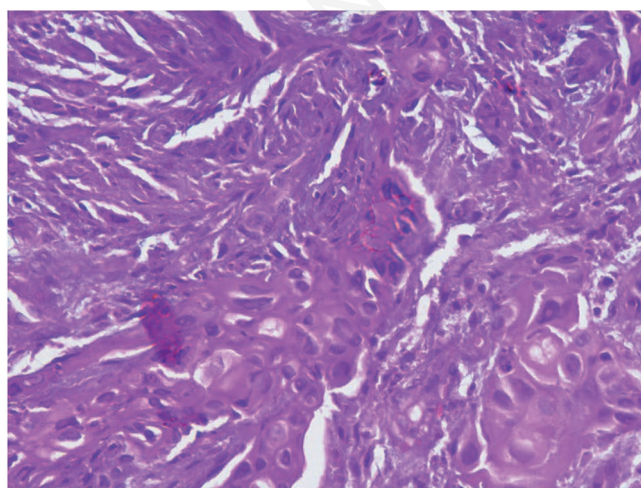


Figure 2. Photomicrograph of pleural biopsy showing metastatic squamous cell carcinoma (H&E, magnification 40x).

and he then disclosed history of painful erection for the last three months. Examination of the genitalia revealed non-circumcised penis with slight tenderness at the glans. On retracting the foreskin of penis, a raw erythematous lesion of 0.5x0.5 cm was seen at the junction of corona with the body of the penis. Biopsy of the lesion was performed by the surgeon that showed histological features of squamous cell carcinoma. The patient subsequently underwent surgery and received chemotherapy.

Discussion

The diagnosis of pleural effusion requires cytochemical analysis to establish underlying aetiology, however in around 20% cases, the cause remain uncertain despite extensive diagnostic workup. Such undiagnosed exudative pleural effusion often requires thoracoscopic evaluation that may increase diagnostic yield up to 85%. In these cases, the common causes of exudative pleural effusion are tuberculosis, primary or metastatic malignancy, parapneumonic effusion, mesothelioma, *etc.* [4].

The case described in this report is unique one and impart new lessons to learn. Very first, the penile carcinoma is one of the rarest site that can metastasize to the pleura to cause malignant pleural effusion. The first case of metastatic squamous cell carcinoma in pleural fluid was reported by Hoda and Rosen [5] in a 66-year old male having history of surgically treated carcinoma of penis, who subsequently died three days after the diagnosis. Theodore *et al.* [6] reported penile cancer in a 37-year-old man with AIDS and human papilloma virus infection who subsequently died within three years of metastatic disease that involved pleura, pericardium, lung, bone and subcutaneous tissue. Chaux *et al.* [7] described autopsy findings in 14 patients with penile squamous cell carcinoma and constructed a natural history model for penile cancer routes of spread & cancer progression. They observed recurrence and metastatic disease in 10 cases with only one case having metastatic disease at pleura. An another case was reported by Itani and co-workers [8] in a 43-year old male initially having biopsy proven squamous cell carcinoma penis who underwent neoadjuvant chemotherapy followed by surgery and subsequently developed metastasis to liver and bone. On PET scan he was incidentally diagnosed to have large right sided pleural effusion, with both pleural fluid cytology and pleural biopsy showing metastatic carcinoma. The same case also developed trapped lung physiology. Our case is different from the cases described above as in these cases, the diagnosis of carcinoma penis was evident well before the development of pleural metastasis and malignant pleural effusion, whereas in our case the primary site was hidden and not evident at the time of diagnosis of metastatic pleural disease. Such type of occult carcinoma penis presenting as metastatic pleural effusion has not been described in the literature till date. Table 1 summarizes the cases of squamous cell carcinoma of penis having metastasis to pleura reported in the literature till date.

Secondly, for the same reason, this case also stresses on thorough assessment for workup in cases of metastatic carcinoma with hidden/unknown primary. In our case, the symptoms of metastatic malignant pleural effusion were major and prompted the patient to consult medical care, on the other hand the symptom of primary site of malignancy were insignificant to an extent that they were temporary (pain only during penile erection) and more so not evident even on routine clinical evaluation. If such mild symptoms were ignored and examination of penis without retraction of fore-

Table 1. Cases of carcinoma penis with metastasis to pleura reported in literature till date.

No.	Year	Country	Author	Age of patient in years	Confirmation of diagnosis	Period between diagnosis of carcinoma penis and pleural metastasis
1	1992	USA	Hoda [5]	66	Pleural fluid cytology	History of surgery in past for carcinoma penis
2	2002	France	Theodore [6]	37	Pleural biopsy	3 years
3	2011	Paraguay	Chaux [7]	-	Autopsy study on pleura	Pleural effusion developed after recurrence of penile cancer
4	2019	USA	Itani [8]	43	Pleural fluid cytology and pleural biopsy	Pleural effusion developed after neoadjuvant chemotherapy followed by total penectomy
5	2020	India	Dixit (this study)	41	Thoracoscopic pleural biopsy	Pleural effusion was initial presentation; carcinoma penis was occult and present at the time of diagnosis of pleural effusion

skin not done, the primary site could have been missed for considerable period ahead. Therefore, this report shows importance of minor details in clinical examination in selected cases as the genitalia are often not given much attention while examining patients with pulmonary diseases.

References

- Dixit R, Agarwal KC, Gokhroo A, et al. Diagnosis and management options in malignant pleural effusions. *Lung India* 2017;34:160-6.
- Johnston WW. The malignant pleural effusion. A review of cytopathologic diagnoses of 584 specimens from 472 consecutive patients. *Cancer* 1985;56:905-9.
- Briasoulis E, Pavlidis N. Cancer of unknown primary origin. *Oncologist* 1997;2:142-52.
- Patil C, Dixit R, Gupta R, et al. Thoracoscopic evaluation of 129 cases having undiagnosed exudative pleural effusion. *Lung India* 2016;33:502-6.
- Hoda SA, Rosen PP. Cytologic diagnosis of metastatic penile carcinoma in pleural effusion. *Arch Pathol Lab Med* 1992;116:198-9.
- Théodore C, Androulakis N, Spatz A, et al. An explosive course of squamous cell penile cancer in an AIDS patient. *Ann Oncol* 2002;13:475-9.
- Chaux A, Reuter V, Lezcano C, et al. Autopsy findings in 14 patients with penile squamous cell carcinoma. *Int J Surg Pathol* 2011;19:164-9.
- Itani W, Austin A, Beegle SS. Metastatic penile squamous cell carcinoma resulting in trapped lung: a case report. *Chest* 2019;156:A1515.