

Pulmonary fibrosis presenting as an early manifestation of microscopic polyangiitis

D. Eleftheriou¹, S. Katsenos¹, S. Zorbas², I. Griveas², K. Psathakis¹

ABSTRACT: *Pulmonary fibrosis presenting as an early manifestation of microscopic polyangiitis. D. Eleftheriou, S. Katsenos, S. Zorbas, I. Griveas, K. Psathakis.*

Microscopic polyangiitis (MPA) is a systemic small vessel vasculitis that is included in the pulmonary-renal syndromes. Although glomerulonephritis represents the major clinical feature of MPA indicative of renal involvement, diffuse alveolar haemorrhage is the classic manifestation of pulmonary involvement. However, pulmonary fi-

bro sis is a less frequently reported pulmonary manifestation. Herein we describe a patient who was diagnosed with MPA presenting with radiographic evidence of pulmonary interstitial fibrosis as an early clinical manifestation accompanied by constitutional symptoms such as fever and weight loss. We also include a short literature review focusing on the association between pulmonary fibrosis and MPA.

Monaldi Arch Chest Dis 2012; 77: 3-4, 141-144.

Keywords: *Microscopic polyangiitis, Perinuclear antineutrophilic cytoplasmic antibodies, Pulmonary fibrosis.*

¹ Department of Pneumology, Army General Hospital of Athens, Athens;

² Department of Nephrology, Army General Hospital of Athens, Athens, Greece.

Correspondence: Stamatis Katsenos, MD, PhD; Department of Pneumology; Army General Hospital of Athens, 158 Mesogion&Katehaki Avenue, 115 25 Athens, Greece; e-mail: skatsenos@yahoo.gr

Microscopic polyangiitis (MPA) is an idiopathic autoimmune necrotizing vasculitis affecting predominantly small-caliber blood vessels and is characterised by the presence of antineutrophil cytoplasmic autoantibodies (ANCA), the absence of granulomas on histopathological specimen as well as the lack of immune deposits. It represents the main cause of the pulmonary-renal syndrome because it can lead to both pulmonary capillaritis and glomerulonephritis [1].

More specifically, renal involvement occurs in the majority of patients with MPA resulting in rapidly progressive glomerulonephritis. Lung involvement is present in 25-55% of patients. Diffuse alveolar hemorrhage caused by pulmonary capillaritis is the most common manifestation of respiratory involvement presenting clinically with dyspnea, hemoptysis, cough, pleuritic chest pain and anemia [2, 3]. Pulmonary fibrosis is a rarely reported clinical feature and can be seen months to years prior to, at the time of, or years after the diagnosis of MPA [1, 4].

In this report, we describe a patient with MPA whose the prime clinical presentation was interstitial pulmonary fibrosis that substantially antedated the presence of vasculitis and we concurrently discuss the recent knowledge about this rare lung manifestation in MPA.

Case Report

A 75-year old female, non-smoker presented at our department due to 3-month progressive fatigue, muscle weakness, anorexia and a 20-kg weight loss together with high-grade (39.5°C) fever for two weeks. The patient received several courses of antibiotics for common bacterial pathogens, before she sought our medical assistance, with no fever remission. She did not mention any respiratory symptoms. Her past medical history was unremarkable.

At presentation, she was frail and bedridden. Her muscle strength was impaired and graded 3/5 based on Medical Research Council (MRC) scale whereas distal motor and sensory function was intact. Lung auscultation revealed diffuse bilateral inspiratory crackles. Clubbing was also present. The rest of the physical examination showed no abnormal findings. Standard laboratory tests demonstrated leukocytosis (WBC: 20.600/μl with neutrophil predominance), normochromic normocytic anemia (Ht: 26%) and highly increased erythrocyte sedimentation rate (130 mm/h) as well as C-reactive protein (192 mg/l). Serum biochemistry test results and arterial blood gases on room air were within normal range.

A chest radiograph showed diffuse reticulonodular infiltrates throughout the lung fields (fig 1). Further imaging evaluation by high-resolution

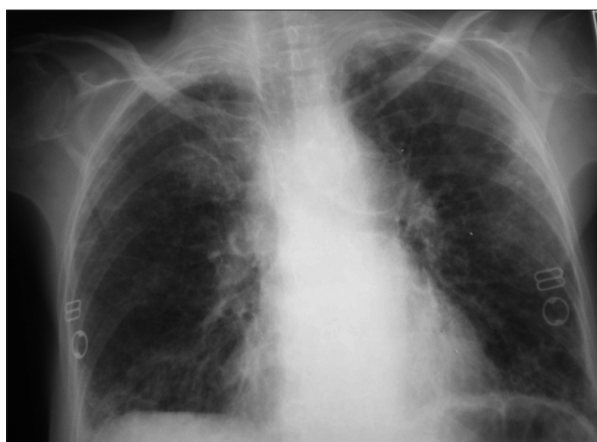


Fig. 1. - Chest radiograph showing diffuse reticulonodular infiltrates throughout the lung fields.

chest computed-tomography revealed intralobular septal thickening at the periphery, bilateral lower lobe honeycombing with associated traction bronchiectasis as well as a consolidation in the apical segment of the right upper lobe (fig. 2 a, b). Pulmonary function tests were not performed because of the patient's inability to cooperate with the procedure. Afterwards, the patient underwent fiberoptic bronchoscopy. No intraluminal lesions or other abnormal findings were observed. Microbiologic examination of samples obtained by bronchial washings and BAL for mycobacteria and other common pathogens as well as cytologic examination were negative. BAL fluid analysis showed 60% alveolar macrophages, 30% neutrophils, 8% lymphocytes and 2% eosinophils. Transbronchial lung biopsies were non-diagnostic. HRCT features and BAL cellular pattern were compatible with idiopathic pulmonary fibrosis. The patient refused to consent to an open lung biopsy.

However, a gradual renal impairment was noticed during her hospitalisation period with a serum creatinine level of 4.5 mg/dl. Urine examination showed 8-10 non-dysmorphic RBC per high power field and proteinuria 1.7 gr/ 24h. Further serological investigations for antinuclear antibody (ANA), extractable nuclear antigens, anti-glomerular basement membrane (anti-GMB) and complement yielded negative results. Perinuclear anti-neutrophil cytoplasmic antibodies (p-ANCA) were strongly positive with an anti-myeloperoxidase (MPO) antibody level of 1024 whereas anti-proteinase 3 antibodies were not detected. The patient exhibited further clinical deterioration with anuria and uncompensated metabolic acidosis. Percutaneous renal biopsy was directly performed showing a pauci-immune necrotising glomerulonephritis with crescentic formation in 44% of glomeruli and extra-glomerular vasculitic lesions (of interlobar and arciform arteries) as well as a moderate C3 staining in three glomeruli along the mesangium. Therefore, these findings were consistent with the diagnosis of MPA.

The patient was given corticosteroids (methylprednisolone 1gr iv/day for 3 days followed by 32

mg/day orally), 500 mg iv cyclophosphamide once monthly and prophylactic antibiotic therapy with trimethoprim/sulfamethoxazole. Intermittent renal hemodialysis was also initiated and continued for two weeks. A remarkable improvement of her renal function and general clinical condition was noted after two months of hospitalisation as serum creatinine level fell to 1.5 mg/dl and proximal muscle strength was partially recovered allowing her to walk small distances with minimal support. Six months after discharge while being on methylprednisolone dose tapering the disease was stabilized and the patient was completely recuperated. We could speculate that pulmonary fibrosis may represent an early manifestation of MPA in the present case considering the renal abnormalities established at the time and the exclusion of other entities leading to interstitial fibrosis.

Discussion

Microscopic polyangiitis is a systemic vasculitis histologically characterised by pauci-immune necrotising small-vessel vasculitis without granulomatous inflammation as well as the presence of circulating antineutrophilic cytoplasmic antibodies (ANCA) and particularly with a perinuclear staining pattern on immunofluorescence (p-ANCA) and specificity against myeloperoxidase (MPO) [1]. MPA is also a prime cause of the pulmonary-renal syndrome resulting in two major consistent pathologic features: focal segmental necrotising glomerulonephritis and pulmonary capillaritis [2, 3]. Other manifestations include cutaneous vasculitis, peripheral neuropathy, musculoskeletal involvement, diarrhea and gastrointestinal bleeding and in a few cases sinusitis.

Pulmonary involvement can be seen in 25-55% of patients. The characteristic lung manifestation of MPA is diffuse alveolar hemorrhage caused by pulmonary capillaritis, which has been reported in 12-55% of patients [1]. Pulmonary fibrosis is a less frequently described pulmonary manifestation and may precede, manifest at time of or follow the diagnosis of MPA [1, 4]. However, Tzelepis *et al.* reported recently a relatively high prevalence of pulmonary fibrosis in patients with MPA [5]. Nevertheless, the estimated high prevalence may not accurately reflect the true prevalence due to selection bias since the cohort study consisted of patients who were treated primarily in a general medicine or renal disease ward and may not be representative of the entire MPA patient population.

While the etiology of PF is unclear, two main mechanisms have been suggested for its development in MPA patients. Chronic subclinical alveolar hemorrhage has been presented as a possible cause leading to fibrosis, in a manner similar to that described for pulmonary fibrosis in patients with idiopathic hemosiderosis and hemoptysis [6]. The second is that ANCA antigens such as MPO undergo translocation to the surface of neutrophils (possibly in response to proinflammatory cytokines), and subsequent binding of circulating ANCA results in neutrophil degranulation and the release of reactive oxygen species, causing injury

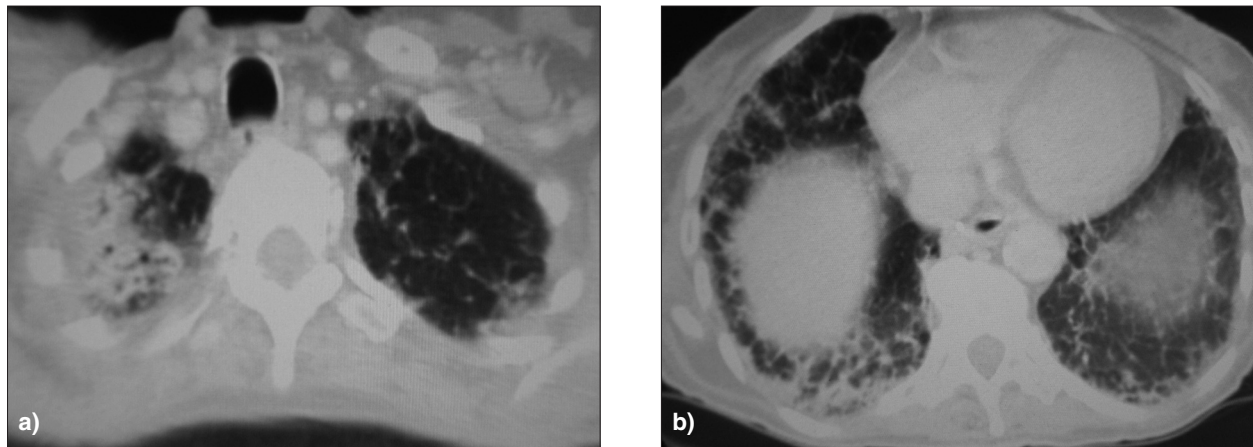


Fig. 2. - HRCT of the thorax demonstrating intralobular septal thickening at the periphery, bilateral lower lobe honeycombing with associated traction bronchiectasis (a) as well as a consolidation in the apical segment of the right upper lobe (b).

and consequent fibrosis. In this setting, fibrosis could represent a reparative response to the underlying chronic lung injury [3, 7].

According to consensus guidelines, the present case met the diagnostic criteria of MPA [8]. In particular, the patient had renal disease with pathological features consistent with MPA, and serum evidence of p-ANCA positivity as well as the constitutional symptoms of fever, fatigue and weight loss that would also go along with MPA. It is already established that MPA is often heralded by a long prodromal phase of profound constitutional symptoms followed by the development of rapidly progressive glomerulonephritis [1, 9].

Furthermore, the diagnosis of interstitial fibrosis (usual interstitial pneumonia-UIP pattern) was reliably made based on the most recently published international guidelines for idiopathic pulmonary fibrosis (IPF) diagnosis [10]. According to these evidence-based guidelines, the presence of UIP pattern (peripheral honeycombing with traction bronchiectasis) on HRCT is sufficient for the diagnosis of IPF and obviates the need for surgical lung biopsy. Other known causes of interstitial lung disease (e.g., domestic and occupational environmental exposures, connective tissue disease, drug toxicity and family history) were excluded thus further strengthening the initial diagnosis.

We could arguably allege that pulmonary fibrosis represents an initial pulmonary manifestation of MPA in the present case. Of the 59 well-identified cases in the literature with pulmonary fibrosis and MPA, PF had been manifested prior to the development of MPA in 23, MPA preceded the presence of PF in 1 and both conditions were identified concurrently in 35 [6, 11-16]. Nevertheless, it is possible that, in patients in whom both diseases were diagnosed at the same time, PF might have been present earlier but not clinically apparent. Likewise, patients presenting initially with PF might have had evidence of MPA that was not identified until later. Pulmonary fibrosis in our patient was most likely present several months before her admission to hospital. The progressive deterioration of general clinical condition forced her to seek further medical assistance. Testing for an-

ti-MPO antibodies had not been carried out before vasculitis presentation. Our patient became anti-MPO positive when she developed acute renal failure. It seems that the two conditions were indeed related in our case. The occurrence of haematuria and proteinuria when she presented with PF would be consistent with this association. Although idiopathic interstitial fibrosis and MPA could have occurred concurrently by accident, each in itself is a rare disease. The possibility of both entities occurring in the same patient seems remote.

In conclusion, pulmonary fibrosis is an uncommon but recognised pulmonary manifestation of MPA. Whether this is a genuine clinical feature of vasculitis or a coincidental finding remains equivocal. However, the fact that most such patients have autoantibodies against MPO suggests that there may be a true association in at least some cases. The fibrosis may precede other disease manifestations by a variable length of time or become apparent at time of or years after the diagnosis of MPA. The prognosis of patients with pulmonary fibrosis is poor but may be improved by the institution of immunosuppressive agents. Larger prospective studies should be conducted to clarify the possible causal relationship between pulmonary fibrosis and MPA.

References

1. Chung SA, Seo P. Microscopic polyangiitis. *Rheum Dis Clin North Am* 2010; 36: 545-558.
2. Guillevin L, Durand-Gasselien B, Cevallos R, *et al.* Microscopic polyangiitis: clinical and laboratory findings in eighty-five patients. *Arthritis Rheum* 1999; 42: 421-430.
3. Collins CE, Quismorio FP Jr. Pulmonary involvement in microscopic polyangiitis. *Curr Opin Pulm Med* 2005; 11: 447-451.
4. Arulkumaran N, Periselneris N, Gaskin G, *et al.* Interstitial lung disease and ANCA-associated vasculitis: a retrospective observational cohort study. *Rheumatology* 2011; 50: 2035-2043.
5. Tzelepis GE, Kokosi M, Tzioufas A, *et al.* Prevalence and outcome of pulmonary fibrosis in microscopic polyangiitis. *Eur Respir J* 2010; 36: 116-121.
6. Birnbaum J, Danoff S, Askin FB, Stone JH. Microscopic polyangiitis presenting as a "pulmonary-muscle"

- syndrome. Is subclinical alveolar hemorrhage the mechanism of pulmonary fibrosis? *Arthritis Rheum* 2007; 56: 2065-2071.
7. Foucher P, Heeringa P, Petersen AH, et al. Antimyeloperoxidase-associated lung disease. An experimental model. *Am J Respir Crit Care Med* 1999; 160: 987-994.
 8. Jennette JC, Falk RJ, Andrassy K, et al. Nomenclature of systemic vasculitides: proposal of an international consensus conference. *Arthritis Rheum* 1994; 37: 187-192.
 9. Brown KK. Pulmonary vasculitis. *Proc Am Thor Soc* 2006; 3: 48-57.
 10. Raghu G, Collard HR, Egan JJ, et al. An official ATS/ERS/JRS/ALAT statement: Idiopathic pulmonary fibrosis: evidence-based guidelines for diagnosis and management. *Am J Respir Crit Care Med* 2011; 183: 788-824.
 11. Bhanji A, Karim M. Pulmonary fibrosis-an uncommon manifestation of anti-myeloperoxidase-positive systemic vasculitis? *NDT Plus* 2010; 3: 351-353.
 12. Eschun CM, Mink SN, Sharma S. Pulmonary interstitial fibrosis as a presenting manifestation in perinuclear antineutrophilic cytoplasmic antibody microscopic polyangiitis. *Chest* 2003; 123: 297-301.
 13. Herrier B, Pagnoux C, Agard C, et al. Pulmonary fibrosis associated with ANCA-positive vasculitides. Retrospective study of 12 cases and review of the literature. *Ann Rheum Dis* 2009; 68: 404-407.
 14. Foulon G, Delaval P, Valeyre D, et al. ANCA-associated lung fibrosis: analysis of 17 patients. *Respir Med* 2008; 102: 1392-1398.
 15. Hiromura K, Nojima Y, Kitahara T, et al. Four cases of antimyeloperoxidase antibody-related rapidly progressive glomerulonephritis during the course of idiopathic pulmonary fibrosis. *Clin Nephrol* 2000; 53: 384-389.
 16. Ando Y, Okada F, Matsumoto S, et al. Thoracic manifestation of myeloperoxidase-antineutrophilic cytoplasmic antibody (MPO-ANCA)-related disease. CT findings in 51 patients. *J Comput Assist Tomogr* 2004; 28: 710-716.

