

A filamentous trio

Rishabh Raj¹, Kavitha Venkatnarayan¹, Uma Maheswari Krishnaswamy¹, Uma Devaraj¹,
Priya Ramachandran¹, Jayanthi Savio²

¹Department of Pulmonary Medicine; ²Department of Microbiology, St. John's National Academy of Health Sciences, Bengaluru, India

Abstract

Opportunistic infections caused by fungi and unusual bacteria are predominantly encountered in the setting of immunosuppressed host. Co-infections with multiple such organisms can pose multiple challenges even to the astute clinician from establishing the diagnosis to drug interactions during treatment of such infections. We hereby present one such case of a triple opportunistic infection in an immunocompetent host and the difficulties faced in the therapeutic decision making.

Correspondence: Dr. Kavitha Venkatnarayan, Department of Pulmonary Medicine, 3rd floor, Oncology Block, St John's National Academy of Health Sciences, Sarjapur Road, Bengaluru 560034, India. Tel. +91.9013770826. E-mail: kavaiims@gmail.com

Keywords: Aspergillus; nocardia; mucormycosis; diabetes mellitus.

Authors' contributions: All the authors have contributed towards patient diagnosis and management and manuscript preparation and revision.

Ethics approval and consent to participate: No ethical committee approval was required for this case report by the Department, because this article does not contain any studies with human participants or animals. Informed consent was obtained from the patient included in this study.

Consent for publication: A written consent has been obtained from the patient for publishing the case.

Conflict of interest: The authors have no conflict of interest to disclose.

Funding: No funding obtained in relation to the above manuscript.

Received for publication: 7 July 2020.

Accepted for publication: 10 September 2020.

©Copyright: the Author(s), 2020

Licensee PAGEPress, Italy

Monaldi Archives for Chest Disease 2020; 90:1493

doi: 10.4081/monaldi.2020.1493

This article is distributed under the terms of the Creative Commons Attribution Noncommercial License (by-nc 4.0) which permits any noncommercial use, distribution, and reproduction in any medium, provided the original author(s) and source are credited.

Case Report

A 59-year-old gentleman who was a farmer with a background of hypertension and diabetes for 6 years, presented with low grade fever, cough with expectoration of purulent sputum and dyspnea for 15 days. There was no history of hemoptysis. He had been treated with ceftriaxone, azithromycin and doxycycline for 7 days elsewhere for the above symptoms and had been started on intravenous meropenem as there had been no response to the initial antibiotic therapy.

On admission, he was febrile, had tachypnea (respiratory rate of 32/min), tachycardia (heart rate – 124/min) and left infrascapular crepitations. His blood investigations including complete hemogram, renal and liver functions were within normal limits. However, blood sugars were poorly controlled, ranging between 250-300mg/dl with a HbA1c of 12.8%. HIV serology was negative.

Chest radiogram showed inhomogeneous opacities in the right midzone and left mid and lower zones with mild left pleural effusion (Figure 1A). Thoracic ultrasound showed evidence of left mild pleural effusion with shreds suggestive of an underlying consolidation. A diagnostic pleurocentesis was performed which revealed a neutrophil predominant exudative fluid (cell count – 1397, N78L22; protein – 3.58 g/dl; glucose – 144 mg/dl).

Meropenem was continued pending culture reports and the patient continued to be febrile. A CT chest was performed in view of bilateral disease and sub-optimal response to antibiotics. It showed multiple patchy areas of consolidation, reverse halo sign (central ground glass surrounded by dense consolidation) in the right middle lobe and lower lobe and cavitation in the left lower lobe with mild left sided pleural effusion (Figure 2). His sputum examination showed presence of aseptate fungal hyphae. A bronchoscopy was done which revealed mucopurulent secretions in the left lower lobe. Tissue biopsy could not be obtained as the patient was very sick, thus only a broncho-alveolar lavage (BAL) was performed and sent for microbiological investigations. Fungal staining of the BAL fluid confirmed the presence of septate as well as aseptate hyphae suggestive of dual infection with *Mucorales* and *Aspergillus* species and BAL galactomannan level was 2.35. On culture, the specimen grew both *Aspergillus niger* and *Nocardia* species (Figure 3).

In view of the triple infection with aspergillus, mucor and nocardia, he was started on intravenous liposomal amphotericin B (LAMB), Co-trimoxazole and insulin therapy titrated to achieve tight glycemic control. In view of the unusual triad of infective organisms, a nitroblue tetrazolium test was done, which was positive suggestive of normal neutrophil oxidative function.

The patient's fever spikes subsided after 4 days, with symptomatic relief of cough and dyspnea over the next 2 weeks. Chest radiograms repeated after 2 and 4 weeks showed ongoing signifi-

cant radiological response with more than 80% resolution of opacities at the end of 2 months of treatment (Figure 1B). After completing 3 g of cumulative dose of LAMB, he was started on oral posaconazole. He developed hyperkalemia attributable to co-trimoxazole which was confirmed on re-challenging with the drug. Hence, oral linezolid was started for nocardiosis. He was discharged on oral posaconazole and linezolid along with human mix-tard insulin.

Discussion

Recent times have witnessed an increase in the burden of unusual opportunistic infections partly due to an increase in the 'at risk' population. This is secondary to the global increase in people living with HIV-AIDS, advances in the medical care of patients with malignancies, increase in the number of transplants, indiscriminate use of antibiotics in critical care and increasing use of immunosuppressants and steroids [1].

Nocardiosis, aspergillosis and mucormycosis share many common attributes. All the organisms occur ubiquitously in the environment and reach the lungs through inhalational route. All of them present with non-specific symptoms, making the diagnosis a real challenge even to the astute clinician. Traditionally, hematological malignancies, post-transplant status, neutropenia, congenital and acquired immunodeficiency, steroid therapy and use of other immunosuppressants have been identified as risk factors [1]. However, diabetes mellitus (DM) is also being increasingly reported as a predisposing condition for the three above mentioned infections. With an estimated prevalence of DM of 7.3% and a predicted increase in prevalence among the rural and lower socioeconomic strata [2], DM will soon outnumber all other risk factors for oppor-

tunistic infections in India. Apart from the traditionally known microvascular and macrovascular complications, DM is known to impact the immune system in various ways. Some of the mechanisms studied include, decrease in the production of inflammatory cytokines and complements required for opsonization and phagocytosis, impairment of chemotaxis and oxidative function of mono and polymorphonuclear leucocytes and deficient proliferation of CD4 cells and their response to antigens [3].

DM is a predominant risk factor for mucormycosis in Asians when compared to the Western literature where hematological malignancies and transplants are the major risk factors [4,5]. In addition to the phagocyte dysfunction enumerated earlier, acidic pH in ketoacidosis increases the availability of free iron essential for cell growth and development, thus enhancing the virulence of mucor in DM [6]. Chronic lung diseases and DM are among the risk factors reported for nocardiosis [7]. Similarly, DM, hepatic dysfunction and critical illness are being identified as emerging risk factors for invasive pulmonary aspergillosis (IPA) [8]. With all the evidence discussed above, it is about time that DM is also included in the list of predisposing host factors to diagnose probable invasive fungal diseases [9].

The radiological presentation of both mucormycosis and IPA can vary from single to multiple nodules which can be cavitating, consolidation, halo or reverse halo sign. A bird's nest appearance of irregular, intersecting areas of stranding and irregular lines present within area of ground glass opacity can also be seen in patients with invasive fungal infection (more common in mucormycosis) [10]. Pulmonary nocardiosis can also present with consolidation, lung mass or nodules with cavitation and pleural effusion [7]. In our patient also, the presence of reversed halo sign prompted further investigation for an opportunistic infection.

As clinical and radiological features of multiple co-infections are non-specific, a high index of suspicion is required for early

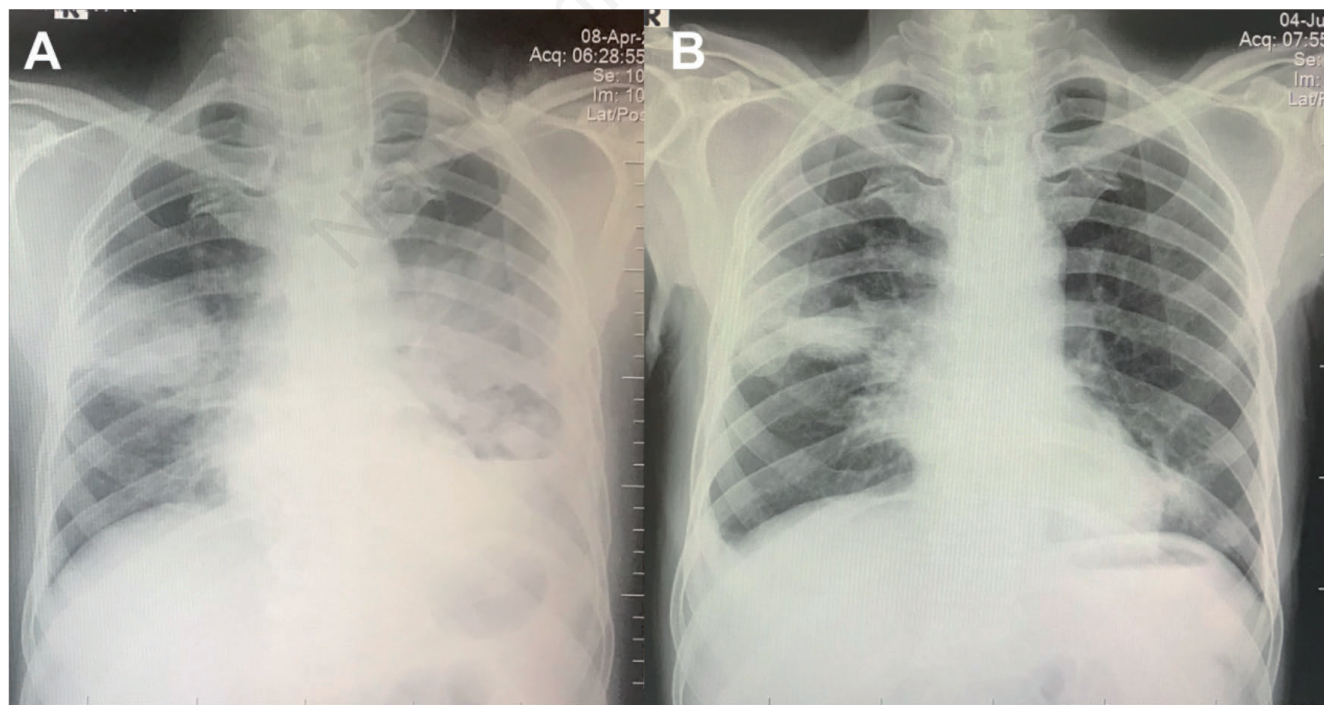


Figure 1. Chest radiograph. A) Right midzone and left mid and lower zone inhomogeneous opacities with blunting of left cardiophrenic angle. B) After 2.5g of LAMB, partial resolution with residual cavity in right midzone.

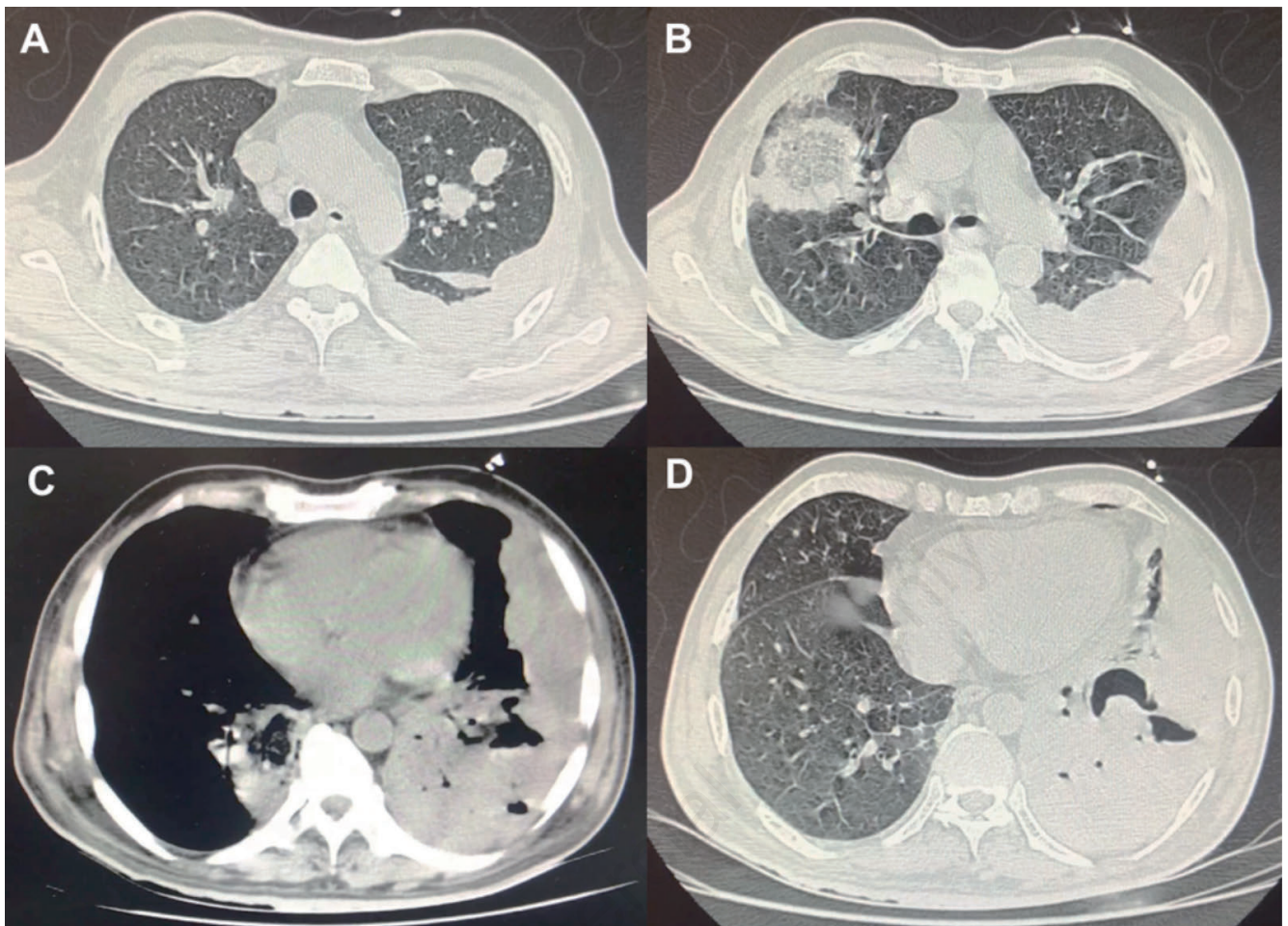


Figure 2. CT chest showing left upper lobe nodules, right middle lobe consolidation with reversed halo sign. Left lower lobe necrotizing consolidation with left pleural effusion.

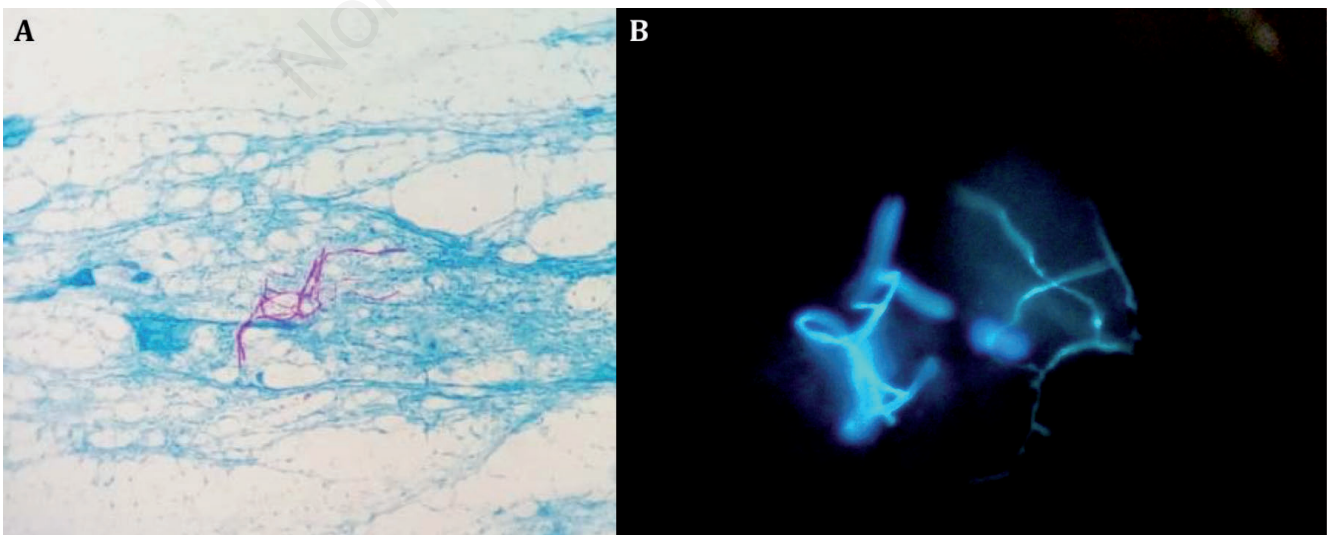


Figure 3. A) Modified Ziehl Neelsen stain (100x): thin beaded branching acid fast bacilli suggestive of *Nocardia* species. B) KOH, calcofluor stain (10x): both broad, aseptate fungal hyphae (left) and septate fungal hyphae (right)

diagnosis and prompt therapy. Although guidelines for diagnosis require demonstration of the mold in tissue [9], obtaining tissue either by biopsy or following resection of the infected tissue may be challenging in patients who may be poor surgical candidates or too sick for biopsies. Hence, the diagnosis of proven fungal infection is difficult to obtain.

Only a few cases of co-infection of aspergillus, mucor and nocardia have been reported predominantly in transplant recipients and hematological malignancies. To our knowledge till date only one case of a triple infection of pulmonary aspergillosis with mucormycosis and pulmonary nocardiosis has been reported in the literature [11]. Early diagnosis and prompt therapy are the key to improve outcome in these infections, all of which carry a very high mortality rate. Co-infections also pose a therapeutic challenge with respect to drug interactions and side effect profiles. Voriconazole being the first choice for aspergillus and LAMB for mucor, LAMB was chosen in our patient as it is an accepted alternative for aspergillosis as well [12,13]. Combination therapy with LAMB and voriconazole is controversial. An antagonistic effect is postulated based on competitive binding – azoles inhibit the synthesis of ergosterol essential for the action of polyenes thus rendering them ineffective. However, a concentration dependent synergistic action based on the dose of azoles used has also been reported [14]. Though anecdotal case reports and pharmacokinetic models have demonstrated better outcomes with the combination, some studies have shown voriconazole and amphotericin to be the least effective combination [15,16]. In view of the controversies, the combination of azoles and polyenes are not recommended [14]. After 3 g of LAMB, our patient family expressed financial difficulties in continuing hospital stay. Hence posaconazole, which is active against both the fungi was started.

In addition to the above, was the challenge of treating nocardiosis. Our patient developed hyperkalemia secondary to co-trimoxazole therapy and was thus started on linezolid as it has a broader coverage for all nocardia species [17]. Following this he developed anemia which was attributed to linezolid which was replaced with minocycline. After 3 months of treatment, he is doing well continuing posaconazole and minocycline.

Learning points

Patients with only diabetes mellitus and no other immunosuppression can have serious concurrent infections with multiple opportunistic organisms.

Radiological signs like halo sign and reversed halo/ bird nest sign on CT can help suspect invasive fungal infections.

A high index of suspicion is imperative for early diagnosis and prompt therapy in such patients to reduce mortality and improve outcome.

Treating co-infections with multiple antibiotics can be challenging due to multiple drug interactions and side effects which need to be closely monitored.

References

- Lai CC, Tan CK, Huang YT, et al. Current challenges in the management of invasive fungal infections. *J Infect Chemother* 2008;14:77–85.
- Anjana RM, Deepa M, Pradeepa R, et al. Prevalence of diabetes and prediabetes in 15 states of India: results from the ICMR–INDIAB population-based cross-sectional study. *Lancet Diabetes Endocrinol* 2017;5:585–96.
- Casqueiro J, Casqueiro J, Alves C. Infections in patients with diabetes mellitus: A review of pathogenesis. *Indian J Endocrinol Metab.* 2012;16:S27-36.
- Prakash H, Ghosh AK, Rudramurthy SM, et al. A prospective multicenter study on mucormycosis in India: Epidemiology, diagnosis, and treatment. *Med Mycol* 2019;57:395–402.
- Jeong W, Keighley C, Wolfe R, et al. The epidemiology and clinical manifestations of mucormycosis: a systematic review and meta-analysis of case reports. *Clin Microbiol Infect* 2019;25:26–34.
- Ibrahim AS, Spellberg B, Walsh TJ, Kontoyiannis DP. Pathogenesis of mucormycosis. *Clin Infect Dis* 2012;54:S16-22.
- Singh A, Chhina D, Soni R, et al. Clinical spectrum and outcome of pulmonary nocardiosis: 5-year experience. *Lung India* 2016;33:398.
- Danion F, Rouzaud C, Duréault A, et al. Why are so many cases of invasive aspergillosis missed? *Med Mycol* 2019;57:S94-103.
- De Pauw B, Walsh TJ, Donnelly JP, et al. Revised definitions of invasive fungal disease from the European Organization for Research and Treatment of Cancer/Invasive Fungal Infections Cooperative Group and the National Institute of Allergy and Infectious Diseases Mycoses Study Group (EORTC/MSG) Consensus Group. *Clin Infect Dis* 2008;46:1813-21.
- Walker CM, Abbott GF, Greene RE, et al. Imaging pulmonary infection: Classic signs and patterns. *Am J Roentgenol* 2014;202:479–92.
- Dam AP, Pruijm MTC, Harinck BIJ, et al. Pneumonia involving Aspergillus and Rhizopus spp. after a near-drowning incident with subsequent Nocardia cyriacigeorgici and N. farcinica coinfection as a late complication. *Eur J Clin Microbiol Infect Dis* 2005;24:61-4.
- Patterson TF, Thompson GR, Denning DW, et al. Practice guidelines for the diagnosis and management of aspergillosis: 2016 update by the Infectious Diseases Society of America. *Clin Infect Dis* 2016;63:e1-60.
- Cornely OA, Arikan-Akdagli S, Dannaoui E, et al. ESCMID and ECMM joint clinical guidelines for the diagnosis and management of mucormycosis 2013. *Clin Microbiol Infect* 2014;20:5-26.
- Bellmann R, Smuszkievicz P. Pharmacokinetics of antifungal drugs: practical implications for optimized treatment of patients. *Infection* 2017;45:737-79.
- Siopi M, Siafakas N, Vourli S, et al. Optimization of polyene-azole combination therapy against aspergillosis using an in vitro pharmacokinetic-pharmacodynamic model. *Antimicrob Agents Chemother* 2015;59:3973-83.
- Qiu KY, Liao XY, Fang JP, K et al. Combination antifungal treatment for invasive fungal disease after hematopoietic stem cell transplantation in children with hematological disorders. *Transplant Infect Dis* 2019;21:e13066.
- Wilson JW. Nocardiosis: updates and clinical overview. *Mayo Clin Proc* 2012;87:403-7.