

# Prolonged non-invasive respiratory supports in a patient with COVID-19 and severe acute hypoxemic respiratory failure: A case report

Andrea Lanza<sup>1</sup>, Maurizio Sommariva<sup>1</sup>, Sara Mariani<sup>1</sup>, Gabriela Ferreyra<sup>2</sup>, Giuliana Enrica Stagni<sup>1</sup>, Valeria Tombini<sup>3</sup>, Angela Oppizzi<sup>3</sup>, Catia Pontiggia<sup>3</sup>, Andrea Bellone<sup>3</sup>

<sup>1</sup>Respiratory Physiotherapists Team, ASST Grande Ospedale Metropolitano Niguarda, Milan; <sup>2</sup>Department of Surgical Science, Anesthesia and Critical Care, University of Turin; <sup>3</sup>Emergency Department, ASST Grande Ospedale Metropolitano Niguarda, Milan, Italy

## Abstract

A pandemic caused by the Severe Acute Respiratory Syndrome Coronavirus 2 was declared in 2020. Severe cases were characterized by the development of acute hypoxemic respiratory failure (AHRF) requiring advanced respiratory support. However, intensive care units (ICU) were saturated, and many patients had to be treated out of ICU. This case describes a 75-year-old man affected by AHRF due to Coronavirus Disease 2019 (COVID-19), hospitalized in a high-dependency unit, with PaO<sub>2</sub>/FiO<sub>2</sub> <100 for

28 consecutive days. An experienced team with respiratory physiotherapists was in charge of the noninvasive respiratory support (NIRS). The patient required permanent NIVS with continuous positive airway pressure, non-invasive ventilation, high flow nasal oxygen and body positioning. He was weaned from NIRS after 37 days and started exercise training afterwards. The patient was discharged at home with low-flow oxygen therapy. This case represents an example of a successful treatment of AHRF with the still controversial noninvasive respiratory supports in one patient with COVID-19.

## Introduction

A pandemic caused by the Severe Acute Respiratory Syndrome Coronavirus 2 (SARS-CoV-2) was declared in 2020. Italian health care system was close to collapse due to a high number of patients with Coronavirus Disease 2019 (COVID-19) acute hypoxemic respiratory failure (AHRF) and acute respiratory distress syndrome (ARDS) requiring advanced respiratory support. However, intensive care units (ICU) were saturated and many patients had to be managed out of ICU [1]. High Dependency Units (HDU) have been fully dedicated from that moment on to perform non-invasive ventilation (NIV) in patients with COVID-19 and AHRF.

NIV has been used in patients with ARDS, however this therapy is still controversial due to potential delay of intubation and increased mortality rate [2]. The Lung Safe Study showed that NIV was associated with elevated mortality when PaO<sub>2</sub>/FiO<sub>2</sub> was <150 mmHg [3]. Also, an elevated respiratory drive with high tidal volumes (V<sub>t</sub>) may cause patient self-inflicted lung injury (P-SILI) worsening pulmonary edema [4]. Moreover, requirement for prolonged NIV sessions for several weeks may be associated with poor tolerance, leading to failure in 5–25% of the cases [5]. Little is known about NIV in patients with COVID-19 and without clear conclusions on the type of patients to be included [6]. However, a non-invasive respiratory support (NIRS) and body positioning may be the only resource available in some patients affected by AHRF due to COVID-19 and not eligible for invasive mechanical ventilation, due to the unprecedented and sustained high levels of demand for limited intensive care units capacity [7].

We present a patient affected by severe AHRF due to COVID-19, treated outside the ICU with a prolonged combined strategy of body positioning and alternation of Continuous Positive Airway Pressure (CPAP), NIV and High Flow Nasal Oxygen (HFNO), in addition to conventional therapy.

Correspondence: Andrea Lanza, ASST Grande Ospedale Metropolitano Niguarda, Piazza dell'Ospedale Maggiore 3, 20162 Milano, Italy.  
Tel. +39.02.64447203.  
E-mail: andrea.lanza@ospedaleniguarda.it

Acknowledgements: we would like to thank all the health care professionals of the emergency department of ASST Grande Ospedale Metropolitano Niguarda.

Key words: COVID-19; non-invasive ventilation; high flow nasal-cannula, acute hypoxemic respiratory failure; prone position.

Conflict of interest: The authors declare that they have no competing interests, and all authors confirm accuracy.

Ethics approval and consent to participate: No ethical committee approval was required for this case report by the Department, because this article does not contain any studies with human participants or animals. Informed consent was obtained from the patient included in this study.

Consent for publication: The patient gave his written consent to use his personal data for the publication of this case report.

Received for publication: 23 March 2021.  
Accepted for publication: 7 July 2021.

©Copyright: the Author(s), 2021  
Licensee PAGEPress, Italy  
Monaldi Archives for Chest Disease 2022; 92:1783  
doi: 10.4081/monaldi.2021.1783

This article is distributed under the terms of the Creative Commons Attribution Noncommercial License (by-nc 4.0) which permits any noncommercial use, distribution, and reproduction in any medium, provided the original author(s) and source are credited.

## Case Report

On 8 April 2020, a 75-years-old male with a past medical history of hypokinetic dilated cardiomyopathy (left ventricular ejection fraction 29%), atrial fibrillation, chronic obstructive pulmonary disease (COPD) and body mass index equals to 35.29 kg/m<sup>2</sup>, with implantable cardioverter-defibrillator was admitted to the Emergency Department (ED) of Niguarda Hospital, Milan (Italy). At admission, the patient presented fever, dyspnea and clinical signs of respiratory distress: respiratory rate (RR) 30 breaths/min, oxygen saturation (SpO<sub>2</sub>) 91% with 6 lt/min oxygen. Arterial blood gas analysis (ABG) confirmed severe hypoxemia (pH=7.42; PaO<sub>2</sub>=63 mmHg; PaCO<sub>2</sub>=33 mmHg) yielding a PaO<sub>2</sub>/FiO<sub>2</sub> ratio of 160. Chest computed tomography showed bilateral ground-glass lung changes. The test for COVID-19 was confirmed positive the same day.

In ED, a Helmet CPAP 10 cmH<sub>2</sub>O and FiO<sub>2</sub> 50% was initiated. Few hours later, it was increased to 12.5 cmH<sub>2</sub>O and FiO<sub>2</sub> 70%, to maintain a target SpO<sub>2</sub> of 92-94% and PaO<sub>2</sub>/FiO<sub>2</sub> around 90. Due to the worsening of oxygenation, the ICU team was immediately notified. However, given the impaired functional status due to multiple comorbidities and low chance to successfully overcome critical illness, the patient was transferred to a COVID-19 HDU dedicated to NIVS with trained physicians, nurses and respiratory physiotherapists (RPTs). A protocol to improve parenchymal recruitment and maximize gas exchange was applied. RPTs implemented Helmet CPAP and changes of body position (prone, right and left and seated position out of bed) every 2-3 hours. All changes of position improved SpO<sub>2</sub> in comparison to supine position. Lateral positions were prevalent during sleep to reduce the respiratory workload due to obesity and prevent possible unrecognized obstructive sleep disorders. Specifically, prone position produced the highest SpO<sub>2</sub> improvement of around 8% being well tolerated by the patient for at least 2 hours. However, oxygenation returned to baseline after re-supination. Despite the severe condition, sitting position was reached almost on a daily basis, and it was associated with a SpO<sub>2</sub> increase of 5-6%.

For the first 8 days the patient remained on similar CPAP and FiO<sub>2</sub> setting for 20-24 hours/day with a mean SpO<sub>2</sub> 92% and RR 27-30 breaths/min (Table 1). There was only an adverse event on day 6<sup>th</sup>. Suddenly, in an attempt to reach prone position, SpO<sub>2</sub> dropped to 75%, RR 35 breaths/min and respiratory mechanics deteriorated, even increasing FiO<sub>2</sub> to 100%. Thus, considering the respiratory instability of the patient, prone position was avoided from that moment on.

On day 8<sup>th</sup>, the patient exhibited intolerance to the helmet, complaining of discomfort and noisiness. An oronasal mask (Mirage Quattro Fx NV, Resmed) was introduced during the daytime. Also, HFNO with flow rate of 50 l/min and FiO<sub>2</sub> 80-100% was used to allow short interruptions of CPAP.

The night between the 8th and 9th day, the patient's respiratory function suddenly worsened. He complained of severe dyspnea with paradoxical abdominal breathing, use of respiratory accessory muscles, RR ≥40 breaths/min, HR 150/min and SpO<sub>2</sub> between 75 and 80% despite CPAP 12.5 cmH<sub>2</sub>O and FiO<sub>2</sub> 100%. Immediately, the patient was switched from CPAP to NIV (Monnal T75, Air Liquide Medical Systems) in pressure support ventilation (PSV) by oronasal mask under the following settings: pressure support (PS) 12 cmH<sub>2</sub>O, positive end expiratory pressure (PEEP) 12 cmH<sub>2</sub>O, rise time 100 mms and FiO<sub>2</sub> 100%. After 30 minutes the patient showed a reduction of RR to 26-28 breaths/min and SpO<sub>2</sub> stabilized at 95%, with mean Vt equals to 800 ml.

On day 10<sup>th</sup>, ABG on NIV with FiO<sub>2</sub> 70% showed pH 7.45, PaO<sub>2</sub> 60.6 mmHg and PaCO<sub>2</sub> 43 mmHg.

Until day 20<sup>th</sup>, the patient continued on NIV 24 hours/day with short interruptions of HFNO 60 l/min with FiO<sub>2</sub> 100% for feeding, unless SpO<sub>2</sub> dropped to 85%. Ventilatory setting were able to maintain a mean SpO<sub>2</sub> 90-95% and RR 22-30 breaths/min (Table 1).

Due to the permanent mask use, a skin lesion on the nose bridge occurred on day 16<sup>th</sup>. On that day, ABG showed pH 7.43, PaO<sub>2</sub> 68 mmHg, PaCO<sub>2</sub> 41 mmHg (PaO<sub>2</sub>/FiO<sub>2</sub> of 75). To avoid NIV failure, RPTs started rotating different types of masks (Total Face, Responics; Oronasal, Mirage Ultra and Mirage Quattro Fx, Resmed) in order to change the contact points over the skin. After 3 days, the lesion improved, and no more sores appeared.

From day 20<sup>th</sup> to day 28<sup>th</sup> severe AHRF persisted while NIV was used 18 hours/day and HFNO for 2 hours, 3 times a day. Changes of PaO<sub>2</sub>/FiO<sub>2</sub> ratio and hours per day on each respiratory support are reported in Figure 1.

While on NIV, the patient alternated phases of good tolerance with acceptable breathing pattern in contrast with others of high agitation, severe dyspnea, RR ≥30 and increased Vt over 1000 ml, surpassing 8ml/kg/predicted body weight (PBW). In order to reduce inspiratory effort during agitation, first, RPTs increased PS; however, no Vt reduction was observed. Consecutively, PEEP was increased to 15 cmH<sub>2</sub>O and support of sedative drug therapy (morphine) was implemented with a reduction of RR below 30 breaths/min, mean Vt around 650 ml and SpO<sub>2</sub> stabilized at 93-94%.

From 29<sup>th</sup> to 36<sup>th</sup> day, clinical and respiratory conditions improved, PaO<sub>2</sub>/FiO<sub>2</sub> ratio was progressively increasing with a gradually lower FiO<sub>2</sub> on both NIV and HFNO from 80% to 40%. PS and PEEP were also reduced. Time on NIV was progressively reduced whereas HFNO increased during daytime (Figure 1).

On day 37<sup>th</sup>, NIV was interrupted and low-flow O<sub>2</sub> therapy was provided. On the same day, RPTs started a light/moderate intensity motor exercise training, sustained with conventional oxygen therapy (COT) to maintain SpO<sub>2</sub> >93%. The patient had no specific impairment of motor abilities; however, he presented a movement-

**Table 1. Changes of ventilatory support mode, interfaces and settings during hospital stay.**

Mode Interface	Day 1-8	Day 9-16		Day 17-27		Day 28-36	
	CPAP Helmet/ oronasal	PSV Oronasal	HFNO Nasal prongs	PSV Oronasal/ total face	HFNO Nasal prongs	PSV Oronasal/ total face	HFNO Nasal prongs
PEEP (cmH <sub>2</sub> O)	12.5	12/15	-	8/10	-	6/8	-
PS (cmH <sub>2</sub> O)	-	10/12	-	8/12	-	6/8	-
HFNO (l/min)	-	-	50-60	-	60	-	60
FiO <sub>2</sub> (%)	50-100	70-100	100	80-100	100	40-80	40-100

CPAP, continuous positive airway pressure; PSV, pressure support ventilation; HFNO, high flow nasal oxygen; PS, pressure support; PEEP, positive end expiratory pressure; FiO<sub>2</sub>, fraction of inspired oxygen.

related dyspnea with  $O_2$  desaturation. Exercises included sit-to-stand exercises and free walking without equipment, with a continuous monitoring of  $SpO_2$ , RR and heart rate. These activities were performed daily for 20 to 30 minutes. COT was gradually reduced from 10 l/min to 6l/min.

During the hospitalization period, medical therapy included hydroxychloroquine, methyl-prednisolone, bronchodilators, ceftriaxone, morphine, piperacillin-tazobactam and heparin.

At discharge, on 58<sup>th</sup> day, the patient was asymptomatic and eupneic with  $O_2$  2l/min. Two consecutive test results for SARS-CoV-2 were negative.

## Discussion

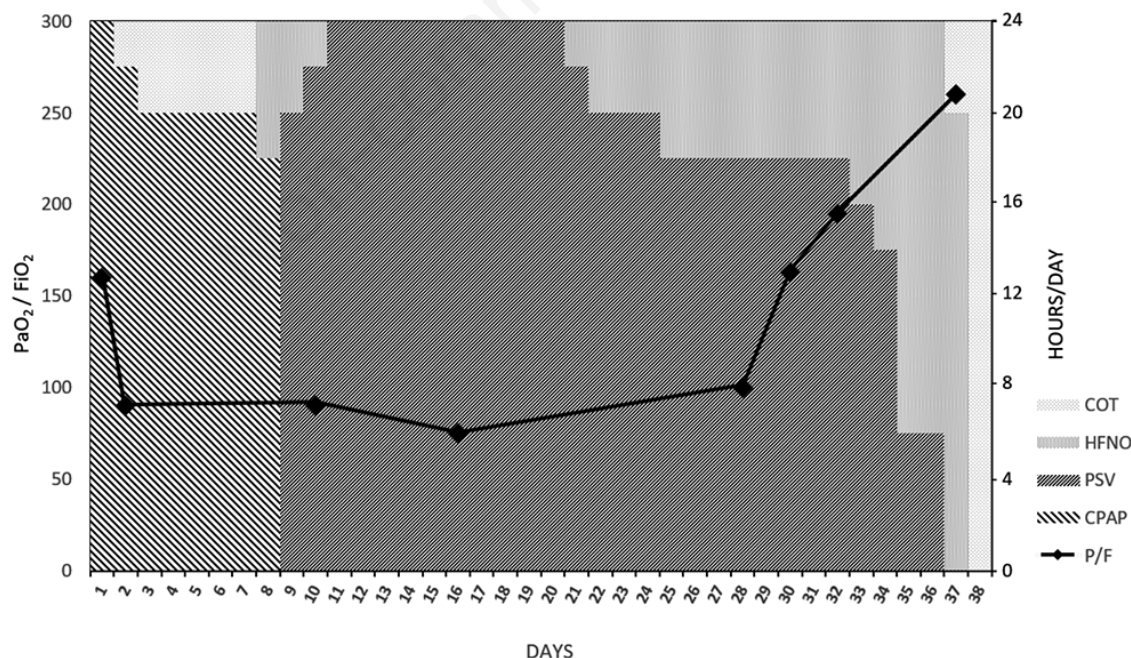
The case report describes the prolonged follow-up of a patient affected by COVID-19 severe AHRF ventilated for a long time on progressive respiratory support with CPAP, HFNO, NIV, and body positioning. The patient was successfully weaned from non-invasive support and discharged at home after almost two months.

NIV efficacy in hypoxemic patients is controversial. A recent meta-analysis conducted in severe AHRF showed that NIV reduced intubation and mortality rates [8]. However, it may delay endotracheal intubation increasing mortality rate [4,9]. Around 30% of NIV failure rate was observed in SARS and other viral pandemics [10,11]. Little is known about NIV efficacy in COVID-19. The scanty data showed more chances of success in patients with  $PaO_2/FiO_2 >150$  [12]. Furthermore, it has been observed that patients with COVID-19 ARDS who were mechanically ventilated have longer ICU stay, which makes administration of care more difficult. In patients surviving to severe ARDS, ICU length of stay

was 26 (13-43) days in COVID-19 compared to 14 (7-23) days in others ARDS [13,3].

This was the case of our patient with prolonged NIV sessions and not eligible to invasive ventilation because of multiple comorbidities. Thus, NIRS was the only way to try to “bridge” the patient out of viral infection starting from COT, CPAP and HFNO to incrementing the support to NIV [14]. However, based on our experience, the longer NIV is required the more is likely to fail because of intolerance and adverse effects, resulting in intubation and/or death.

This was a challenging case with a prolonged 32 days-period of NIRS 18 to 24 hours/day with  $PaO_2/FiO_2 <100$  for 28 consecutive days. During some periods with NIV, the patient had a  $V_t >8ml/kg$  PBW. As already described, high  $V_t$  may increase transpulmonary pressure in the dependent regions provoking P-SILI [9]. Implementation of higher inspiratory pressures was not effective to reduce inspiratory effort, most likely due to the patient high inspiratory drive. Thus, RPTs increased PEEP up to 15 cmH<sub>2</sub>O with a successful reduction of  $V_t$  in the safe range. High PEEP may balance the patient’s strong effort and counteract the P-SILI by homogeneous distribution of lung stress, better gas exchange and less efficient diaphragmatic contraction [15]. A hot topic during the pandemic was whether pronation could improve oxygenation during NIRS. A recent meta-analysis have shown feasibility, safety and oxygenation improvements in awake patients with COVID-19 [16]. In our case, oxygenation improved but it was not sustained after re-supination. Unfortunately, after the first week, the attempt to pronation caused a sudden drop in oxygenation. We may hypothesize that the effort to reach prone position in an awake patient with AHRF might be excessive in oxygen consumption. Given the difficulty to maintain continuous and prolonged NIV sessions, we used HFNO as a bridge to improve patient tolerance.



**Figure 1.** Daily usage of ventilatory support and changes of  $PaO_2/FiO_2$  ratio during the hospital stay. CPAP, continuous positive airway pressure; PSV, pressure support ventilation; HFNO, high flow nasal oxygen; COT, conventional oxygen therapy. On the left side, arterial oxygen pressure/fraction of inspired oxygen ( $PaO_2/FiO_2$ , P/F) during the hospital stay represented by a black solid line with diamonds. On the right side, hours/day for each ventilatory support. Different ventilatory modalities are depicted with different ink grey colors, as reported in the graph legend.

The use of a ventilator with dual NIV-HFNO mode facilitated the treatment, reducing the requirement of two devices [17]. After day 28, the patient started to have a fast oxygenation increase.

A limitation of this report is the lack of lung imaging during recovery. Another limitation was that due to the overload quantity of patients with COVID-19, we did not organize a specific rehabilitation program for these patients. Nevertheless, referral to rehabilitation facilities in Italy was very limited. Most of them were closed or converted to acute care hospitals. In our case, after the acute phase of respiratory failure, functional exercises were set up with the support of conventional O<sub>2</sub> as recommended by Vitacca *et al.* [18].

In our HDU RPTs were the frontline key personnel with a solid practical and theoretical knowledge in NIRS management, in particular in mask positioning and asynchronism detection. It is well established that the ability of a team is related to successful NIRS, making the treatment tolerable even for 24 hrs/day. Rate of NIV failure decrease when experience grows [19].

## Conclusions

Many patients with AHRF during the COVID-19 outbreak could not be escalated to invasive mechanical ventilation due to poor functional status and saturated ICU. Even if it still not shared by international guidelines, NIRS has been implemented successfully.

This case report shows how a skilled and experienced team made prolonged non-invasive support feasible for COVID-19 pneumonia, even outside ICU. A team with trained respiratory physiotherapists may have a particular important role in the successful implementation of NIV to improve hypoxemia and save lives.

## References

- Grasselli G, Zangrillo A, Zanella A, et al. Baseline characteristics and outcomes of 1591 patients infected with SARS-CoV-2 admitted to ICUs of the Lombardy Region, Italy. *JAMA* 2020;323:1574.
- Kangelaris KN, Ware LB, Wang CY, et al. Timing of intubation and clinical outcomes in adults with acute respiratory distress syndrome. *Crit Care Med* 2016;44:120–9.
- Bellani G, Laffey JG, Pham T, et al. Noninvasive ventilation of patients with acute respiratory distress syndrome. Insights from the LUNG SAFE study. *Am J Respir Crit Care Med* 2017;195:67–77.
- Tonelli R, Fantini R, Tabbi L, et al. Early Inspiratory effort assessment by esophageal manometry predicts noninvasive ventilation outcome in de novo respiratory failure. A pilot study. *Am J Respir Crit Care Med* 2020;202:558–67.
- Antonelli M, Conti G, Moro M, et al. Predictors of failure of noninvasive positive pressure ventilation in patients with acute hypoxemic respiratory failure: a multi-center study. *Intensive Care Med* 2001;27:1718–28.
- Winck JC, Ambrosino N. COVID-19 pandemic and non invasive respiratory management: Every Goliath needs a David. An evidence based evaluation of problems. *Pulmonology* 2020;26:213–20.
- Vergano M, Bertolini G, Giannini A, et al. Clinical ethics recommendations for the allocation of intensive care treatments in exceptional, resource-limited circumstances: the Italian perspective during the COVID-19 epidemic. *Crit Care* 2020;24:165.
- Liu Y-J, Zhao J, Tang H. Non-invasive ventilation in acute respiratory failure: a meta-analysis. *Clin Med* 2016;16:514–23.
- Brochard L, Slutsky A, Pesenti A. Mechanical ventilation to minimize progression of lung injury in acute respiratory failure. *Am J Respir Crit Care Med* 2017;195:438–42.
- Cheung TMT, Yam LYC, So LKY, et al. Effectiveness of noninvasive positive pressure ventilation in the treatment of acute respiratory failure in severe acute respiratory syndrome. *Chest* 2004;126:845–50.
- Belenguier-Muncharaz A, Reig-Valero R, Altaba-Tena S, et al. [Utilización de la ventilación mecánica no invasiva en neumonía grave por virus H1N1]. [Article in Spanish]. *Med Intensiva* 2011;35:470–7.
- Mukhtar A, Lotfy A, Hasanin A, El-Hefnawy I, El Adawy A. Outcome of non-invasive ventilation in COVID-19 critically ill patients: A Retrospective observational Study. *Anaesth Crit Care Pain Med* 2020;39:579–80.
- COVID-ICU Group on behalf of the REVA Network, COVID-ICU Investigators. Clinical characteristics and day-90 outcomes of 4244 critically ill adults with COVID-19: a prospective cohort study. *Intensive Care Med* 2021;47:60–73.
- Wilson ME, Majzoub AM, Dobler CC, et al. Noninvasive ventilation in patients with do-not-intubate and comfort-measures-only orders: A systematic review and meta-analysis. *Crit Care Med* 2018;46:1209–16.
- Yoshida T, Grieco DL, Brochard L, Fujino Y. Patient self-inflicted lung injury and positive end-expiratory pressure for safe spontaneous breathing. *Curr Opin Crit Care* 2020;26:59–65.
- Pb S, Mittal S, Madan K, et al. Awake prone positioning in non-intubated patients for the management of hypoxemia in COVID-19: A systematic review and meta-analysis. *Monaldi Arch Chest Dis* 2021;91:1623.
- Lazzeri M, Lanza A, Bellini R, et al. Respiratory physiotherapy in patients with COVID-19 infection in acute setting: a Position Paper of the Italian Association of Respiratory Physiotherapists (ARIR). *Monaldi Arch Chest Dis* 2020;90:1285.
- Vitacca M, Lazzeri M, Guffanti E, et al. Italian suggestions for pulmonary rehabilitation in COVID-19 patients recovering from acute respiratory failure: results of a Delphi process. *Monaldi Arch Chest Dis* 2020;90:1444.
- Karim HMR, Burns KEA, Ciobanu LD, et al. Noninvasive ventilation: education and training. A narrative analysis and an international consensus document. *Adv Respir Med* 2019;87:36–45.