

DOI: [10.4081/monaldi.2022.2142](https://doi.org/10.4081/monaldi.2022.2142)

Post severe COVID-19 infection lung damages study. The experience of early three months multidisciplinary follow-up)

Lucrezia De Michele¹, Paola Pierucci^{2,3}, Guido Giovannetti⁴, Michele De Ceglie⁵, Michela Dimitri³, Alessandra Mirabile⁵, Vitaliano Quaranta⁶, Arnaldo Scardapane⁵, Carlo D'Agostino¹, Giovanna Elisiana Carpagnano²

¹Cardio Thoracic and Vascular Department, University Hospital Policlinic of Bari

²Cardiothoracic Department, Respiratory and Critical Care Unit, Bari Policlinic University Hospital, Bari

³Section of Respiratory Diseases, Department of Basic Medical Science Neuroscience and Sense Organs, University of Bari 'Aldo Moro', Bari

⁴Department of Biomedical Sciences and Human Oncology, University of Bari "Aldo Moro", Medical School, Bari

⁵DIM, Interdisciplinary Department of Medicine, Section of Diagnostic Imaging, University of Bari "Aldo Moro" Medical School, Bari

⁶Respiratory Unit, Di Venere Hospital, Bari, Italy

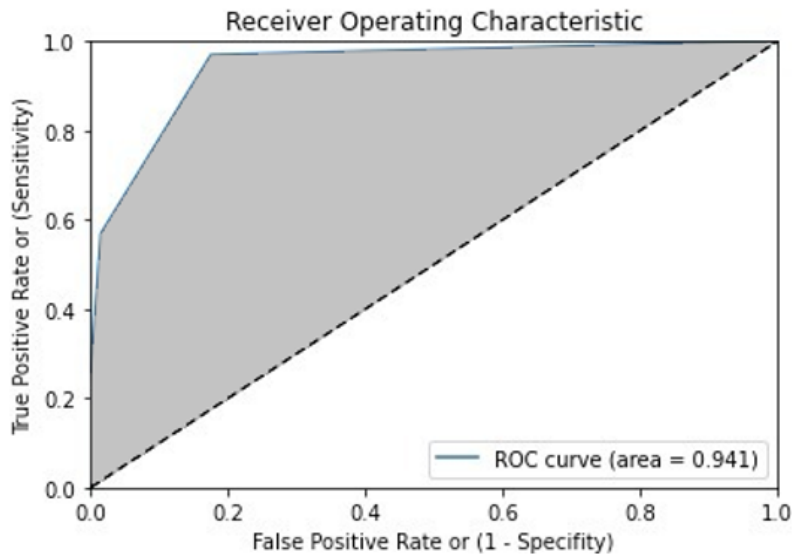
Correspondence: Paola Pierucci MD MSc, Cardiothoracic Department, Respiratory and Critical care Unit Bari Policlinic University Hospital; Section of Respiratory Diseases, Dept. of Basic Medical Science Neuroscience and Sense Organs, University of Bari 'Aldo Moro' School of Medicine, Piazza G. Cesare 12, 70122 Bari, Italy. Tel. +39.080.5591111. E-mail: paola.pierucci@policlinico.ba.it

Key words: ARDS; cardiorespiratory sequelae; pulmonary emboli; non-invasive ventilation; high CPAP; long COVID-19.

Supplementary Table 1. Radiologic outcomes of patients enrolled.

	CT	LUS	p-value
No signs of ILD, n (%)	16 (42.1%)	14 (36.8%)	0.75
Signs of ILD, n (%)	22 (57.9%)	24 (63.2%)	0.81
Mild, n (%)	15 (39.5%)	16 (42.1%)	0.87
Moderate, n (%)	7 (18.4%)	8 (21.1%)	0.81
Severe, n (%)	0 (0.0%)	0 (0.0%)	-
Consolidations, n (%)	0 (0.0%)	0 (0.0%)	-
Pleural effusion, n (%)	0 (0.0%)	0 (0.0%)	-

CT, computed tomography; LUS, lung ultrasonography score; ILD, interstitial lung disease. No signs of ILD corresponding to CT score=0 and LUS score=0. Signs of ILD corresponding to CT score=1-25 and LUS score=1-36. Mild ILD corresponding to CT score=1-5 and LUS score=1-7. Moderate ILD corresponding to CT score=6-12 and LUS score=8-18. Severe ILD corresponding to CT score 13-25 and LUS score 19-36.



	ILD	No ILD	
LUS ≥ 1	63	22	PPV: 74.1% FP: 25.9%
LUS = 0	103	2	NPV: 98.1% FN: 1.9%
	Sens.: 96.9%	Spec.: 82.4%	

K: 0.74 Acc.: 87.4% LR⁺: 5.51 LR⁻: 0.04

Supplementary Figure 1. Receiver operating characteristic (ROC) curve analysis of comparison between CT scan and lung ultrasonography for interstitial lung disease assessment. Receiver operating characteristic (ROC) and Cohen's kappa analysis was carried out to compare CT scan and LUS findings in the assessment of interstitial lung disease. ROC, receiver operating characteristic; ILD, interstitial lung disease; K, Cohen's kappa; Sens., sensitivity; Spec., specificity; PPV, positive predictive value; NPV, negative predictive value; Acc., accuracy; LR⁺, likelihood ratio positive; LR⁻, likelihood ratio negative; FP, false positive; FN, false negative.