

Subcutaneous finger cardioverter-defibrillator in low weight paediatric patients: a case series

Berardo Sarubbi¹, Gabriella Farina², Diego Colonna¹, Anna Correra¹, Emanuele Romeo¹, Giovanni Domenico Ciriello¹, Guido Oppido², Maria Giovanna Russo³

¹Adult Congenital Heart Disease Unit, Monaldi Hospital, Naples; ²Paediatric Cardiac Surgery Unit, Monaldi Hospital, Naples, ³Paediatric Cardiology Unit, "L.Vanvitelli" University, Monaldi Hospital, Naples, Italy

Abstract

Placement of traditional transvenous implantable cardioverter defibrillator (ICD) system in low-weight children is often difficult

Correspondence: Dr. Berardo Sarubbi, Adult Congenital Heart Disease Unit, Monaldi Hospital, Via Leonardo Bianchi, 80131 Naples, Italy. Tel. +39.081.7065288. E-mail: berardo.sarubbi@virgilio.it

Key words: Subcutaneous finger cardioverter defibrillator; ventricular arrhythmias; sudden death; inheritable channelopathies; long QT syndrome

Conflict of interest: The authors declare that they have no conflicts of interest to report regarding the present study, and all authors confirm accuracy.

Funding: The authors received no specific funding for this study. All authors report no relationships that could be construed as a conflict of interest.

Ethical approval and consent to participate: All procedures performed in studies involving human participants were in accordance with the Ethical Standards of the Institutional and/or national Research Committee and with the 1964 Helsinki declaration and its later amendments or comparable ethical standards. Informed consent was obtained from all individual participants included in the study.

Acknowledgements: Special thanks to the nursing staff and to the head nurse Mrs. Assunta Carandente for their support in maintaining high-quality standard of care for our patients. We thank furthermore Dr. Nadia Puzone and Dr. Gabriella Piccolo, data manager, for data collecting and analysis and Dr. Cecilia Spinelli Barrile for her professional support in reviewing the English language and style of the manuscript.

Received for publication: 15 January 2022.
Accepted for publication: 20 June 2022.

Publisher's note: All claims expressed in this article are solely those of the authors and do not necessarily represent those of their affiliated organizations, or those of the publisher, the editors and the reviewers. Any product that may be evaluated in this article or claim that may be made by its manufacturer is not guaranteed or endorsed by the publisher.

©Copyright: the Author(s), 2022

Licensee PAGEPress, Italy

Monaldi Archives for Chest Disease 2023; 93:2203

doi: 10.4081/monaldi.2022.2203

This article is distributed under the terms of the Creative Commons Attribution-NonCommercial International License (CC BY-NC 4.0) which permits any noncommercial use, distribution, and reproduction in any medium, provided the original author(s) and source are credited.

because of their vessel size, the elevated risk of lead malfunction and failure, children's growth and various anatomic constraints, creating the need for alternative solutions. Subcutaneous array leads combined with an abdominally placed ICD device can minimize the surgical approach. In this case series, we analyse the data behind indications for subcutaneous finger cardioverter defibrillator (SFC) and discuss the preliminary clinical experience in low-weight children. We considered 4 consecutive children (mean age 3.9 years, range 3-5.5 years, mean body weight 17.6 kg, range 14-23 kg) who underwent SFC implant from April 2016 to August 2020. All patients showed a good compliance to the device system with no complications (infections or skin erosions). No patients experienced in the observation period (mean time 44.5±21.5 months) sustained ventricular arrhythmias requiring shocks. No inappropriate shocks released by the device occurred. No significant changes were observed in LET (lowest energy tested) performed around 24 months of follow-up. All patients showed a good compliance and stable atrio-ventricular sensing and pacing thresholds. In smaller children in whom a transvenous approach is not feasible or not possible for anatomic reasons, the SFC appears to be a safe method to prevent SCD with little surgical trauma and preservation of an intact vascular system, providing an adequate bridge to transvenous ICD or subcutaneous ICD implant late in the life.

Introduction

Implantable cardioverter defibrillators (ICD) have been shown to be safe and effective in preventing sudden cardiac death (SCD) in paediatric patients who are survivors of cardiac arrest in the absence of reversible causes and for high-risk patients with inheritable disorder channelopathies, cardiomyopathies or congenital heart disease [1-3]. However, placement of traditional transvenous ICD system in low-weight children may be problematic because of their vessel size, elevated rate of lead malfunction and failure, children's growth and various anatomic constraints, creating the need for alternative solutions.

Subcutaneous implantable cardioverter defibrillator is not suitable for very young low-weight patients and epicardial defibrillation patch electrodes require a large thoracotomy associated with a considerable perioperative risk. Conversely, subcutaneous array leads combined with an abdominally placed ICD device can minimize the surgical approach [4-6].

The purpose of this case series was to analyse our experience in terms of appropriateness and feasibility of subcutaneous finger cardioverter-defibrillator (SFC) in low weight children, analysing intermediate and long-term follow-up.

Methods

This is an observational, retrospective, non-randomized, standard-of-care case-series study on SFCD implantation and follow-up in low-weight children.

The study complied with the Declaration of Helsinki and its later amendments. Informed consent was obtained from patient's guardians.

Patients' selection

All the patients aged less than 6 years, who underwent SFCD implantation between April 2016 and August 2020 were included in the study.

Inclusion criteria (specific indications for SFCD implantation): international guidelines were followed for ICD implantation [1].

In particular, the indication for SFCD was considered for children younger than 6 years, with low-weight who had contraindications for S-ICD or ICD implantation due to the lack of available favourable venous access or possible venous occlusion following intracavitary leads positioning, elevated rate of lead malfunction and failure and finally when pacing therapy for bradycardia support was hypothesized.

Implantation procedure

Each patient underwent placement of a single finger subcutaneous defibrillation lead [5,7]. Under general anaesthesia, the apex

of the heart was exposed via a subxiphoid incision. An epicardial, bipolar pace/sense lead was attached to the apex of the right ventricle and, if required for the patient, to the right atrium (Figure 1A) and then sutured to the myocardium after confirmation of good pacing thresholds. A tunneling tool shaped according to the anatomy of the patient and placed inside an introducer sheath, was used to create a subcutaneous tunnel (Figure 1B) at the level of the seventh intercostal space and extended posteriorly as close to the spine as possible (Figure 1C). A subcutaneous lead was then advanced into the sheath. After testing the pace/sense lead, the leads were connected to the ICD generator that was secured in a preperitoneal pocket in the right or left upper quadrant. Defibrillation threshold testing was then performed.

Regarding ICD testing, our practice was to use a "lowest energy tested" (LET) that successfully terminated the tachyarrhythmia as a surrogate for a true defibrillation threshold (DFT), with shocks being delivered between the ICD device ("active can") and the subcutaneous array lead serving as cathode. The LET protocol involved 2 successive shocks. The first was generally programmed at 14-16 J. If the first shock failed, the second was programmed at 20 J. A minimum of a 10 J safety margin was considered acceptable. The ICDs were programmed for single zone detection of ventricular fibrillation at rates greater than 214-231 beats per minute.

Acute efficacy of the system was defined as successful conversion of induced ventricular tachycardia/ventricular fibrillation (VT/VF) by an intraoperative defibrillation test.

Data collection

Categories of data collection included the following:

- patients' demographics;

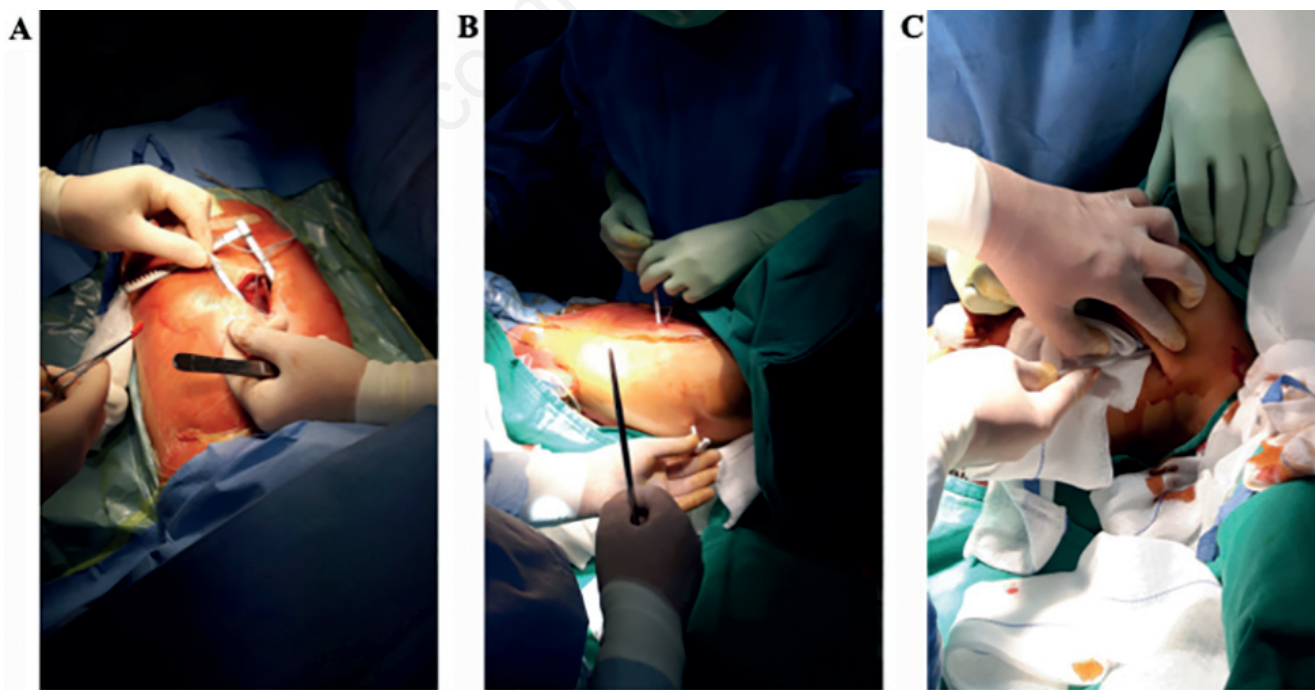


Figure 1. Implantation procedure. A) Epicardial, bipolar pace/sense lead attached to right atrium and ventricle. B) Creation of a tunnel at the level of the seventh intercostal space. C) Extension of the tunnel posteriorly as close to the spine as possible and advancing of the subcutaneous lead into the sheath.

- preimplant clinical data (underlying cardiac disease diagnosis; a copy of the preimplant 12-lead ECG; drug therapy; indication for ICD placement and motivation for use of the SFCD);
- implant characteristics: implant techniques, results of defibrillation testing, initial SFCD programming, atrio-ventricular sensing and stimulation threshold at implant, a copy of the postprocedural chest x ray (Figure 2), procedural complications, and postprocedural length of stay.

Acute complications were defined as those occurring before discharge from the hospital or within 30 days from the implant.

Therapies were classified as appropriate if delivered for VT/VF; otherwise, they were considered inappropriate (IAS).

Follow-up

Patients were regularly followed between April 2016 and December 2020 at Paediatric CHD Unit and Arrhythmic PMK/ICD outpatient clinic in accordance with the following protocol: patients underwent clinical evaluation, device interrogation by telemetry, and ECG at 1 and 3 months and every 3-4 months thereafter. Trans-thoracic echocardiography, Holter monitoring, and X-ray were performed every 12 months. Nearly around 24

months of follow-up the first three patients (#1, #2, #3) underwent LET testing as already stated [1]. The outcomes analysed included patients' characteristics, and the presence of long-term complications. Moreover, during follow up were assessed the atrio-ventricular sensing and pacing threshold, the presence of all post-operative VF episodes, presence and time to the first appropriate shock, first inappropriate shock, and first appropriate and inappropriate events without shock delivery.

Data analysis

Data are presented as mean \pm standard deviation or median (interquartile range) for continuous variables as appropriate and as frequencies and percentages for dichotomous variables. The study is descriptive, with no inferential statistics performed.

Results

All the patient's data are reported in Tables 1 and 2.

Baseline patient characteristics: Four consecutive children

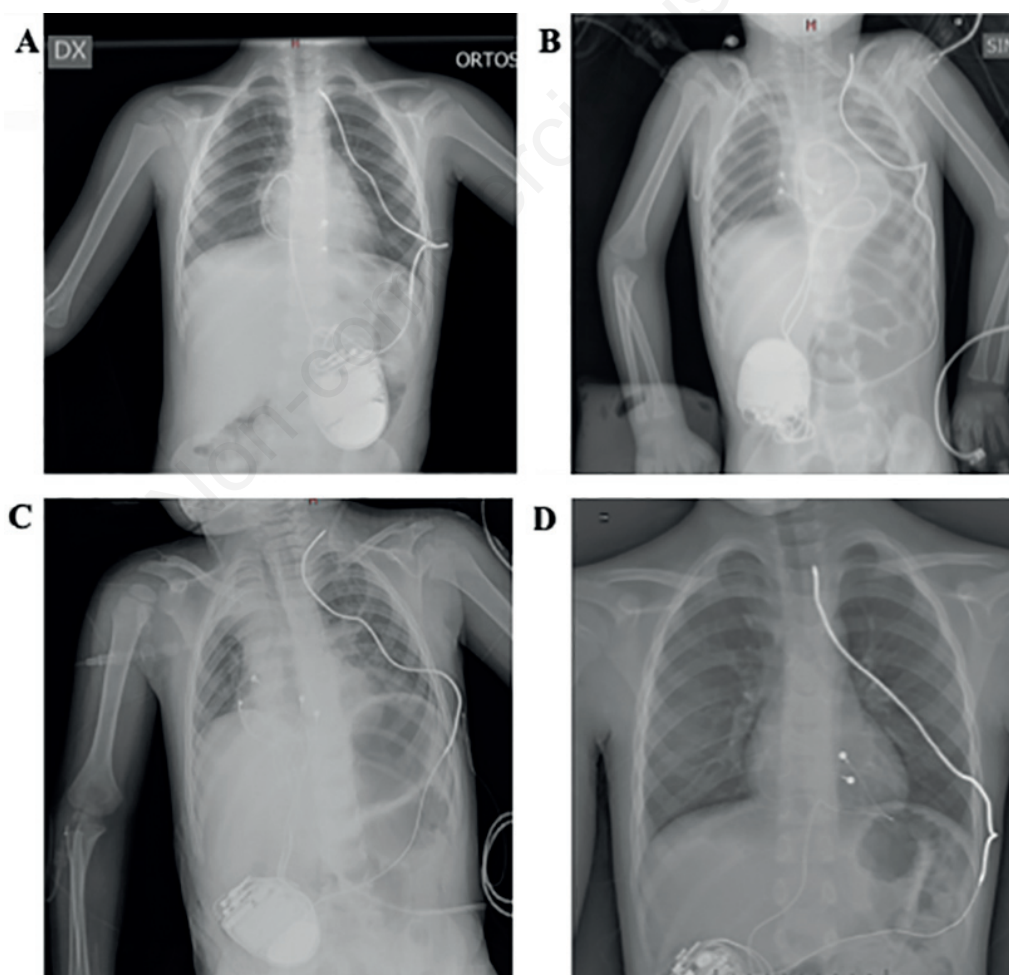


Figure 2. Postimplant chest X-rays. A) Patient #1 (3 years 8 months old/F, 14 kg, 0.61 m² BSA). B) Patient #2 (3 years old/M, 17.5kg, 0.66m² BSA). C) Patient #3 (3 years 5 months old/M, 16 kg, 0.64m² BSA). D) Patient #4 (5 years 6 months old/M, 23 kg, 0.9m² BSA).

(mean age 3.9 years, range 3-5.5 years, 1 female) who underwent SCD implant from April 2016 to August 2020 were included in the study. Mean weight at implant was 17.6±3.8 Kg, height 103.5±14.4 cm, body mass index 16.5±2.3 and body surface area 0.7±0.1. Three patients were affected by long QT syndrome (LQTS). Notably, one of these presented Jervell and Lange-Nielsen syndrome. One patient was affected by familial Brugada syndrome. Primary prevention was the indication only in one.

Procedural data: Two patients had implanted an abdominal ICD device combined with a single subcutaneous array with one finger only and dual chamber bipolar epicardial sensing and pacing leads. The other two had a single chamber (ventricle) epicardial sensing and pacing lead. In all patients a successful defibrillation test was performed. No complications were reported during the procedures. Three patients had an optimal LET (14-16J), only one required a subsequent 20J shock.

Follow-up: The post-operative course was uneventful, and all patients were discharged between 4 and 5 days after the procedure. Mean follow-up was 44.5±21.5 months (range 68-16 months). No acute (within 30 days of implant) complications (infections or skin erosions) were reported. No significant differences were observed over the time in the atrio-ventricular sensing and pacing threshold. During the follow-up no patients experienced appropriate or inappropriate shocks. No significant changes were observed in LET (lowest energy tested) performed after 24 months of follow-up in the first three patients. Lead migration after placing of subcutaneous defibrillation leads was not observed on X-ray scan performed during the follow-up. The outcome was uneventful and the cosmetic results were excellent. There were no device infections,

lead fractures, device erosions, or other ICD-related complications during the follow-up period.

Discussion

In very low weight paediatric patients, life-threatening arrhythmias requiring ICD placement are quite rare. Secondary prevention of SCD is a generally accepted indication for ICD therapy. Primary prevention still remains controversial, but may be justifiable in selected cases [1,2]. However, due to improved risk stratification (e.g., in hypertrophic cardiomyopathy and in repaired congenital heart disease) and due to the recognition of inherited arrhythmias at high risk there is an increasing number of low-weight young patients selected for ICD treatment.

Very young patients pose an important challenge regarding ICD implantation. The small caliber vein dimensions in young children place them at high risk for vessel injury and vascular occlusion in patients, especially in patients with complex congenital heart disease, and paucity of venous access in patients requiring lifelong device therapy. Improvements of endovascular leads and devices have facilitated ICD implantation; but unfortunately, it has been documented a high rate of complications in paediatric patients, especially lead failure that is most common and it is related to somatic growth [8-9]. Complications have also been reported when epicardial defibrillation patch electrodes were used instead of endocardial leads [10]. SCD systems minimizing the perioperative risk and complications and our data suggested that should be applied in the

Table 1. Baseline clinical characteristics of the case series.

Pt.	Sex	Age	Weight (kg)	High (cm)	BMI (kg/m ²)	BSA (m ²)	Diagnosis	Indication	Drugs at discharge
#1	F	3 years 8 months	14	98	14.58	0.61	LQTS	Secondary prevention	Propranolol
#2	M	3 years	17.5	95	19.39	0.66	LQTS	Secondary prevention	Propranolol
#3	M	3 years 5 months	16	96	17.36	0.64	LQTS (JLNS)	Primary prevention	Propranolol
#4	M	5 years 6 months	23	125	14.7	0.9	Brugada syndrome	Secondary prevention	None

BMI, body mass index; BSA, body surface area; LQTS, long QT syndrome; JLNS, Jervell e Lange-Nielsen syndrome.

Table 2. Procedural data and outcome of the case series.

Pt.	Time of implant - ICD type	Program - modality	Sensing at discharge (mV)	Estimate threshold discharge (V)	LET at implant	Sensing at last F-U (mV)	Estimate threshold at last F-U	Intra-op. def. test	Complications (infections - skin erosion)	AS	IAS	LET at 24 months	F-U (months)	Outcome
#1	April 2016 Medtronic Evera	VI 40bpm	R wave 13.4	Vn: 0.5/0.4	14 J	R wave 9.4	Vn: 0.75/0.4ms	Yes	None	No	No	16 J	68	Good
#2	November 2017 Medtronic Evera	AAI/DDD 80/130bpm	P wave 4.1	Atr: 0.25/0.4ms Vn: 0.75/0.4ms	16 J	P wave 3.8 R wave 3.5	Atr: 0.25/0.4ms Vn: 1.0/0.4ms	Yes	None	No	No	16 J	49	Good
#3	March 2018 Medtronic Evera	AAI/DDD 60/130bpm	P wave 3.9 R wave 4.6	Atr: 0.75 Vn: 1.5	16 J	P wave 4.3 R wave 3.5	Atr: 0.5/0.4ms Vn: 0.5/0.4ms	Yes	None	No	No	16 J	45	Good
#4	August 2020 Medtronic Evera	VI 40bpm	R wave 8.5	Vn: 1.0	20 J	R wave 7.5	Vn: 0.75/0.4ms	Yes	None	No	No	n.a.	16	Good

Atr, atrium; Vn, ventricle; AS, appropriate shock; IAS, inappropriate shock; LET, lowest energy tested; F-U, follow-up; n.a., not available.

low-weight paediatric patients as an adequate bridge to transvenous ICD or S-ICD implant late in the life. This case-series describes four cases of inheritable channelopathies in which such a system was successfully implanted. The used configuration involved a single-finger subcutaneous defibrillation lead used as the anode with an active, abdominally placed generator as the cathode.

In our series, the single lead had the advantage of requiring significantly less subcutaneous dissection compared with a multi-fingers array or patch. Furthermore, this configuration achieved successful defibrillation with low LETs. The post-operative course was for all uneventful, without any complications. There were no surgical morbidity and no short- or long-term ICD-related complications, such as infection, lead fracture, and device erosion. Sensing and pacing thresholds of the epicardial leads remained unchanged from the time of implantation. No patients experienced appropriate or inappropriate shocks.

While little can be definitively concluded from 4 patients, our experience suggests that this system, using only one finger, is reliable and can be safely used in low-weight paediatric patients. The SFCD could provide an adequate bridge to transvenous ICD or subcutaneous ICD implant. This system could benefit very low-weight children in particular, but there are limitations. The long-term clinical course of DFT stability in a growing child is still unknown. As a result, additional testing would almost certainly be required.

Limitations

The main limitations of this study are the small sample size, the low event rate, the retrospective design of the analysis and the relatively limited follow-up period.

Conclusions

In smaller children in whom a transvenous approach is not feasible or for anatomic reasons not possible, the SFCD appears to be a safe method to prevent SD with little surgical trauma and preservation of an intact vascular system, providing an adequate bridge to transvenous ICD or S-ICD implant late in the life.

References

1. Priori SG, Blomström-Lundqvist C, Mazzanti A, et al. ESC Guidelines for the management of patients with ventricular arrhythmias and the prevention of sudden cardiac death: The Task Force for the Management of Patients with Ventricular Arrhythmias and the Prevention of Sudden Cardiac Death of the European Society of Cardiology (ESC). Endorsed by: Association for European Paediatric and Congenital Cardiology (AEPC). *Eur Heart J* 2015;36:2793-867.
2. Al-Khatib SM, Stevenson WG, Ackerman MJ, et al. AHA/ACC/HRS guideline for management of patients with ventricular arrhythmias and the prevention of sudden cardiac death: A report of the American College of Cardiology/American Heart Association Task Force on Clinical Practice Guidelines and the Heart Rhythm Society. *Heart Rhythm* 2018;15:e190-e252.
3. Drago F, Bloise R, Bronzetti G, et al. Italian recommendations for the management of pediatric patients under twelve years of age with suspected or manifest Brugada syndrome. *Minerva Pediatr* 2018;72:1-13.
4. Luedemann M, Hund K, Stertmann W, et al. Implantable cardioverter defibrillator in a child using a single subcutaneous array lead and an abdominal active can. *Pacing Clin Electrophysiol* 2004;27:117-9.
5. Madan N, Gaynor JW, Tanel R, et al. Single-finger subcutaneous defibrillation lead and “active can”: a novel minimally invasive defibrillation configuration for implantable cardioverter-defibrillator implantation in a young child. *J Thorac Cardiovasc Surg* 2003;126:1657-9.
6. Kaltman JR, Gaynor JW, Rhodes LA, et al. Subcutaneous array with active can implantable cardioverter defibrillator configuration: a follow-up study. *Congenit Heart Dis* 2007;2:125-9.
7. Stephenson EA, Batra AS, Knilans TK, et al. A multicenter experience with novel implantable cardioverter defibrillator configurations in the pediatric and congenital heart disease population. *Cardiovasc Electrophysiol* 2006;17:41-6.
8. Sherrid MV, Daubert JP. Risks and challenges of implantable cardioverter-defibrillators in young adults. *Prog Cardiovasc Dis* 2008;51:237-63.
9. Maisel WH, Kramer DB. Implantable cardioverter-defibrillator lead performance. *Circulation* 2008;117:2721-3.
10. Silka MJ, Kron J, Dunnigan A, Dick M 2nd. Sudden cardiac death and the use of implantable cardioverter-defibrillators in pediatric patients. *Circulation* 1993;87:800-807.