

The cardiac paradox of losing weight: a case of gastro-cardiac syndrome

Francesco Natale, Riccardo Molinari, Simona Covino, Roberta Alfieri, Giovanni Cimmino

Vanvitelli Cardiology Unit, Monaldi Hospital, Department of Translational Medical Sciences, University of Campania “Luigi Vanvitelli”, Naples, Italy

Abstract

Thanks to an unusual reversible cause of reflex syncope, a young physician avoided pacemaker implantation. We present the treatment of a bizarre case of gastro-cardiac syndrome, an often-overlooked clinical entity.

Correspondence: Francesco Natale, Vanvitelli Cardiology Unit, Monaldi Hospital, Department of Translational Medical Sciences, University of Campania “Luigi Vanvitelli”, Via Leonardo Bianchi, 80131 Naples, Italy.
Tel. +39.081.7064239.
E-mail: natalefrancesco@hotmail.com

Key words: bradycardia, cardiac pacemaker, electrophysiology, diet, weight loss.

Contributions: FN, substantial contributions to the conception, acquisition and analysis of data for the case report; RM, SC, RA, drafting the case report; GC, final approval of the version to be published.

Conflict of interest: the authors declare no conflict of interest

Ethics approval and consent to participate: no ethical committee approval was required for this case report by the Department, because this article does not contain any studies with human participants or animals. Informed consent was obtained from the patient included in this study.

Consent for publication: the patient gave written consent to use his personal data for the publication of this case report and any accompanying images.

Received: 16 August 2022.
Accepted: 3 September 2022.
Early view: 13 September 2022.

Publisher’s note: all claims expressed in this article are solely those of the authors and do not necessarily represent those of their affiliated organizations, or those of the publisher, the editors and the reviewers. Any product that may be evaluated in this article or claim that may be made by its manufacturer is not guaranteed or endorsed by the publisher.

©Copyright: the Author(s), 2022
Licensee PAGEPress, Italy
Monaldi Archives for Chest Disease 2023; 93:2409
doi: 10.4081/monaldi.2022.2409

This article is distributed under the terms of the Creative Commons Attribution-NonCommercial International License (CC BY-NC 4.0) which permits any noncommercial use, distribution, and reproduction in any medium, provided the original author(s) and source are credited.

Case Report

A 40-year-old patient presented to our Cardiology Department with a traumatic transitory loss of consciousness. This episode occurred after a brisk walk and was preceded by prodromes such as dizziness and pallor. The patient was afebrile and eupneic at the time of our visit, with blood tests such as blood count, inflammation markers, electrolyte profile, and hepato-renal function all normal. The 12-lead ECG revealed sinus bradycardia but no other abnormalities.

The patient was a physician who had previously reported being in good health: he had never collapsed or displayed warning symptoms such as chest pain or palpitations. There were no cardiovascular risk factors reported: he never smoked, worked out regularly (mostly running), and had no family history of ischemic heart disease or sudden cardiac death. There was no mention of hypertension or diabetes. Furthermore, he had previously undergone a cardiovascular examination for amateur physical activity, with no pathological findings.

A 24h ECG Holter monitoring was prescribed based on the personal history (Figure 1A). The Holter ECG revealed sinus bradycardia (mean HR 56 bpm) with low atrial rhythm phases and some nocturnal pauses, the longest of which was 2.8s. There was also one case of supraventricular atrial ectopic beats with some non-conducted atrial extrasystoles described (Figure 1B). A previous 24-hour ECG Holter did not reveal any abnormalities. During the 24-hour registration period, the patient reported no symptoms. Furthermore, for his or her own decision, the patient has a cardiac MRI to rule out the presence of any cardiomyopathies. The exam was performed in a III level center equipped with a 1.5 Tesla whole-body scanner and a dedicated cardiac multi-element phase-array refraction coil. The report revealed no obvious myocardial areas of altered tissue composition, well preserved contractile function, and mild septal hypertrophy consistent with the patient's physical activity.

In clinical suspicion for a situational syncopal event, a head-up tilt test (HUTT) was prescribed. The test was positive (cardioinhibitory syncope - VASIS IIb) with a 3s asystolic pause (Figure 1C). According to the current European Guidelines, in absence of predictable and reversible causes of syncope, a DDD pace-maker implantation (class IIa level B [1]) is suggested. Before to proceed with pacemaker implantation, taking into account the young age, we re-questioned the patient more accurately, looking for any reversible causes of reflex syncope. He told us that he placed the Elipse™ intragastric balloon about 5 months earlier and he excreted it just a couple of days before the syncope. The implantation occurred with no complications. He did not refer any symptoms related to the balloon placement, except for nausea, vomiting and abdominal cramps persisting for the first few days after the insertion and indicated as common side effects.

The Elipse™ intra-gastric balloon (Allurion Technologies, Wellesley, MA, USA) is a game-changing device in the field of bariatric endoscopic therapies. It can be implanted without sedation

or upper gastrointestinal endoscopy. It is folded inside a capsule that is connected to a filling catheter. After swallowing the capsule, the correct gastric positioning is confirmed using X-ray or fluoroscopy,

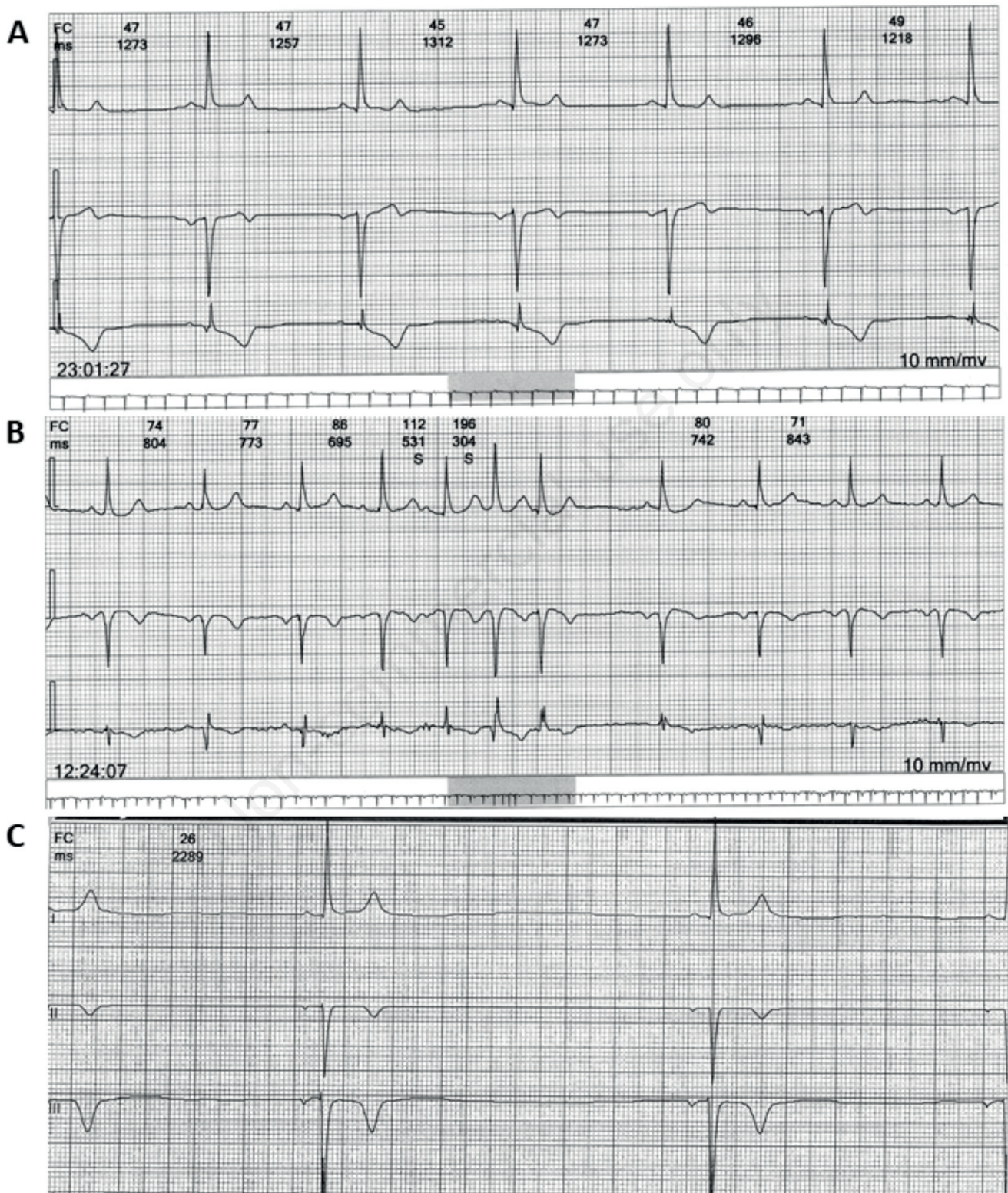


Figure 1. A,B) The 24h Holter monitoring showing persistent sinus bradycardia and atrial extrasystoles. C) A 3 leads from the head-up tilt test registration is reported showing a 3s asystolic pause.

and the balloon is filled with 500 ml of distilled water *via* a catheter. It also has a self-opening release valve that is set to open after approximately 16 weeks. The empty balloon is excreted through the gastrointestinal tract at the end of this period [2]. Several studies have demonstrated the safety and efficacy of Elipse™: Genco *et al.* demonstrated that its effectiveness in weight loss is comparable to other intragastric balloons despite a shorter duration in stomach (4 months *vs* 6 months) and non-endoscopic placement [3]. Only a few side effects were reported, the majority of which were related to the balloon's hyperinflation or deflation, esophagitis, and, in rare cases, pancreatitis, gastric outlet obstruction, or small bowel obstruction [4,5]. We believe that not enough research has been done on the cardiovascular side effects of balloon placement and the resulting pathophysiological changes.

Discussion

The gastro-cardiac syndrome [6], also known as Roemheld syndrome, is a well-defined nosographic entity that gastroenterologists and cardiologists frequently overlook. A variety of cardiac disorders coexist with gastrointestinal changes in this syndrome (GERD, aerophagia or other diseases involving the accumulation of gas in the intestine). Atrial extrasystoles and paroxysmal supraventricular tachycardia, as in our case, are common manifestations, which are frequently caused by gas accumulation below the diaphragm [7]. In some cases, particularly in hyperacid patients, cardiac symptoms are vagotonic in nature, ranging from sinus bradycardia to vasovagal syncope [8]. Prolonged therapy based on proton pump inhibitors, prokinetics, and other antacids, or resolution of gastrointestinal pathological substrates (aerophagia, hiatal hernia, *etc.*) can be used to treat symptoms [9]. According to some studies, the implantation of intragastric balloons may result in a decrease in gastric tone with enlargement of the proximal gastric segment and an increase in proximal gastric compliance. These phenomena appear to be related to increased vagal tone as a result of changes in heart rate variability [10]. Other studies have reported cardiac arrest and asystole following balloon placement [11].

Given these findings, we cannot rule out the possibility of an intragastric balloon playing a role in the development of gastrocardiac syndrome. Furthermore, it is likely that the pathophysiological changes caused by intragastric balloon placement are not immediately reversible with balloon removal. Following the removal of the balloon, a gastric ex-vacuo effect can alter gastric kinetics and intracavitary pressures, and some improper vagal stimulations on the anterior and posterior gastric plexuses may occur. It is not ruled out that the implantation of gastric balloons may cause such pathophysiological changes, as seen in other pathological conditions [12,13], resulting in prolonged parasympathetic stimulations and gastric remodeling.

In our young patient, who had no cardiovascular risk factors but was diagnosed with cardioinhibitory syncope at the HUTT, a possible cause-effect relationship between the Elipse™ excretion and the syncope cannot be ruled out. Given the possibility of this reflex being a reversible cause of syncope, we postponed pacemak-

er implantation in favor of a loop recorder implantation with a short-interval follow-up. In the following months, no more asystolic pauses or increased heart rate were recorded at monitoring, and, most importantly, no syncope occurred. After 8 months, the patient was no longer regarded as being at high risk of relapse, and the follow-up was postponed.

Conclusions

According to the current case report, cardiovascular screenings should be performed before, during, and after the implantation of gastric balloons to prevent cardiovascular events such as syncope or arrhythmias. More research on the pathophysiological changes in the cardiovascular system caused by these devices is required.

References

1. Brignole M, Moya A, de Lange FJ, et al. 2018 ESC Guidelines for the diagnosis and management of syncope. *Eur Heart J* 2018;39:1883-48.
2. Machytka E, Gaur S, Chuttani R, et al. Elipse, the first procedureless gastric balloon for weight loss: A prospective, observational, open-label, multicenter study. *Endoscopy* 2017;49:154-60.
3. Genco A, Ernesti I, Ienca R, et al. Safety and efficacy of a new swallowable intragastric balloon not needing endoscopy: Early Italian experience. *Obes Surg* 2018;28:405-9.
4. Ienca R, Al Jarallah M, Caballero A, et al. The procedureless elipse gastric balloon program: Multicenter experience in 1770 consecutive patients. *Obes Surg* 2020;30:3354-62.
5. Angrisani L, Santonicola A, Vitiello A, et al. Elipse balloon: the pitfalls of excessive simplicity. *Obes Surg* 2018;28:1419-21.
6. Salvesen HA. [The gastrocardiac symptom complex]. [Article in Norwegian]. *Tidsskr Nor Laegeforen* 1959;79:987-8.
7. Jervell O, Lødøen O. The gastrocardiac syndrome. *Acta Med Scand* 1952;142:595-9.
8. Milovanovic B, Fiolipovic B, Mutavdzin S, et al. Cardiac autonomic dysfunction in patients with gastroesophageal reflux disease. *World J Gastroenterol* 2015;21:6982-9.
9. Saeed M, Bhandohal JS, Visco F, et al. Gastrocardiac syndrome: A forgotten entity. *Am J Emerg Med* 2018;36:1525.e5.
10. Layec S, Val-Laillet D, Heresbach D, Malbert CH. Gastric tone, volume and emptying after implantation of an intragastric balloon for weight control. *Neurogastroenterol Motil* 2010;22:1016-e266.
11. Cubattoli L, Barneschi C, Mastrocinque E, et al. Cardiac arrest after intragastric balloon insertion in a super-obese patient. *Obes. Surg* 2009;19:253-6.
12. Rafanelli M, Ungar A. High blood pressure and syncope: orthostatic hypotension as a link. *Monaldi Arch Chest Dis* 2016;84:729.
13. Carbone A, Avitabile V, Golino P, et al. ST-elevation during head up tilt test: a challenging case in syncope unit. *Monaldi*