

# Pulmonary embolism and gastric bleed with disseminated mucormycosis - treading dangerous waters

Nishant Kumar Chauhan<sup>1</sup>, Ashish Agarwal<sup>2</sup>, Naveen Dutt<sup>1</sup>, Taruna Yadav<sup>3</sup>, Rishabh Kochar<sup>1</sup>

<sup>1</sup>Department of Pulmonary Medicine; <sup>2</sup>Department of Gastroenterology; <sup>3</sup>Department of Diagnostic and Interventional Radiology, All India Institute of Medical Sciences (AIIMS), Jodhpur, India

## Abstract

Mucormycosis is an opportunistic infection seen in immunocompromised patients or in surgical and trauma settings with Mucorales wound contamination. In immunocompetent people,

disseminated mucormycosis is uncommon. To ensure survival, patients with mucormycosis require early diagnosis and aggressive treatment using a multi-modality approach. We present a case of disseminated mucormycosis in an immunocompetent patient who also had pulmonary embolism and gastrointestinal bleeding. A recent severe acute respiratory syndrome coronavirus 2 (SARS-CoV-2) infection, identified retrospectively by a positive IgM against SARS-CoV-2, was the only risk factor present. This report emphasizes the increased risk of mucormycosis and thromboembolic complications following a recent SARS-CoV-2 infection, as well as its successful treatment with medical therapy alone.

Correspondence: Dr. Rishabh Kochar, Department of Pulmonary Medicine, All India Institute of Medical Science (AIIMS), Jodhpur 342005, Rajasthan, India.  
Tel. +91.9460174456.  
E-mail: rishkochar@gmail.com

Key words: acute pulmonary embolism, COVID-19 complications, gastrointestinal mucormycosis, disseminated mucormycosis, cerebral mucormycosis.

Contributions: NKC, AA, RK, in patient diagnosis and management, manuscript drafting; ND, TY, involved in patient diagnosis and in manuscript drafting and reviewing. All the authors read and approved the final version of the manuscript and agreed to be accountable for all aspects of the work.

Conflict of interest: the authors declare that they have no competing interests, and all authors confirm accuracy.

Ethical approval: no ethical committee approval was required for this case report by the Department, because this article does not contain any studies with human participants or animals. Informed consent was obtained from the patient included in this study.

Consent for publication: written consent was obtained to use the patient's personal data, investigation and images for publication of this case report.

Received: 22 August 2022.  
Accepted: 28 October 2022.  
Early view: 25 November 2022.

Publisher's note: all claims expressed in this article are solely those of the authors and do not necessarily represent those of their affiliated organizations, or those of the publisher, the editors and the reviewers. Any product that may be evaluated in this article or claim that may be made by its manufacturer is not guaranteed or endorsed by the publisher.

©Copyright: the Author(s), 2022  
Licensee PAGEPress, Italy  
Monaldi Archives for Chest Disease 2023; 93:2418  
doi: 10.4081/monaldi.2022.2418

*This article is distributed under the terms of the Creative Commons Attribution-NonCommercial International License (CC BY-NC 4.0) which permits any noncommercial use, distribution, and reproduction in any medium, provided the original author(s) and source are credited.*

## Introduction

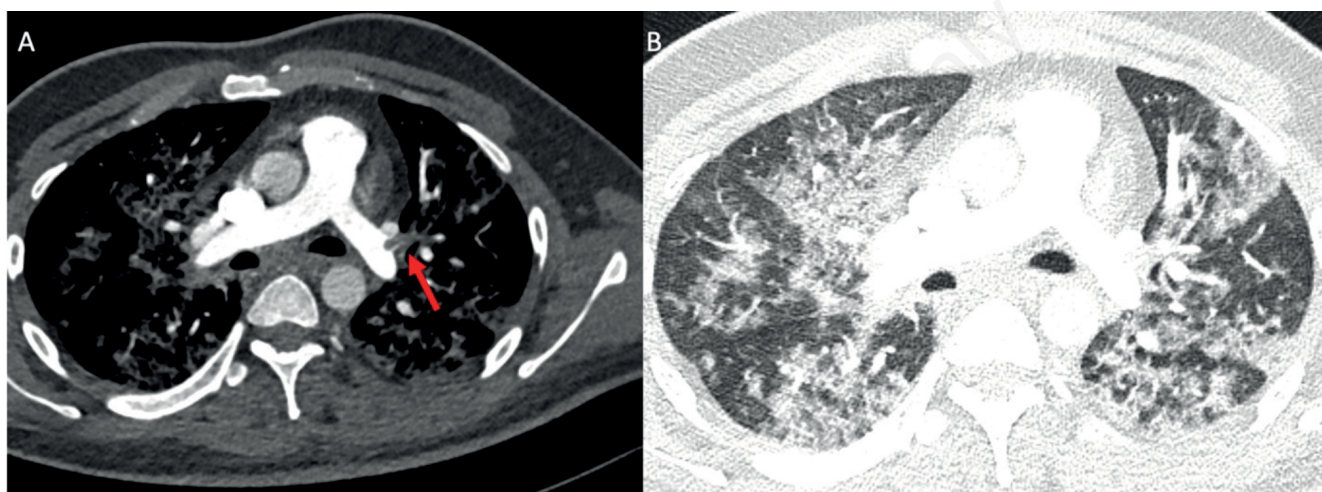
Mucormycosis is a rare but often life-threatening disease caused by fungi belonging to the order of Mucorales. Mucor is abundantly found in soil and decaying organic matter and produces airborne spores that are responsible for host infection. The risk factors for infection include diabetes mellitus, diabetic ketoacidosis, corticosteroid use, malignancy, organ transplant recipients, iron overload, AIDS, neutropenia, and malnutrition, whereas the infection is rarely seen in an immunocompetent host [1]. Commonly affected sites are rhino-cerebral, followed by pulmonary, whereas gastrointestinal infections are rare and comprise about 7% of reported cases [2]. Eradication of infection is achieved by a combination of antifungal therapy and surgical resection of the involved site. Earlier considered to be an uncommon infection, a sudden surge has occurred in mucormycosis cases following the COVID-19 pandemic. Due to reasons, not fully known, COVID-19 has predisposed patients to mucor infection [3,4]. We have also seen pulmonary thromboembolism in patients with COVID-19 with an unusual frequency [5]. Here we report an unusual presentation of disseminated mucormycosis and pulmonary embolism in an immunocompetent adult.

## Case Report

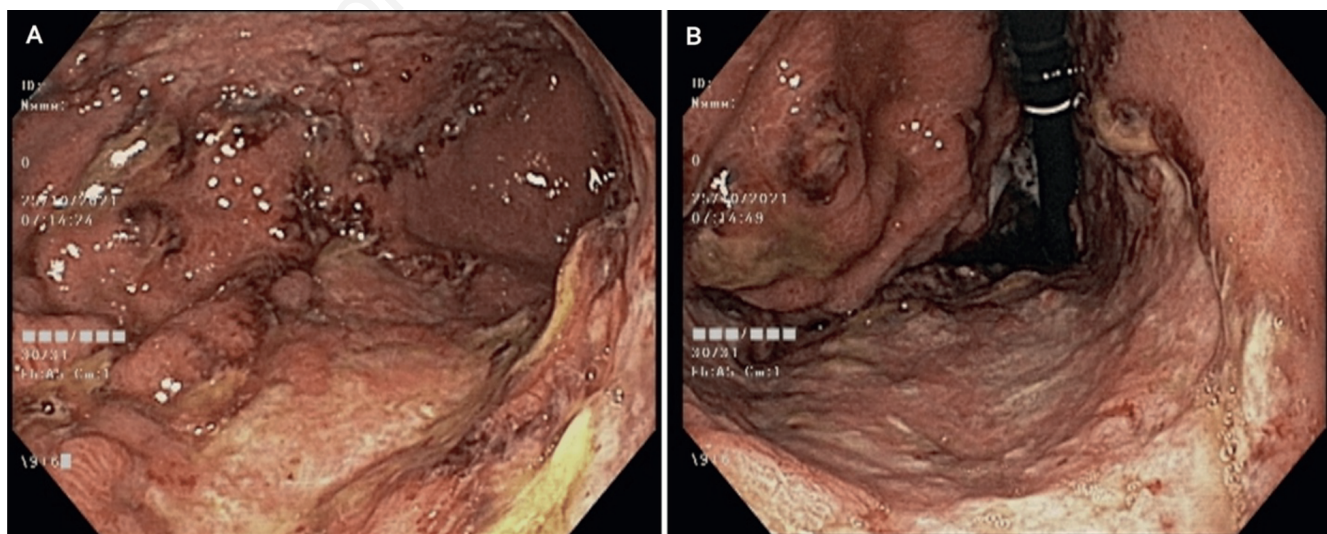
A 35-year-old gentleman with Down's syndrome presented to us with high-grade fever, recurrent vomiting, and delirium for 7 days. After 5 days of these symptoms, he developed rapidly progressive breathlessness along with dry cough and constipation followed by melena. The patient was normotensive with tachypnea, tachycardia, S1Q3T3 pattern on electrocardiogram, and had oxy-hemoglobin saturation (SpO<sub>2</sub>) of 60% on room air. Rapid antigen test and multiple nasal and oropharyngeal swabs for RT-PCR (reverse transcriptase polymerase chain reaction) for SARS-CoV-2 were negative. Blood investigations were normal except for neutrophilic leukocytosis.

Computed tomographic (CT) pulmonary angiography (Figure 1 A,B) revealed pulmonary thromboembolism involving the left main pulmonary artery and its branches with bilateral ground glass opacities and interlobular septal thickening. Because of clinic-radiological picture of pneumonia bronchoalveolar lavage (BAL) was done which revealed neutrophil-predominant lavage fluid. The patient was initiated on broad-spectrum antibiotics and high-flow nasal oxygen (HFNO) therapy. Aerobic culture and stains for fungus and mycobacterium on BAL fluid were all negative. CT abdomen angiography showed ulcers in the distal body of the stomach with a heterogeneous enhancement of the mucosa. Upper gastrointestinal (upper GI) endoscopy was performed which showed multiple necrotic black ulcers in the body of the stomach and sloughing of the mucosa (Figure 2 A,B). Histopathological examination of the biopsy from the gastric mucosal lesion showed broad, aseptate to pauciseptate, ribbon-like, and foldable fungal hyphae in the epithelium, along with focal

ulceration with exudate and invasive fungal profiles, morphologically conforming to mucormycosis. The patient was at high risk of surgical complications due to extensive involvement and recent pulmonary embolism, hence was initiated on liposomal amphotericin B. Low molecular weight heparin was started after control of gastrointestinal bleed. The patient tolerated the treatment well and no adverse reactions against amphotericin were observed. Oxygen requirement also decreased and the patient was shifted to nasal prongs and subsequently on room air. After 10 days of amphotericin therapy patient developed confused behavior with paraparesis and left upper limb weakness. Contrast-enhanced CT brain showed multiple ring-enhancing lesions and the clinic-radiological picture was suggestive of cerebral mucormycosis. Treatment was supplemented with a short course of mannitol. Neurological deficit improved over the next 10 days. After 28 days of amphotericin B therapy, the patient was initiated on oral posaconazole and discharged on room air. Because



**Figure 1.** CT pulmonary angiography images. A) Axial image showing pulmonary thromboembolism in left pulmonary artery and its branches. B) Lung window showing bilateral ground glass opacities with interlobular septal thickening.



**Figure 2.** Endoscopic images showing diffuse deep ulceration with sloughing of the gastric mucosa. A) Forward view examination. B) Retroflexed view examination.

of simultaneous presentation with mucormycosis and pulmonary embolism, testing for IgM against SARS-CoV-2 was done and found to be positive, suggestive of a recently acquired infection [6]. The patient is presently on oral posaconazole and completely asymptomatic at 6 months of follow-up. Upper GI endoscopy at 6 months has shown complete resolution of all lesions.

## Discussion

We present a case of concurrent gastric and cerebral mucormycosis along with pulmonary embolism in a physically active and immunocompetent patient with Down's syndrome with successful remission on intravenous and oral anti-fungal therapy. The patient had an unusual presentation with delayed presentation of cerebral involvement while on treatment and without rhino-orbital disease. Although there are few case reports of disseminated mucormycosis with successful response to therapy, the presence of concurrent pulmonary embolism and gastrointestinal bleeding in this patient made this case particularly difficult to manage.

Mucorales enter the body as spores usually through ingestion, inhalation, or inoculation of spores into open wounds from where based on the host factors they are either eradicated or germinate and produce infection. Gastric mucormycosis primarily results from the ingestion of spores. An outbreak of gastric mucormycosis was reported in a Spanish hospital due to contamination of wooden tongue depressors and crushers used to prepare medicines for patients in the intensive care unit [7]. Once the infection is established, dissemination occurs due to angio-invasion, thrombosis, and subsequent embolization of the thrombus. Disseminated mucormycosis is most commonly reported to involve the lungs and brain where the lungs are considered the primary site of entry [8]. In the present case, the patient likely acquired gastric infection first with secondary dissemination to the brain.

Identification of mucormycosis is a challenge as there is no reliable serological test and the diagnosis only depends on the demonstration of fungal hyphae in tissue or isolation of fungal hyphae *via* culture or polymerase chain reaction. Culturing the tissue is a slow and cumbersome method with low sensitivity as fungal hyphae get crushed in tissue preparation and yield a positive culture in only 50% of the cases. The gold standard of diagnosis is microscopic visualization of fungal morphology on histopathological specimens with or without tissue infiltration, vasculitis, tissue infarction, and inflammatory exudation. Polymerase chain reaction for diagnosis has shown high sensitivity and specificity and may soon become commonplace [9]. CT of the abdomen has non-specific signs such as ulceration, mucosal thickening, or intramural mass lesion. Endoscopy usually reveals variably sized and numbered mucosal ulceration with green to black exudates with or without necrosis of the tissue [10]. Imaging of paranasal sinuses and brain shows mucosal thickening of sinuses, soft tissue density in paranasal sinuses extending into orbit and brain, brain abscess, ring-enhancing lesions, infarcts, and cavernous sinus thrombosis [11].

Most cases of primary gastric or disseminated mucormycosis have been reported in immunocompromised, polytrauma, burn patients, diabetics, or those with hematological malignancies. Among immunocompetent individuals, most cases reported have localized disease involving skin/ subcutaneous tissue in trauma and burn patients with disseminated disease in few [12]. Surgery is another major cause of disseminated mucormycosis in immunocompetent adults with possible contamination in the peri- or post-operative period [13]. Once diagnosed, treatment should be initiated at the earliest possible. Multiple agents have been tried - amphotericin B, Azole antifungals (posaconazole, voriconazole),

echinocandins, iron chelators, and hyperbaric oxygen therapy with variable success. Surgery, whenever feasible, remains a cornerstone in the management of mucormycosis due to local vasculitis and a large amount of necrotic debris which interferes with the activity and penetration of antifungal agents [1].

## Conclusions

Our patient represents a unique case with disseminated mucormycosis in absence of any apparent risk factor. Infection with SARS-CoV-2 has been reported to be associated with mucormycosis and prothrombotic states. The presence of IgM and/or IgG against SARS-CoV-2 is representative of past infection or immunization. As the patient did not have a history of immunization with the COVID-19 vaccine, his disease was likely associated with COVID-19. The findings of this case report demonstrate two important points: first, the significance of a recent COVID-19 infection in causing thromboembolic disease and disseminated mucormycosis; and second, successful treatment of disseminated mucormycosis with medical therapy alone.

## References

1. Spellberg B, Edwards Jr J, Ibrahim A. Novel perspectives on mucormycosis: pathophysiology, presentation, and management. *Clin Microbiol Rev* 2005;18:556-69.
2. Roden MM, Zaoutis TE, Buchanan WL, et al. Epidemiology and outcome of zygomycosis: A Review of 929 reported cases. *Clin Infect Dis* 2005;1:634-53.
3. Raut A, Huy NT. Rising incidence of mucormycosis in patients with COVID-19: another challenge for India amidst the second wave? *Lancet Respir Med* 2021;9:e77.
4. Singh AK, Singh R, Joshi SR, Misra A. Mucormycosis in COVID-19: a systematic review of cases reported worldwide and in India. *Diabetes Metab Syndr* 2021;15:102146.
5. Tan BK, Mainbourg S, Friggeri A, et al. Arterial and venous thromboembolism in COVID-19: a study-level meta-analysis. *Thorax* 2021;76:970-9.
6. Jacofsky D, Jacofsky EM, Jacofsky M. Understanding antibody testing for COVID-19. *J Arthroplasty* 2020;35:S74-S81.
7. Maravi-Poma E, Rodríguez-Tudela JL, de Jalón JG, et al. Outbreak of gastric mucormycosis associated with the use of wooden tongue depressors in critically ill patients. *Intensive Care Med* 2004;30:724-8.
8. Pak J, Tucci VT, Vincent AL, et al. Mucormycosis in immunochallenged patients. *J Emerg Trauma Shock* 2008;1:106-13.
9. Skiada A, Lass-Floerl C, Klimko N, et al. Challenges in the diagnosis and treatment of mucormycosis. *Med Mycol* 2018;56:93-101.
10. Naqvi HA, Nadeem Yousaf M, Chaudhary FS, Mills L. Gastric mucormycosis: An infection of fungal invasion into the gastric mucosa in immunocompromised patients. *Case Rep Gastrointest Med* 2020;16:8876125.
11. Chikley A, Ben-Ami R, Kontoyiannis DP. Mucormycosis of the central nervous system. *J Fungi* 2019;8:59.
12. Mignogna MD, Fortuna G, Leuci S, et al. Mucormycosis in immunocompetent patients: a case-series of patients with maxillary sinus involvement and a critical review of the literature. *Int J Infect Dis* 2011;15:533-40.
13. Nain PS, Matta H, Singh K, et al. Post-operative abdominal wall mucormycosis - a case series. *Indian J Surg* 2015;77:S253-6.