

Spontaneous large volume hemothorax managed with a small-bore chest tube

Moiz Salahuddin, Samia Ayub

Department of Medicine, Aga Khan University, Karachi, Pakistan

Abstract

A 67-year-old male with metastatic lung cancer presented with acute shortness of breath and increasing oxygen require-

ments. He had a decreasing hemoglobin for which he required red blood cell transfusions. His chest x-ray showed near complete white-out of the left lung. Bedside ultrasound (Handheld Sonostar C4PL) showed a large pleural effusion with swirling echogenic material suggestive of plankton sign. The pleural effusion was aspirated and showed frank blood, after which a small-bore chest tube (SBCT) was inserted. A total of 3200 mL of blood was drained with the SBCT. There was complete clearance of the pleural space, and no further blood product transfusions were needed. This case highlights that conservative management can be considered in patients with spontaneous hemothorax due to metastatic disease.

Correspondence: Moiz Salahuddin, Department of Medicine, Aga Khan University, Stadium Road, PO Box 3500, Karachi 74800, Pakistan.
Tel. +92.302.8026665.
E-mail: moiz_salahuddin@hotmail.com

Key words: hemothorax; lung cancer; small-bore chest tube; pleural effusion.

Contributions: MS, concepts, design, definition of intellectual content, literature search, data acquisition, manuscript preparation, manuscript editing, manuscript review, guarantor; SA, concepts, design, literature search, data acquisition, manuscript preparation, manuscript editing, manuscript review. All the authors read and approved the final version of the manuscript and agreed to be accountable for all aspects of the work.

Availability of data and material: all data underlying the findings are fully available.

Conflict of interest: the authors have no conflict of interest in this study.

Ethics approval and patient consent: no ethical committee approval was required for this case report by the Department, because this article does not contain any studies with human participants or animals. Informed consent was obtained from the patient included in this study.

Consent for publication: the patient gave his written consent to use his personal data for the publication of this case report and any accompanying images. All information regarding the patient has been de-identified.

Received: 28 November 2022.

Accepted: 25 January 2023.

Early view: 2 February 2023.

Publisher's note: all claims expressed in this article are solely those of the authors and do not necessarily represent those of their affiliated organizations, or those of the publisher, the editors and the reviewers. Any product that may be evaluated in this article or claim that may be made by its manufacturer is not guaranteed or endorsed by the publisher.

©Copyright: the Author(s), 2023

Licensee PAGEPress, Italy

Monaldi Archives for Chest Disease 2023; 93:2496

doi: 10.4081/monaldi.2023.2496

This article is distributed under the terms of the Creative Commons Attribution-NonCommercial International License (CC BY-NC 4.0) which permits any noncommercial use, distribution, and reproduction in any medium, provided the original author(s) and source are credited.

Introduction

Spontaneous hemothorax occurs without any traumatic event or procedure that led to blood accumulation in the pleural space [1]. Spontaneous hemothoraces may occur due to coagulopathies or malignancies involving the pleura [1]. Hemothorax is defined by a pleural fluid hematocrit to serum hematocrit ratio greater than 50% [1,2]. For traumatic hemothoraces, large bore chest tubes should be placed, and surgical management may be indicated. However, spontaneous hemothoraces have different pathophysiology, and thus different management strategies may be considered. We present a case of a spontaneous hemothorax that was managed with a different strategy.

Case Report

A 67-year-old male presents to the Emergency Room with complaints of shortness of breath. He reports progressively increasing shortness of breath on exertion for the last 1 week. He has a past medical history of metastatic lung adenocarcinoma for which he is currently receiving erlotinib.

On examination, he is in mild respiratory distress. He is on 5 liters nasal cannula with an oxygen saturation of 92%. His heart rate is 123 bpm, respiratory rate of 25, blood pressure of 125/80 and a temperature of 37.3 C. On initial lab testing, his hemoglobin is 9.3 gm/dL, white blood cell count of $15.3 \times 10^9/L$ and platelets of $144 \times 10^9/L$. His prothrombin time was 14.9 seconds, partial thromboplastin time is 27.8 seconds with an International Normalized Ratio of 1.4.

His chest x-ray (CXR) (Figure 1) showed a large left pleural effusion. Bedside ultrasound (Handheld Sonostar C4PL) showed a large volume pleural effusion (Figure 2) with multiple echogenic swirling densities that were floating in the pleural fluid at high speed. This was consistent with 'plankton sign' which can represent a hemothorax. Given these findings, a small-bore chest tube (SBCT) - 10 French pigtail catheter with Seldinger technique under

ultrasound guidance was placed. On initial aspiration, the fluid was bloody – appearing like a venous blood sample.

The SBCT was connected to a pleuro-evac drainage system at

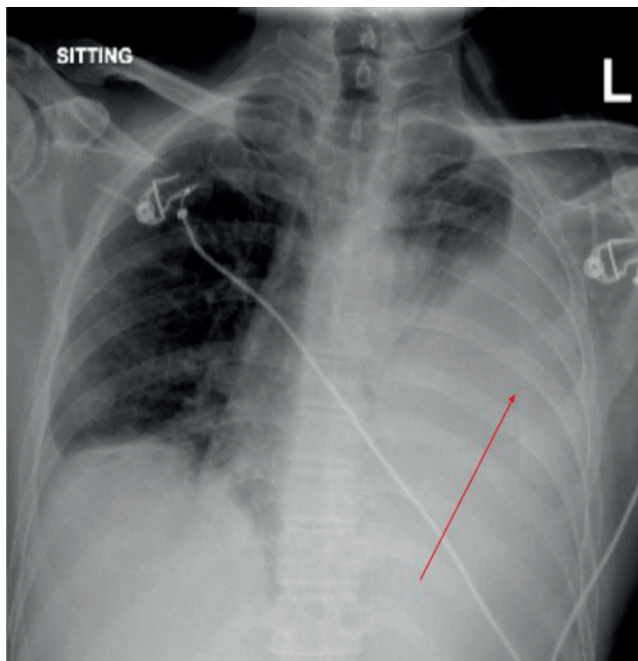


Figure 1. Initial chest x-ray showing a large left pleural effusion.

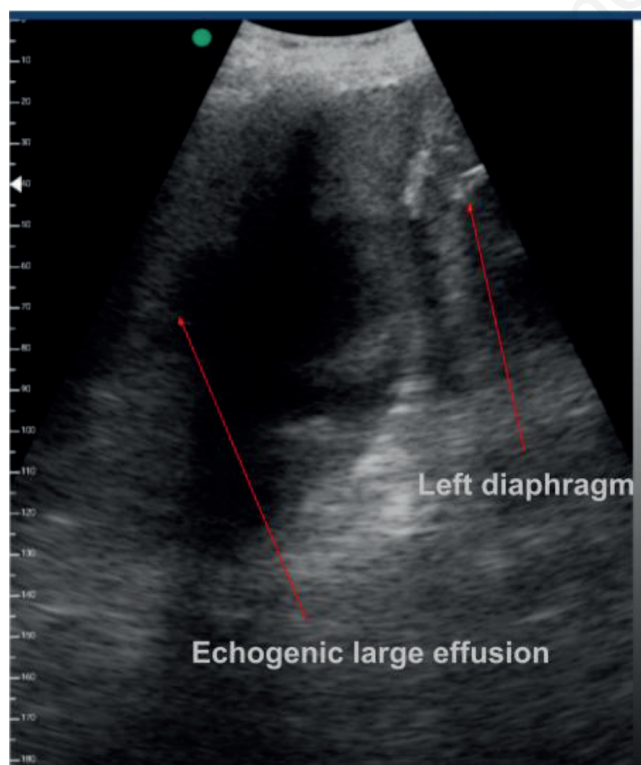


Figure 2. Thoracic ultrasound showing echogenic material floating in the pleural space - consistent with plankton sign.

-20 cm H₂O suction. In the first 24 h, 2000 mL was drained of bloody pleural fluid, and after 48 h the total fluid drained was 3200 mL. On pleural fluid analysis, the pleural fluid hematocrit to serum hematocrit ratio was 88, consistent with a hemothorax.

After 48 h, the pleural fluid drainage decreased to 100 mL/day. His hemoglobin initially dropped to 6.7 gm/dL and he was given 2 units packed red blood cells, after which he remained stable around 10 gm/dL with no further decline. After 48 h of the SBCT insertion, his oxygen requirements were weaned off to room air from 5 liters, his heart rate improved to 90 bpm, and his tachypnea resolved. His CXR 48 h after pigtail insertion (Figure 3) showed significantly improved effusion with lung expansion. He was stable and discharged home with the SBCT in place. One week later his pleural fluid color had significantly improved to a serosanguinous color.

Discussion

We describe a case of a spontaneous hemothorax in a patient with metastatic lung cancer, which was successfully managed with a SBCT. Our patient likely had a spontaneous hemothorax from tumor seeding on the pleural surface which can erode and cause venous bleeding into the pleural space. This is usually a slow accumulation but can lead to a large collection over days, and a slow drop of 1-2 gm/dL of hemoglobin in 24 h.

Malignancy associated spontaneous hemothorax is rare, but the often-reported tumors are sarcomas, neurofibromas, renal carcinoma, hepatocellular carcinoma [3-5]. Our case represents a spontaneous hemothorax due to lung cancer. There are limited reports of spontaneous hemothorax caused by lung cancer.

In our case, we placed a SBCT that was a 10 French pigtail. The tube did not clog throughout the drainage process and did not require flushing. It is important to note that draining 3.2 liters of bloody fluid does not necessarily indicate continuous bleeding. Rather this is most likely old blood that had been slowly oozing

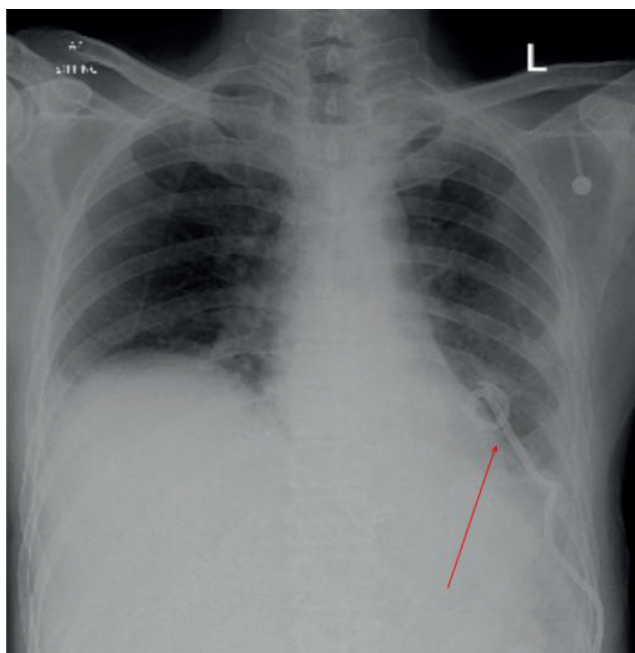


Figure 3. Chest x-ray 48 h after chest tube insertion.

from the pleural surface over many days that led to 3 liters of blood collecting in the pleural space. One prior report showed success with a 16 French indwelling pleural catheter draining a spontaneous hemothoraces [2]. It is important that if a SBCT pigtail is placed for a complicated effusion or hemothorax, it should be directed by ultrasound into the largest collection, to be able to drain the dependent fluid successfully.

Ultrasound chest findings can help guide interventions in such cases. In our patient, ultrasound findings showed swirling echogenic material (plankton sign) at high speed in the pleural cavity. This finding represents highly proteinaceous material such as protein or blood in the pleural space, which can suggest a hemothorax. The ultrasound chest can help prepare the pulmonologist for necessary planning such as placing a chest tube instead of doing a thoracentesis [6,7]. This strategy would also confirm that this is not a traumatic hemothorax due to a thoracic procedure, but rather this was a spontaneous hemothorax present prior to any interventions.

Patients with metastatic disease to the pleura may have limited survival of a few months [8]. These patients may have limited respiratory reserve, high oxygen requirements, poor nutritional status and are immunocompromised. For these patients, undergoing video-assisted thoracostomy (VATS) may add to morbidity, and increased length of hospital stay. Such patients with metastatic disease are at higher risk for general anesthesia, and a non-intubated VATS may provide a solution without increased morbidity.

We recommend that for patients with spontaneous hemothorax who have a short life-expectancy; a SBCT may provide palliation and sufficient drainage of the pleural space. If the bleeding volume remains high after 2-3 days and there is a continued need for blood transfusion, then VATS should be considered.

Conclusions

Spontaneous hemothoraces can occur due to malignancy or coagulopathies. Ultrasound chest findings can guide the physician

towards the underlying pathologies. An echogenic swirling pleural effusion represents a highly proteinaceous pleural effusion which could be due to malignancy or hemothorax. Spontaneous hemothoraces can be sufficiently managed with small bore chest-tubes, especially in patients with malignant spontaneous hemothorax.

References

1. Azfar Ali H, Lippmann M, Mundathaje U, Khaleeq G. Spontaneous hemothorax: a comprehensive review. *Chest* 2008; 134:1056-65.
2. Morgan CK, Bashoura L, Balachandran D, Faiz SA. Spontaneous hemothorax. *Ann Am Thorac Soc* 2015;12: 1578-82.
3. Yen CW, Hsu LS, Chen CW, Lin WH. Hepatocellular carcinoma with thoracic metastases presenting as hemothorax: A case report and literature review. *Medicine (Baltimore)* 2018; 97:e10945.
4. Campione A, Forte G, Luzzi L, et al. Pulmonary angiosarcoma presenting as spontaneous recurrent hemothorax. *Asian Cardiovasc Thorac Ann* 2009;17:84-5.
5. Chetcuti K, Barnard J, Loggos S, et al. Massive hemothorax secondary to metastatic renal carcinoma. *Ann Thorac Surg* 2010;89: 2014-6.
6. Svigals PZ, Chopra A, Ravenel JG, et al. The accuracy of pleural ultrasonography in diagnosing complicated parapneumonic pleural effusions. *Thorax* 2017;72:94-5.
7. Chung MH, Hsiao CY, Nian NS, et al. The Benefit of ultrasound in deciding between tube thoracostomy and observative management in hemothorax resulting from blunt chest trauma. *World J Surg* 2018;42:2054-60.
8. Clive AO, Kahan BC, Hooper CE, et al. Predicting survival in malignant pleural effusion: development and validation of the LENT prognostic score. *Thorax* 2014;69:1098-104.