

# A study of subcutaneous emphysema, factors contributing to its development, resolution and management with different modalities

Mukesh Goyal,<sup>1</sup> Jose K. Jimmy,<sup>2</sup> Ramakant Dixit,<sup>1</sup> Deepak Kumar Garg<sup>3</sup>

<sup>1</sup>Department of Respiratory Medicine, Jawaharlal Nehru Medical College, Ajmer; <sup>2</sup>Department of Critical Care Medicine, Mar Sleeva Medicity Palai, Cherpunkal; <sup>3</sup>Department of Anesthesia, Jawaharlal Nehru Medical College, Ajmer, India

Correspondence: Ramakant Dixit, Department of Respiratory Medicine, JLN Medical College, Ajmer 305001, Rajasthan, India.  
Tel.: +91 9413040257.  
E-mail: dr.ramakantdixit@gmail.com

Key words: subcutaneous emphysema, intercostal chest tube drainage, pneumothorax.

Contributions: JKJ, data acquisition, analysis and interpretation, and manuscript drafting; MG, study concept and design, manuscript drafting and critical revision for important intellectual content; RD, study concept and design, data acquisition, analysis and interpretation and manuscript drafting, and critical revision for important intellectual content; DKG, study concept and design. All the authors have read and approved the final version of the manuscript and agreed to be accountable for all aspects of the work.

Conflict of interest: the authors declare that they have no competing interests, and all authors confirm accuracy.

Ethics approval and consent to participate: the study was approved by the Institutional Ethics Committee. The committee assessed the planned project as ethically unobjectionable.

Informed consent: written informed consent to participate was obtained from all study participants.

Patient consent for publication: not applicable.

Funding: none.

Availability of data and materials: the datasets used and/or analyzed during the current study are available from the corresponding author upon reasonable request.

Received: 15 March 2023.

Accepted: 6 June 2023.

Early view: 26 June 2023.

Publisher's note: all claims expressed in this article are solely those of the authors and do not necessarily represent those of their affiliated organizations, or those of the publisher, the editors and the reviewers. Any product that may be evaluated in this article or claim that may be made by its manufacturer is not guaranteed or endorsed by the publisher.

©Copyright: the Author(s), 2023

Licensee PAGEPress, Italy

Monaldi Archives for Chest Disease 2024; 94:2583

doi: 10.4081/monaldi.2023.2583

This article is distributed under the terms of the Creative Commons Attribution-NonCommercial International License (CC BY-NC 4.0) which permits any noncommercial use, distribution, and reproduction in any medium, provided the original author(s) and source are credited.

## Abstract

Subcutaneous emphysema (SE) is defined as an escape of air in subcutaneous tissue. It is one of the most common complications after intercostal chest tube drainage. SE is usually benign, requiring no specific treatment, but extensive SE can be uncomfortable and alarming for the patient. It can rarely lead to airway compromise, respiratory failure, and death. Factors leading to its development, following chest tube insertion and methods of management, have not been extensively studied and published. This was an analytical study done over 2 years on indoor patients who developed SE. These cases were managed using four different modalities and were analyzed for various factors contributing to the development, severity, and resolution of SE. The results of this study highlight that the cases of hydropneumothorax and secondary pneumothorax were significantly more predisposed to the development of severe SE (following intercostal chest tube insertion) and large air leaks as compared to others. A larger air leak develops higher grades of SE. The average time for resolution of SE was similar among the different modalities of management compared in the study.

## Introduction

Subcutaneous emphysema (SE) refers to gas in the subcutaneous tissues. It is a common condition occurring after a chest injury. It occurs after blunt or penetrating trauma to the laryngeal, tracheal, or bronchial tree. Injury to sinus cavities, facial bones, barotrauma, and bowel perforation are some common causes [1]. Iatrogenic cases may occur due to tube thoracostomy, tracheal intubation, malfunction or disruption of the ventilator circuit, inappropriate closure of the pop-off valve, the Valsalva maneuver that increases thoracic pressure, and trauma to the airway. Infrequently, SE and pneumo-mediastinum have been reported spontaneously in tubercular cavities, silicosis cavitating malignancies, sarcoidosis, and infections such as COVID-19 [2-4]. SE is characterized by swelling of tissues under the skin, commonly seen over the chest wall, neck, and face, around drain or wound sites, but may be found at any place in the body. Chest pain, sore throat, dysphagia, neck pain, breathlessness, and wheezing may be found. SE appears as a radiolucent area over soft tissues on a radiograph. Sometimes, striations are noticed in a pattern due to gas outlining the fibers of the pectoralis major muscle group, called the 'ginkgo leaf sign' of the chest. Air trapped in subcutaneous tissue appears as dark spots on computed tomography (CT) scans and is easier to see than on the skiagram [5].

SE is usually a benign, self-limiting condition and is managed conservatively [4], but extensive cases are disfiguring, uncomfortable, and alarming for the patient, and they can rarely be associated

with airway compromise, respiratory failure, and death, especially in those with tension pneumothorax or pneumomediastinum [5]. Massive accumulation of air in deeper tissue spaces at the level of the thoracic outlet has the capability of compressing the trachea and great vessels, thereby severely compromising the airway, venous return, and blood flow to the head and neck [6].

Various approaches have been described for the management of SE like the use of subcutaneous incisions, needles, and drains. In severe cases, catheters can be placed in subcutaneous tissue to release air. Small cuts, or “blow holes,” may also be made in the skin [7]. When SE occurs due to pneumothorax, an intercostal chest tube (ICT) is frequently used, which controls and eliminates the source of air entering the subcutaneous space. If the volume of air increases and ICT cannot remove air completely, then the tube should be replaced by a larger one. Suction may also be applied at ICT to remove air faster [8]. Since treatment usually involves dealing with an underlying condition, cases of spontaneous SE may require nothing more than bed rest, control of pain, and supplemental oxygen. Breathing oxygen helps the body absorb the subcutaneous air more quickly [9]. Reassurance and observation are also part of treatment in the mild form of SE.

Factors leading to the development of SE following ICT and various methods for its management have not been studied thoroughly to date. So, this study attempted to explore different aspects of the development and management of SE.

## Materials and Methods

This was an analytical study conducted among the patients admitted to the Department of Respiratory Medicine, Jawaharlal Nehru Medical College, Ajmer, over the last 2 years who developed SE.

This study aimed to compare various methods used for the management of surgical emphysema and to identify and analyze various underlying factors contributing to its severity and resolution.

The convenience sampling method was used with a sample size of 68 subjects. The diagnosis of SE was made by the detection of thoracic, cervical, and abdominal crepitus on physical examination and the presence of subcutaneous air detected by chest X-rays and/or thoracic CT among patients presented in the Department of Respiratory Medicine of our institute. Administrative restrictions (a separate wing, distinct from the respiratory department, for COVID-19 and post-COVID-19 patients) prevented including cases from those wings/departments in the study. The grading of SE was done, as proposed by Aghajanzadeh *et al.* [10], into five categories depending on the extent and area of distribution. Grade 1 was SE at the base of the neck; grade 2 was in all of the neck area; grade 3 was in the subpectoralis major area; grade 4 was in the chest wall and all of the neck area; grade 5 was in the chest wall, neck, orbit, scalp, abdominal wall, upper and lower limbs, and scrotum.

Subjects with grade 1 SE were considered mild SE, subjects with grades 2 and 3 were considered moderate, and subjects with grades 4 and 5 were considered severe SE.

All patients were assessed by detailed clinical history and examination for resolution of SE, an air leak in ICT, and complications, if any. The air leak was graded using the classification proposed by Sang *et al.* into grade 0 (no air bubble on three serial volitional coughs), grade 1 (more than one air bubble present on three serial volitional coughs), grade 2 (persistent air bubbles on volitional coughs), grade 3 (persistent, small amount of air bubbles on spontaneous respiration), and grade 4 (persistent large amount of air bubbles on spontaneous respiration) [11]. Digital anemometers can pre-

cisely quantify the air leak but were not used in the study due to financial and administrative constraints.

The patients were managed by the following four methods: i) conservative management by continuous inhalation of high-concentration oxygen; ii) management by blow-hole skin incisions; iii) management by insertion of a subcutaneous drain connected to the vacuum system; iv) management by insertion of a second ICT.

Patients requiring surgical treatment of underlying pulmonary pathology were not included in the study due to the non-availability of a thoracic surgeon at our institute. Patients were given continuous, high-concentration oxygen inhalation through a non-re-breathing mask or a Venturi mask. A blow hole skin incision was made deep into the external thoracic fascia; thereafter, compressive massage was done towards the site of the incision to aid drainage. Subcutaneous drainage was done by inserting an 18 Fr Ryles tube in the subcutaneous space in the anterior chest wall. After making a skin incision just above the nipple, a tract was created by blunt dissection with hemostat forceps; a subcutaneous tube was inserted in this tract and connected to a negative pressure apparatus. The second ICT was usually inserted one or two intercostal spaces below or above the first ICT within the “safe triangle” for ICT placement, although depending upon the locule, it may be inserted more posteriorly or anteriorly in the second intercostal space midclavicular line, as per the British Thoracic Society guidelines [12]. Both ICTs were connected to an underwater seal system separately. Written informed consent was obtained from all the subjects. The subjects also received medical management for underlying pulmonary disease, apart from pleurodesis, when indicated.

Statistical analysis was done using Epi Info (CDC, Atlanta, GA, USA) version 7.2.1.0 software. Categorical variables were expressed as frequency and percentage and were analyzed using a chi-square test. Continuous variables were expressed as mean and standard deviation and were analyzed using an independent sample *t*-test for comparison between two groups and a one-way analysis of variance test for comparison between more than two groups. A *p* value of less than 0.05 was taken as significant.

## Results

A total of 68 patients who developed SE within the age range of 22 to 77 years participated in this study. The mean age of the subjects was 51.27±15.7 years; males (n=60, 88.2%) outnumbered females (n=8, 11). The majority were underweight (n=42, 61.8%); 25 cases (36.8%) had a normal body mass index, and one case was overweight. The majority were current smokers (45.5%), 17.6% were ex-smokers, and 25% were non-smokers. The most frequent pulmonary co-morbidity was pulmonary tuberculosis, constituting 27 cases (39.7%), followed by chronic obstructive pulmonary disease [21 cases (30.9%)], carcinoma lung [6 cases (8.8%)], occupational lung disease [3 cases (4.4%)], bronchial asthma [2 cases (2.9%)], and interstitial lung disease [1 case (1.5%)]. It was observed that patients with pulmonary co-morbidities had a higher grade (4 and 5) of SE (n=46, 80.7%) as compared to patients with no pulmonary co-morbidities (n=4, 36.36%). Patients with no co-morbidity were more likely to develop moderate SE (n=7, 63.6%).

The majority of subjects (n=63, 92.6%) developed SE following ICT insertion, whereas five cases (7.3%) developed spontaneous SE. In subjects developing SE following ICT insertion, most had secondary pneumothorax (n=30, 44.1%) as the underlying condition. This was followed by 24 cases (35.3%) of hydropneumothorax, 7 cases (8.8%) of pleural effusion, and 2 cases (2.9%) of primary pneumothorax. Among the cases of (hydro)pneumothorax, 48 cases

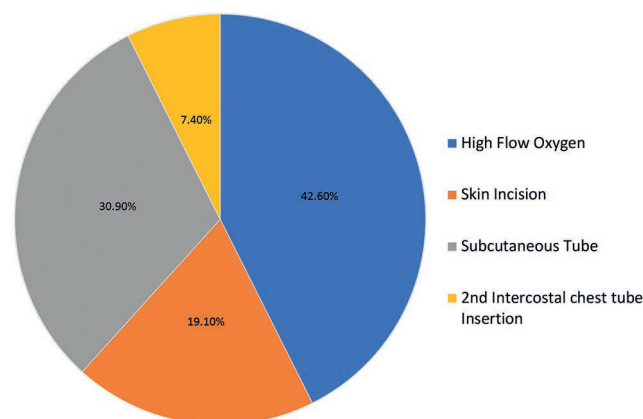
(85.7%) had large and 8 cases (14.2%) had small pneumothorax.

Grade 5 SE was seen in 29 cases (42.6%); 18 cases (26.5%) had grade 4; 19 cases (27.9%) had grade 3; and 2 cases (2.9%) had grade 2 SE.

The subjects with underlying lung disease [(hydro)pneumothorax or pleural effusion] developed severe SE significantly more than the subjects with spontaneous SE, who had a greater chance of developing moderate SE (Table 1). Larger air leaks of grade  $\geq 2$  (in ICT) were significantly more common in cases of secondary pneumothorax and hydropneumothorax as compared to other cases (Table 2) [chi-square: 21.437 with degrees of freedom: 9, (p=0.011)].

A significant correlation between the grade of air leak (in ICT) and the grade of SE was observed, with higher chances of developing severe SE in higher grades of air leak (grade 2 or more). Among the 29 subjects who had grade 5 SE, 67.9% had air leaks of grade  $\geq 3$ , and the rest of 32.1% had air leaks of grade 2 (Table 3).

Out of the total study subjects, 42.6% (n=29) were managed by high-flow oxygen inhalation followed by subcutaneous tube insertion in 21 cases (30.9%), skin incision in 13 cases (19.1%) and second ICT in 5 cases (7.4%) (Figure 1).



**Figure 1.** Distribution of study subjects according to the modality of management.

**Table 1.** Relation between grade of subcutaneous emphysema and the underlying condition.

Underlying condition	Grades of subcutaneous emphysema initially							
	Grade 2		Grade 3		Grade 4		Grade 5	
	n	%	n	%	n	%	n	%
Primary pneumothorax	0	0	1	5.3	1	5.6	0	0.0
Secondary pneumothorax	1	50	8	42.1	9	50.0	12	41.4
Hydropneumothorax	1	50	2	10.5	5	27.8	16	55.2
Pleural effusion	0	0	4	21.1	3	16.7	0	0.0
Spontaneous subcutaneous emphysema	0	0	4	21.1	0	0.0	1	3.4
<b>Total</b>	<b>2</b>	<b>100</b>	<b>19</b>	<b>100</b>	<b>18</b>	<b>100</b>	<b>29</b>	<b>100</b>

Chi-square=21.821 with 12 degrees of freedom; (p=0.040, significant).

**Table 2.** Relation between underlying disease and grade of air leak.

Underlying disease	Grade of air leak								Total
	Grade 0		Grade 1		Grade 2		Grade $\geq 3$		
	n	%	n	%	n	%	n	%	
Primary pneumothorax	0	0.0	0	0.0	2	100.0	0	0.0	2
Secondary pneumothorax	0	0.0	1	3.3	19	63.3	10	33.3	30
Hydropneumothorax	0	0.0	1	4.2	11	45.8	12	50.0	24
Pleural effusion	1	14.2	2	28.5	3	42.8	1	14.2	7

Chi-square=21.437 with 9 degrees of freedom; (p=0.011, significant).

**Table 3.** Relation between grade of surgical emphysema and grade of air leak.

Grade of air leak	Grades of subcutaneous emphysema initially							
	Grade 2		Grade 3		Grade 4		Grade 5	
	n	%	n	%	n	%	n	%
Grade 0	0	0	1	6.7	0	0.0	0	0.0
Grade 1	0	0	3	20.0	1	5.6	0	0.0
Grade 2	1	50	10	66.7	15	83.3	9	32.1
Grade 3 and more	1	50	1	6.7	2	11.1	19	67.9
<b>Total</b>	<b>2</b>	<b>100</b>	<b>15</b>	<b>100</b>	<b>18</b>	<b>100</b>	<b>28</b>	<b>100</b>

Chi-square=24.372 with 6 degrees of freedom (p<0.001, significant).



The average time taken for the resolution of SE was  $6.75 \pm 2.61$  days,  $7.07 \pm 2.25$  days,  $7.61 \pm 2.76$  days, and  $5.60 \pm 3.64$  days, respectively, in cases of SE managed by high-flow oxygen, skin incision, subcutaneous tube, and insertion of a second ICT (Table 4). There was no significant difference in the time of resolution of SE among the different methods used ( $p=0.440$ ), but the mean time taken for resolution of SE increased with the increase in the grade of air leak, a statistically significant finding with  $p=0.019$ . The mean duration of resolution was  $5.60 \pm 2.70$  days in grade 0,  $4.50 \pm 1.29$  days in grade 1,  $6.71 \pm 2.06$  days in grade 2, and  $8.12 \pm 3.16$  days in cases of air leak of grade  $\geq 3$  (Table 4).

## Discussion

Severe SE is associated with co-morbidities and probably has a higher mortality. Apart from the distressing cosmetic deformity, SE can lead to upper airway obstruction, acute respiratory failure, and circulatory collapse due to tension in the pneumo-mediastinum or pacemaker malfunction. It can also lead to difficult interpretation of chest radiographs, echocardiography, ultrasound, and electrocardiograms. This study has identified several important factors associated with SE and its management.

Patients with pulmonary co-morbidities had a higher grade of SE compared to patients with no pulmonary co-morbidities. There are several individual reports of the occurrence of spontaneous SE in patients with underlying tuberculosis, silicosis, lung cancer, *etc.*, with multiple mechanisms. Dixit *et al.* described a case of acute silicosis complicating as spontaneous pneumomediastinum, bilateral pneumothorax, and SE in a 35-year-old male engaged in a stone crusher unit [13]. Dixit and George described a case of SE in cavitary pulmonary tuberculosis without pneumothorax or pneumo-mediastinum [14]. Das *et al.* described a case of a 5-year-old girl with miliary tuberculosis complicated by pneumo-mediastinum and SE [15].

We observed that cases who had a large pneumothorax (even after chest tube insertion) developed SE, an observation consistent with the study by Jones *et al.* [16], where 167 patients were studied, and SE was associated more with cases of moderate or large pneumothorax.

Severe SE developed more in cases of hydropneumothorax, and secondary pneumothorax as compared to pleural effusion and primary pneumothorax, when managed with ICT drainage. This may

be due to larger, longer air leaks in an underlying damaged lung. We observed that hydropneumothorax and secondary pneumothorax cases had a larger air leak (grade  $>3$ ) than other cases. A large air leak (grade  $\geq 3$ ) results in a higher percentage of patients with grade 5 SE.

The average time taken for the resolution of SE was different for the different methods of management used in this study, but there was no significant difference among them. However, it was observed that the insertion of a second chest tube resulted in the fastest resolution of SE.

In our study, the mean time for resolution of SE on subcutaneous tube insertion was  $7.61 \pm 2.76$  days. There are different reports showing different resolution times. Lloyd *et al.* reported two cases of life-threatening SE with blunt traumatic pneumothorax, managed by fenestrated 28-F catheters inserted subcutaneously and connected to suction [17]. Both patients experienced dramatic relief in one hour. Beck *et al.* described a case report of inserting a bilateral fenestrated 14-gauge angio-catheter subcutaneously in a patient with severe SE which resolved by day 3 [18]. Kelly *et al.* described a case of severe SE in a patient with bilateral pneumothorax [19]. They managed SE with a 28-F subcutaneous catheter and showed rapid resolution in one day. Leo *et al.* reviewed 12 patients who developed SE requiring microdrainage [20]. Fenestrated angio-catheters aided by compressive massage (3 to 4 times daily) were used. In 11 of the 12 cases, SE resolved within 3 days. Cesario *et al.* reviewed 21 cases of post-lung resection SE [21], where they used Penrose-type rubber drains subcutaneously through supraclavicular incisions for a mean of 3.5 days, aided by compressive massage. Sherif and Ott described a case where they used a Jackson-Pratt drain, a closed suction drain with a bulb reservoir to provide decompression of the head and neck area in 3 hours, and the drain was removed on day 7 without complications [22].

Management methods for SE and its influencing factors have been studied to date. Only case reports, series, and review articles are available in the literature. This is one of the first-ever studies done on cases of SE that developed following chest tube drainage and comparing various modalities used in its management. It highlights the significant differences between the pulmonary conditions and grade of air leak following chest tube insertion, the grade of air leak with the severity of SE, and the time taken for its resolution. Despite these strengths, the study has a few limitations: small sample size, lack of availability of a thoracic surgeon, non-inclusion of COVID-19 pneumonia and post-COVID-19 patients due to administrative restrictions, lack of randomization and a control group (so the chances of selection bias cannot be ruled out). More studies need to be done in the future with a larger sample size, proper randomization, and preferably with a control group.

**Table 4.** Comparison of time of resolution of subcutaneous emphysema among various management methods and grade of air leak.

Management method	Time of resolution mean (days $\pm$ SD)	p value
Grade of air leak		
High flow oxygen	$6.75 \pm 2.61$	0.440 (NS)
Grade 0	$5.60 \pm 5.60$	
Skin incision	$7.07 \pm 2.25$	
Grade 1	$4.50 \pm 1.29$	
Subcutaneous tube	$7.61 \pm 2.76$	
Grade 2	$6.71 \pm 2.06$	
Second ICT	$5.60 \pm 3.64$	0.019 (S)
Grade 3 and more	$8.12 \pm 3.16$	

ICT, intercostal drain; SD, standard deviation; S, significant; NS, not significant.

## Conclusions

SE is typically regarded as a benign, self-limiting condition that only requires conservative management. Interventional modalities are useful in severe cases of patient discomfort and respiratory distress. The four techniques described in this study have been shown to provide effective relief from severe SE with no significant difference in time resolution between different methods. A significant observed finding of the study is that pulmonary conditions like hydropneumothorax and secondary pneumothorax were found to develop a higher grade of SE and a higher grade of air leak following chest tube insertion. A larger air leak was found to be causing a higher grade of SE with a longer time for its resolution. So, cases of higher grades of SE associated with pulmonary co-morbidities should be

managed promptly, with the choice of method depending on the availability, relevance, and expertise of the treating physician. This is a novel study, the first of its kind, highlighting important aspects of intercostal tube drainage and associated SE.

## References

1. Maunder RJ, Pierson DJ, Hudson LD. Subcutaneous and mediastinal emphysema. Pathophysiology, diagnosis, and management. *Arch Intern Med* 1984;144:1447-53.
2. Agrawal A, Sen KK, Satapathy G, et al. Spontaneous pneumomediastinum, pneumothorax and subcutaneous emphysema in COVID-19 patients—a case series. *Egypt J Radiol Nucl Med* 2021;52:27.
3. Raykar PS, Banur A, Mahanthappa G, et al. J. Characteristics and outcome of pneumothorax, pneumomediastinum, and subcutaneous emphysema in COVID-19 patients: a case series. *J Assoc Chest Physicians* 2023;11:28-35.
4. Macklin MT, Macklin CC. Malignant interstitial emphysema of the lungs and mediastinum as an important occult complication in many respiratory diseases and other conditions. *Medicine (Baltimore)* 1944;23:281-358.
5. Chan L, Reilly KM, Henderson C, et al. Complication rates of tube thoracostomy. *Am J Emerg Med* 1997;15:368-70.
6. Fidrocki DM, Greenbaum NR, Diaz GC. Severe pneumomediastinum and subcutaneous emphysema subsequent to prolonged mechanical ventilation. *IDCases* 2021;24:e01090.
7. Johnson CH, Lang SA, Bilal H, Rammohan KS. In patients with extensive subcutaneous emphysema, which technique achieves maximal clinical resolution: infraclavicular incisions, subcutaneous drain insertion or suction on in situ chest drain?. *Interact Cardiovasc Thorac Surg* 2014;18:825-9.
8. Ruan G, Edquist C, Pagali S. Extensive subcutaneous emphysema: a complication of traumatic pneumothorax. *JAAPA* 2021;34:52-4.
9. Ali RK, Kakamad FH, Hama Ali Abdalla S, et al. Management of post lobectomy subcutaneous emphysema: a case report with literature review. *Ann Med Surg (Lond)* 2021;69:102610.
10. Aghajanzadeh M, Dehnadi A, Ebrahimi H, et al. Classification and management of subcutaneous emphysema: a 10-year experience. *Indian J Surg* 2015;77:673-7.
11. Oh SG, Jung Y, Jheon S, et al. Postoperative air leak grading is useful to predict prolonged air leak after pulmonary lobectomy. *J Cardiothorac Surg*. 2017;12:1.
12. Laws D, Neville E, Duffy J. BTS guidelines for the insertion of a chest drain. *Thorax* 2003;58:ii53-9.
13. Dixit R, Meena M, Patil CB. Pneumomediastinum, bilateral pneumothorax and subcutaneous emphysema complicating acute silicosis. *Int J Occup Med Environ Health* 2015;28:635-8.
14. Dixit R, George J. Subcutaneous emphysema in cavitary pulmonary tuberculosis without pneumothorax or pneumomediastinum. *Lung India* 2012;29:70-2.
15. Das M, Chandra U, Natchu M et al. Pneumomediastinum and subcutaneous emphysema in acute miliary tuberculosis. *Indian J Pediatr* 2004;71:553-4.
16. Jones PM, Hewer RD, Wolfenden HD, Thomas PS. Subcutaneous emphysema associated with chest tube drainage. *Respirology* 2001;6:87-9.
17. Lloyd MS, Jankowski MP. Treatment of life-threatening surgical emphysema with liposuction. *Plast Reconstr Surg* 2009;123:77e-8e.
18. Beck PL, Heitman SJ, Mody CH. Simple construction of a subcutaneous catheter for treatment of severe subcutaneous emphysema. *Chest* 2002;121:647-9.
19. Kelly MC, McGuigan JA, Allen RW. Relief of tension subcutaneous emphysema using a large bore subcutaneous drain. *Anaesthesia* 1995;50:1077-9.
20. Chari M R, Leo S, Priya A R. Simple micro drainage system for palliation of severe subcutaneous emphysema. *Trop Doct* 2022;52:408-10.
21. Cesario A, Margaritora S, Porziella V, Granone P. Microdrainage via open technique in severe subcutaneous emphysema. *Chest* 2003;123:2161-2.
22. Sherif HM, Ott DA. The use of subcutaneous drains to manage subcutaneous emphysema. *Tex Heart Inst J* 1999;26:129-31.