

# Tracheal atypical solitary carcinoid in a so-called “difficult asthma”: a diagnostic challenge

Martina Turrin,<sup>1</sup> Francesca Maria Pontoriero,<sup>2</sup> Giulia Grisostomi,<sup>2</sup> Giordano Fiorentù,<sup>2</sup> Francesca Zampieri,<sup>1</sup> Francesca Savoia,<sup>1</sup> Cosimo Catino,<sup>1</sup> Giuseppe Zanardi,<sup>1</sup> Piera Peditto,<sup>1</sup> Nicola Malacchini,<sup>1</sup> Fabiola Zeraj,<sup>1</sup> Matteo Bonato,<sup>1</sup> Diana Sacchi,<sup>1</sup> Maria Guido,<sup>3</sup> Giovanni Morana,<sup>4</sup> Micaela Romagnoli<sup>1</sup>

<sup>1</sup>Pulmonology Unit, Ca' Foncello Hospital, Azienda Unità Locale Socio-Sanitaria 2 Marca Trevigiana, Treviso; <sup>2</sup>Department of Cardiac, Thoracic, Vascular Science and Public Health, University of Padua; <sup>3</sup>Histology and Pathological Anatomy Unit, Ca' Foncello Hospital, Azienda Unità Locale Socio-Sanitaria 2 Marca Trevigiana, Treviso; <sup>4</sup>Radiology Unit, Ca' Foncello Hospital, Azienda Unità Locale Socio-Sanitaria 2 Marca Trevigiana, Treviso, Italy

Correspondence: Francesca Maria Pontoriero, Department of Cardiac, Thoracic, Vascular Science and Public Health, University of Padua, Italy.

Tel.: +39.0422.322729.

E-mail: fra.pontoriero@gmail.com

Key words: interventional pulmonology, chronic cough, tracheal obstruction, NETs.

Contributions: MT, FMP, GF, GG, MR, conception of the study design, drafting and revision of the manuscript; FZ, FS, CC, GZ, PP, NM, FZe, MB, DS, MG, acquisition and analysis of data, clinic evaluation and clinical management of the patient. All authors have read and agreed to the published version of the manuscript.

Conflict of interest: the authors declare no potential conflict of interest.

Ethics approval and consent to participate: no Ethical Committee approval was required for this case report by the Department. This article does not contain any studies with human participants or animals.

Patient consent for publication: the patient gave her written consent to use her personal data for the publication of this case report and any accompanying images.

Funding: none.

Availability of data and materials: all data used to support our findings are fully available.

Received: 27 March 2023.

Accepted: 23 July 2023.

Early view: 2 August 2023.

Publisher's note: all claims expressed in this article are solely those of the authors and do not necessarily represent those of their affiliated organizations, or those of the publisher, the editors and the reviewers. Any product that may be evaluated in this article or claim that may be made by its manufacturer is not guaranteed or endorsed by the publisher.

©Copyright: the Author(s), 2023

Licensee PAGEPress, Italy

Monaldi Archives for Chest Disease 2024; 94:2586

doi: 10.4081/monaldi.2023.2586

This article is distributed under the terms of the Creative Commons Attribution-NonCommercial International License (CC BY-NC 4.0) which permits any noncommercial use, distribution, and reproduction in any medium, provided the original author(s) and source are credited.

## Abstract

This report describes the case of a 46-year-old non-smoker housewife. She presented to our attention with a diagnosis of “difficult asthma” from another center in the previous two years. She had no allergies and had not been exposed to an excessive amount of noxious stimuli. Her chronic respiratory symptoms (dyspnea on exertion with wheezing) remained uncontrolled despite maximal anti-asthmatic inhaled therapy. A high-resolution computed tomography scan was performed to further investigate other pulmonary diseases that mimic asthma. It revealed a pedunculated endotracheal lesion with regular borders that obstructed 90% of the tracheal lumen. The lesion was removed *via* rigid bronchoscopy with laser endobronchial; histological examination revealed the presence of an atypical carcinoid. Atypical carcinoids are a rare subtype of neuroendocrine lung tumor that accounts for 2% of all thoracic malignancies. They frequently arise from the central airways and cause obstructive symptoms such as coughing, wheezing, chest pain, or recurrent obstructing pneumonia, which is caused by central airway obstruction. Clinical onset is gradual and characterized by non-specific symptoms, which frequently result in misdiagnosis. As a result, in a young patient with progressive dyspnea, chronic cough, and wheezing that is not responding to anti-asthmatic treatment, second-level investigations are required and may lead to a definite diagnosis, allowing the appropriate course of treatment to begin.

## Introduction

Endotracheal lesions are frequently misdiagnosed because symptoms are frequently confused with chronic cough or asthma [1]. Pulmonary carcinoids are rare tumors with age-adjusted incidence rates ranging from 0.2 to 2/100,000 population/year in both the United States and Europe. For the past 30 years, the prevalence has increased by 6% per year, regardless of confounding demographic factors such as age, gender, race, and stage distribution. This increase in pulmonary carcinoids over time is most likely due to increased awareness [2]. Primary tracheal tumors can develop from the trachea's respiratory epithelium, salivary glands, and mesenchymal structures. In adults, 90% of primary tumors are malignant, compared to 10-30% in children. Squamous-cell carcinoma and adenoid cystic carcinoma occur in roughly equal numbers and account for roughly two-thirds of adult primary tracheal tumors. The remaining third is widely distributed among a diverse group of malignant or benign tumors [3].

## Case Report

A 46-year-old Caucasian, non-smoker, female housewife with a past medical history of obesity (body mass index 31.2 kg/m<sup>2</sup>), hypertension, and dyslipidemia was referred to our outpatient third-level clinic from a peripheric center because of non-controlled asthma (difficult asthma) despite the maximum inhalation therapy. Two years prior, she started complaining of a dry cough occurring mostly at night, followed by exertional dyspnea. For those symptoms, she was admitted multiple times to her local emergency room. She was discharged with the diagnosis of bronchial asthma exacerbations and treated with multiple courses of oral and inhaled corticosteroids.

After two years of progressive worsening of her symptoms, she was referred to our outpatient clinic. Her first thoracic physical examination was negative in an outpatient setting. The first-level exams revealed: a normal white blood cell count, normal eosinophil count, C-reactive protein (white blood cells 8.96 10<sup>3</sup>/microL, polymerase chain reaction 0.29 mg/dL, and blood eosinophils 0.00 10<sup>3</sup>/microL), chest X-ray, and pulmonary function tests were also within the normal range. She underwent an allergology examination with skin tests that were positive for dust allergens. To investigate other alternative diagnoses that could justify the patient's persistent symptoms, a high-resolution chest computed tomography (CT) scan was performed. It showed a polypoid lesion of 20×15 mm almost totally occluding the lumen of the middle third trachea (Figure 1); no lymphadenomegaly was present, and no parenchymal lesions or abnormalities were reported. When the patient was admitted to our hospital, we performed a flexible bronchoscopy, confirming the presence of a pedunculated lesion occluding 80-90% of the tracheal lumen, partially adherent to the right lateral wall of the trachea.

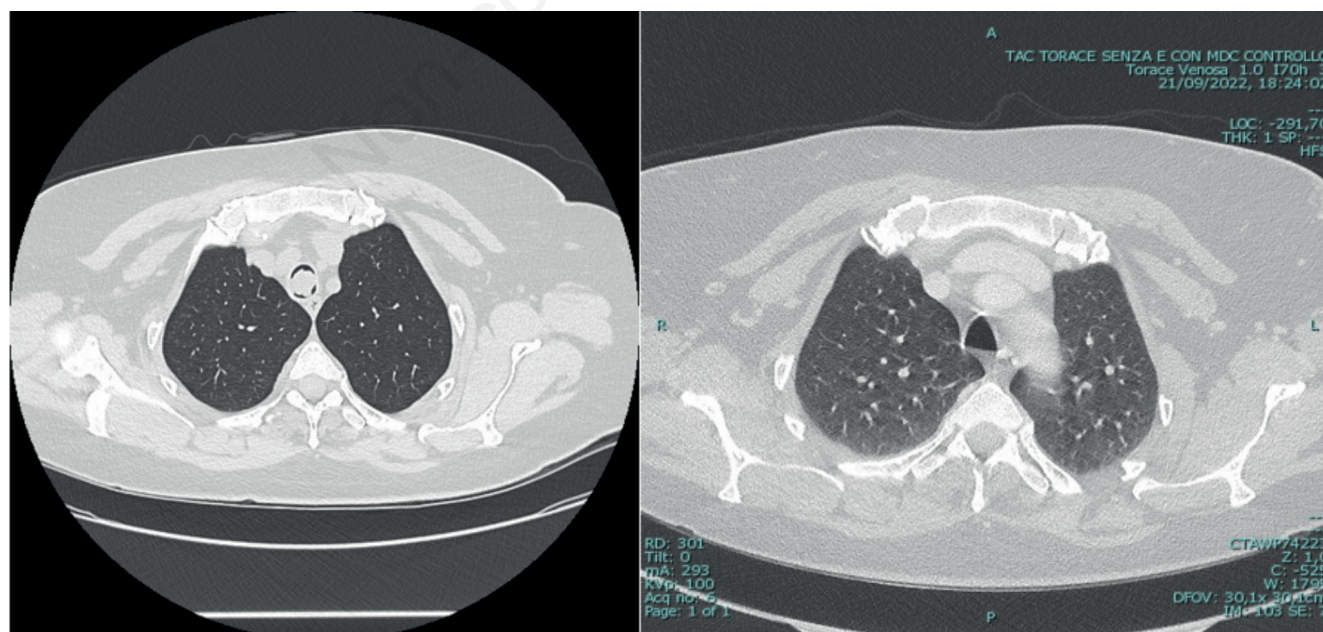
The next day, a rigid bronchoscopy was performed for endobronchial laser resection of the lesion, which allowed for complete removal of the tumor and restoration of normal tracheal lumen

patency. The histological analysis showed the diagnosis of atypical carcinoids (3 mitosis/2 mm<sup>2</sup>; Ki67 8%; immunophenotype: CKAE1/AE3 +, CK7 -/+, *TTF1* -/+, sinaptofisina+, chromogranin A+, CD56+). To exclude the presence of distant metastasis and to confirm the local complete removal of the whole lesion, a neck-chest CT scan and a positron emission tomography (PET) with gallium contrast medium were performed, revealing no uptake in the trachea or any other systemic lesions. A flexible inspection bronchoscopy was performed a month later, which revealed the remnant of a small portion of the peduncle in the right lateral wall of the trachea (Figure 2). The patient, who is no longer experiencing dyspnea, coughing, or chest pain, was referred to a thoracic surgeon for further evaluation. Based on the relative risk of atypical carcinoids, they concluded that surgical tracheal revision was required to avoid recurrence.

## Discussion

This case report underlines the importance of a correct diagnosis approach and shows the indication of interventional pulmonology in the therapeutic management of airway carcinoids. Consequently, this present case highlights the difficult diagnostic challenge of a patient presented with a long-standing cough diagnosed as “difficult asthma” not improved by inhalation therapy and emphasizes the importance of second-level investigations (*e.g.*, CT and PET scan and bronchoscopy) to further evaluate persistent symptoms non-responsive to conventional therapy.

Dyspnea and cough are common non-specific symptoms seen in outpatient settings and hospital emergency rooms; they can be caused by a variety of underlying conditions and organ systems. Their differential diagnosis is broad, encompassing both common diseases such as bronchial asthma and gastroesophageal reflux disease, as well as potentially fatal conditions such as pulmonary embolism, pneumothorax, or acute respiratory failure [4,5].



**Figure 1.** Comparison of chest computed tomography scan before (left) and after (right) endoscopic removal: on the left image endo-tracheal mass is appreciated, in the right image the tracheal normal patency is restored.

Frequently, the correct diagnosis is a diagnostic challenge. As a result, to begin the proper course of treatment, both first-level investigations (e.g., functional and blood tests, blood gas analysis, chest X-ray, electrocardiogram, etc.) and second-level investigations (e.g., chest CT and PET scan) must be performed [6].

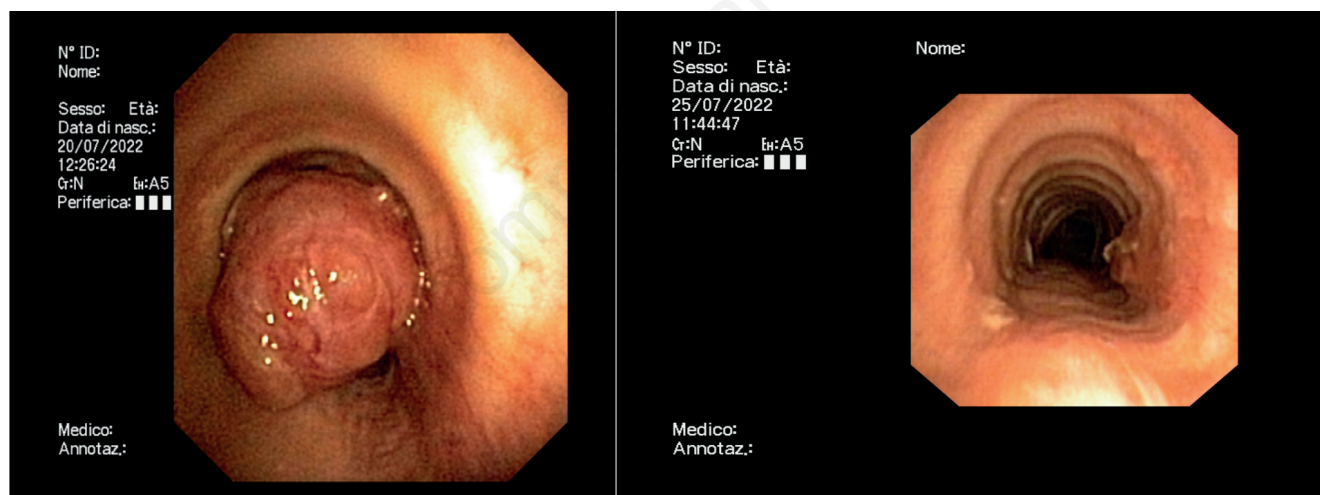
Even after starting a targeted treatment, it is critical not to underestimate the potential of various diagnoses that necessitate further investigation. As a result, the chest high-resolution CT scan revealed the presence of a single atypical carcinoid of the trachea, a rare type of endobronchial malignancy. Neuroendocrine lung neoplasms are a rare subtype of primary lung cancer characterized by neuroendocrine cells that account for 20% of all adult lung malignancies. Neuroendocrine tumors (NETs) make up 2% (with a typical to atypical ratio of 10:1) [7].

The World Health Organization 2022 classification of lung epithelial neuroendocrine neoplasms and poorly differentiated neuroendocrine carcinomas (NECs) is based on the number of mitoses, necrotic features, and Ki67 expression [8]. NETs are further classified into three types. The first is typical (grade 1), with fewer than two mitoses per 2 mm<sup>2</sup> and no evidence of necrosis. The second type is atypical (grade 2), with 2 to 10 mitoses per 2 mm<sup>2</sup> and necrotic characteristics. The third and final type of NET is one with an elevated mitotic count and/or a high Ki67 proliferation index. The latter has an atypical carcinoid morphology, more than 10 mitoses per 2 mm<sup>2</sup>, and a Ki67 percentage greater than 30% [8]. Furthermore, NECs are classified into two subtypes:

small cell lung carcinoma, which has more than 10 mitoses per mm<sup>2</sup>, frequently necrosis, and a small cytomorphology, and large cell NECs, which have more than 10 mitoses per mm<sup>2</sup>, always necrosis, and a large cytomorphology [8]. In our case, histological analysis revealed the presence of atypical NETs with 3 mitosis/2 mm<sup>2</sup> and a Ki67 of 8% (Table 1).

NETs, in particular atypical carcinoids, arise from central airways and manifest with a broad variety of symptoms, such as dyspnea, cough, chest pain, obstructive pneumonia, or life-threatening conditions, e.g., endobronchial hemorrhages with severe hemoptysis or upper airway obstruction [9]. Based on the persistence of respiratory symptoms, the suspicion of an endobronchial lesion should always arise, and a chest CT scan must be performed for differential diagnosis. In a case showing evidence of a tracheal/bronchial lesion on the CT scan, a bronchoscopy is mandatory for diagnostic/therapeutic purposes, with biopsies for histological characterization [somatostatin receptor (SSTR) analysis]. The endoscopic morphology of the endotracheal lesion in our case was highly suspicious for a NET diagnosis, which was then confirmed by histology. The presence of an atypical carcinoid emphasized the need for an Octreoscan or 68Ga-DOTA-octreotate PET to rule out potential distant spread [10,11].

The surgical approach is determined by tumor size, location, and preoperative biopsy specimen evaluation [12]. Because of the high risk of recurrence, revision of the margins is recommended, especially in atypical carcinoids. When endoscopy cannot be used



**Figure 2.** Comparison of bronchoscopy images before and after endobronchial laser resection: in the left image endo-tracheal mass is appreciated, but in the right image no longer present.

**Table 1.** Major representation of the histological pattern of neuroendocrine tumors according to the European Society for Medical Oncology guidelines.

Terminology	HPF	Differentiation	Grade	Ki67 (%)
NET G1	>2 mitoses/2 mm <sup>2</sup>			
Well-differentiated	Low (no necrosis)	<3		
NET G2	2-10 mitoses/2 mm <sup>2</sup>		Intermediate(necrosis)	3-30
NET G3	>10 mitoses/2 mm <sup>2</sup>		High (necrosis)	>30
NEC small cell type	>10 mitoses/2 mm <sup>2</sup>	Poorly differentiated	High (necrosis)	>30
NEC large cell type	>10 mitoses/2 mm <sup>2</sup>			>30

HPF, high-power field; NEC, neuroendocrine carcinoma; NET, neuroendocrine tumor.

to diagnose or remove the entire endotracheal/endobronchial lesion, definitive surgery may be required [13].

In the case of advanced airway atypical carcinoids, they might benefit from peptide receptor radionuclide therapy, such as Lutetium (177Lu Edotreotide), which has been approved in Europe and the United States for the treatment of unresectable or metastatic, progressive, well-differentiated (G1 and G2), SSTR-positive gastroenteropancreatic NETs [14].

## Conclusions

In conclusion, this case demonstrates how a rare disease like endotracheal atypical carcinoids, which typically present with non-specific respiratory symptoms, can be misdiagnosed as other more common respiratory diseases with completely different treatment approaches. Because the clinical presentation can be life-threatening with acute tracheal/bronchial obstruction or massive airway and pulmonary hemorrhaging, a correct, prompt differential diagnosis is critical. For these reasons, it is critical to listen to the patient's complaints and always conduct second-level investigations for the correct diagnosis to begin the proper course of treatment as soon as possible to improve the outcome.

As demonstrated in this case, interventional pulmonology may be the best treatment option for the radical removal of these lesions. Over the last few decades, bronchoscopy has evolved. It has been used by respiratory physicians to diagnose and treat a variety of airway and lung diseases, such as endobronchial or endotracheal lesions. As previously mentioned, atypical carcinoids arise from the central airways and may cause central airway obstruction, which is classified as endobronchial obstruction, extrinsic compression, or a mixed pattern. In the bronchoscopic treatment of these lesions, destruction can be accomplished with several techniques: mechanical debulking with forceps, microdebrider, or tools such as laser electrocautery, argon plasma coagulation, cryotherapy, or photodynamic therapy. For extrinsic compressions, balloon dilation and/or stenting are used to keep the airways open. For mixed patterns, ablation followed by stenting is often necessary [15]. Our case report emphasizes that the role of bronchoscopy in the diagnostic and treating fields is expanding because it can be performed in a day-hospital setting. As a result, it is less expensive for the healthcare system, and in some cases, endobronchial lesions can be treated with less invasive procedures that have fewer postoperative complications; however, highly trained personnel are required.

## References

1. Boissière L, Patey M, Toubas O, et al. Tracheobronchial involvement of rosai-dorfman disease: case report and review of the literature. *Medicine (Baltimore)* 2016;95:e2821.
2. Caplin ME, Baudin E, Ferolla P, et al. Pulmonary neuroendocrine (carcinoid) tumors: European Neuroendocrine Tumor Society expert consensus and recommendations for best practice for typical and atypical pulmonary carcinoids. *Ann Oncol* 2015; 26:1604-20.
3. Macchiarini P. Primary tracheal tumours. *Lancet Oncol* 2006;7: 83-91.
4. Berliner D, Schneider N, Welte T, Bauersachs J. The differential diagnosis of dyspnea. *Dtsch Arztebl Int* 2016;113:834-45.
5. Koch A, Behr J. Cough and its differential diagnosis. *Dtsch Med Wochenschr* 2018;143:1258-71. [Article in German].
6. Ewert R, Gläser S. Dyspnea. From the concept up to diagnostics. *Internist (Berl)* 2015;56:865-71. [Article in German].
7. Rekhman N. Lung neuroendocrine neoplasms: recent progress and persistent challenges. *Mod Pathol* 2022;35:36-50.
8. Rindi G, Mete O, Uccella S, et al. Overview of the 2022 WHO classification of neuroendocrine neoplasms. *Endocr Pathol* 2022;33:115-54.
9. Melosky B. Advanced typical and atypical carcinoid tumours of the lung: management recommendations. *Curr Oncol* 2018;25: S86-93.
10. Hendifar AE, Marchevsky AM, Tuli R. Neuroendocrine tumors of the lung: current challenges and advances in the diagnosis and management of well-differentiated disease. *J Thorac Oncol* 2017;12:425-36.
11. Wolin EM. Challenges in the diagnosis and management of well-differentiated neuroendocrine tumors of the lung (typical and atypical carcinoid): current status and future considerations. *Oncologist* 2015;20:1123-31.
12. Raz DJ, Nelson RA, Grannis FW, Kim JY. Natural history of typical pulmonary carcinoid tumors: a comparison of nonsurgical and surgical treatment. *Chest* 2015;147:1111-7.
13. Baudin E, Caplin M, Garcia-Carbonero R, et al. Lung and thymic carcinoids: ESMO Clinical Practice Guidelines for diagnosis, treatment and follow-up ☆. *Ann Oncol* 2021;32:439-51. Erratum in: *Ann Oncol* 2021;32:1453-5.
14. Strosberg J, El-Haddad G, Wolin E, et al. Phase 3 trial of 177Lu-dotatate for midgut neuroendocrine tumors. *N Engl J Med* 2017;376:125-35.
15. Batra H, Yarmus L. Indications and complications of rigid bronchoscopy. *Expert Rev Respir Med* 2018;12:509-20.