

DOI: [10.4081/monaldi.2023.2661](https://doi.org/10.4081/monaldi.2023.2661)

**CHARGE syndrome and congenital heart diseases: systematic review of literature**

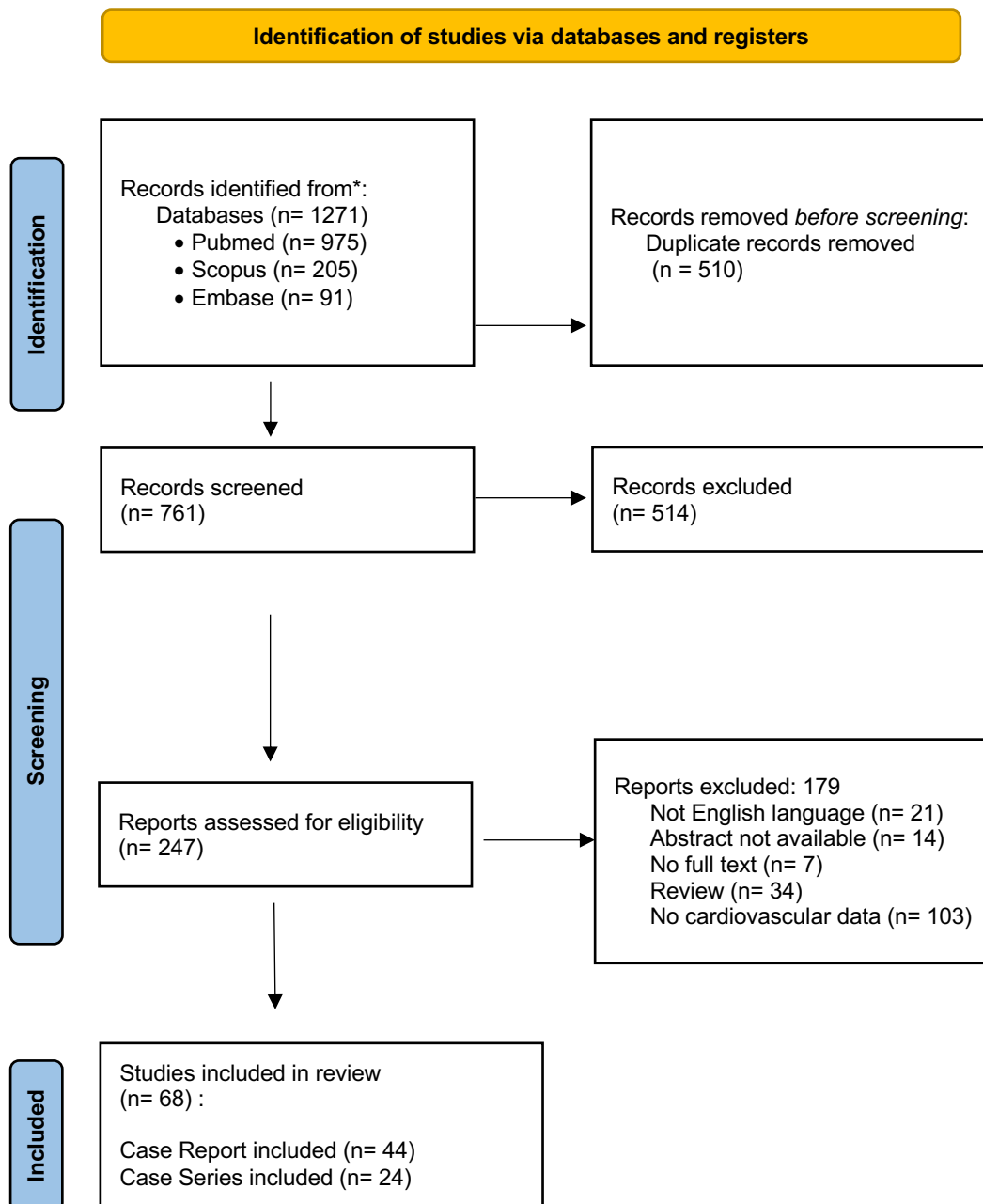
Maria Vincenza Polito,<sup>1</sup> Mario Ferraioli,<sup>2</sup> Alessandra Nocilla,<sup>2</sup> Guido Coppola,<sup>1</sup>  
Federica D'Auria,<sup>1</sup> Antonio Marzano,<sup>1</sup> Luca Barnabei,<sup>1</sup> Marisa Malinconico,<sup>1</sup> Eduardo  
Bossone,<sup>3</sup> Francesco Ferrara<sup>1</sup>

<sup>1</sup>Division of Cardiology, Heart Department, "Cava de' Tirreni and Amalfi Coast" Hospital, University Hospital of Salerno; <sup>2</sup>Department of Medicine, Surgery and Dentistry, University of Salerno, Baronissi (SA); <sup>3</sup>Department of Public Health, Federico II University of Naples, Italy

**Corresponding author:** Francesco Ferrara, Cardiology Division, "Cava de' Tirreni and Amalfi Coast" Hospital, Heart Department, University of Salerno, Via De Marinis, 83023 Cava de' Tirreni (SA), Italy. Fax +39.089.9926241 - Mobile +39.338.6762554. E-mail: [fferrara1975@gmail.com](mailto:fferrara1975@gmail.com)

**Key words:** CHARGE syndrome; persistent fifth aortic arch; congenital heart disease; aortic disease.

---



**Supplementary Figure 1. Flow diagram illustrating study selection process.**

\*Pubmed (aortic disease n = 18; cardiovascular disease n = 594; congenital heart disease n = 363) – duplicate removed n = 307

Scopus (aortic disease n = 19; cardiovascular disease n = 26; congenital heart disease n = 160) – duplicate removed n = 33

Embase (aortic disease n = 19; cardiovascular disease n = 27; congenital heart disease n = 45) – duplicate removed n = 16

**Supplementary Table 1. Distribution of congenital heart diseases (number of cases) described from case series (1981-2020).**

<b>Chestler, 1988</b>
Tetralogy of Fallot 1
ASD 1
VSD 1
PDA 1
Pulmonary stenosis 1
AS 1
Bicuspid aortic valve 1
<b>Corsten-Janssen, 2016</b>
Vascular ring 5
Aberrant subclavian artery 20
Aberrant origin RCA 1
Right AA 20
Truncus bicaroticus 1
Subvalvular AS 2
CoA 5
Tetralogy of Fallot 6
DORV 3
VSD 9
DORV 3
ASD 7
AVSD 3
Pulmonary stenosis 2
IAA 3
Bicuspid aortic valve 2
TAPVR 1
PDA 7
Hypo-LV 1
Truncus arteriosus 1
Absent left AV valve 1
<b>de Lonlay-Debeney, 2015</b>
Tetralogy of Fallot 1
ASD 1
VSD 1
Truncus arteriosus 1
Bicuspid aortic valve 1
Hypo AA 1
<b>Issekutz, 2005</b>

PDA 28  
ASD 18  
VSD 21  
SVC abnormalities 5  
AVSD 7  
AA abnormalities 7  
Conotruncal defects 11

**Larson, 1995**

ASD 3

**Lee, 2009**

PDA 3  
ASD 2  
Pulmonary stenosis 1

**Oley, 1987**

CoA 2  
Tetralogy of Fallot 3  
DORV 1  
VSD 6  
PDA 6  
ASD 4  
Vascular ring 2  
Pulmonary atresia 1  
Ebstein's anomaly 1  
AV canal 2

**Pagon, 1981**

Tetralogy of Fallot 5  
PDA 3  
DORV 2  
AV canal 2  
VSD 1  
ASD + mitral cleft 1  
Right AA + Aberrant left subclavian artery + vascular ring

**Qin, 2020**

ASD 2  
PDA 3  
Right AA 1

**Aramaki, 2006**

AS 1  
CoA 2  
PDA 8  
Hypo-LV 1

VSD 5  
Ebstein's anomaly 1  
ASD 3  
AP-window 1  
Bicuspid aortic valve 1  
IAA 1  
TGA 1

### **Blake, 1990**

Tetralogy of Fallot 4  
Fallot with VSD 4  
Fallot with Ebstein's anomaly 1  
VSD alone 2  
VSD with DORV 1  
VSD with TAPVC 1  
Pulmonary atresia/VSD 2  
DILV with SRAVV and pulmonary stenosis 1  
DORV with pulmonary stenosis and VSD 1  
Pulmonary stenosis with AS 1  
Pulmonary stenosis and secundum ASD 1  
TGA with pulmonary stenosis 1  
VSD and PDA 2  
VSD and secundum ASD 2  
VSD with Ebstein's anomaly 1  
VSD 2  
Secundum ASD and PDA 2  
CoA and PDA 1

### **Corsten-Janssen, 2014**

AS 1  
CoA 2  
Tetralogy of Fallot 22  
DORV 3  
VSD 13  
DORV 3  
ASD 1  
DOLV 1  
Pulmonary stenosis 4  
IAA 4  
TGA 6  
Left isomerism 1  
DIRV/DORV 1  
Pulmonary atresia 1

Truncus arteriosus 1  
Absent left AV valve 1  
Vascular ring with right AA 2  
Aberrant LSA 2  
Aberrant RSA 1  
Hypoplastic pulmonary system 1

**Davenport, 1986**

VSD 3  
DORV 1  
PDA 1  
ASD 1  
Pulmonary stenosis 1

**Husu, 2013**

ASD 8  
Tetralogy of Fallot 2  
PDA 9  
Hypo-LV 1

**Ahn, 1998**

PDA + VSD + ASD  
Pulmonary atresia + VSD + bilateral SVC  
AS + PDA

**Chang, 2013**

VSD + ASD + PDA  
ASD + PDA

**Farquhar, 2002**

PDA 1  
PDA + Aberrant right brachiocephalic artery

**Cheng, 2019**

PDA 6  
ASD 1  
VSD 1  
Bilateral SVC 1  
DORV 1

**Shoji, 2014**

CoA 2  
DORV 3  
VSD 7  
PDA 12  
ASD 6  
Vascular ring 2  
Pulmonary stenosis 2

IAA 2  
TGA 1  
AS 1  
Hypo LV 1  
Endocardial cushion defect 1

**Sohn, 2015**

PDA 11  
ASD 7  
VSD 1  
AS 1

**Stroemland, 2005**

PDA 13  
VSD 3  
Tetralogy of Fallot 1  
DORV 1  
ASD 3  
AVSD 2  
Vascular ring 1

**Tellier, 1998**

Tetralogy of Fallot 4  
Conotruncal malformations 7  
ASD 3  
VSD 5  
PDA 8  
DORV-DOLV 3  
Pulmonary stenosis 4  
AA abnormalities 2

**Wyse, 1993**

Tetralogy of Fallot 8  
Fallot with AVSD 5  
Fallot with Ebstein's anomaly 1  
Pulmonary atresia/VSD 2  
AVSD alone 2  
AVSD with DORV 1  
AVSD with VSD and ASD 1  
AVSD with TAPVC 1  
DORV with TGA and Pulmonary stenosis 1  
DORV with Pulmonary stenosis 1  
Pulmonary stenosis with AS 1  
Pulmonary stenosis and secundum ASD 1  
TGA with Pulmonary stenosis 1

DILV with SRAVV and Pulmonary stenosis 1  
 VSD and PDA 4  
 VSD and secundum ASD 3  
 VSD with Ebstein's anomaly 1  
 VSD 2  
 Secundum ASD and PDA 4  
 CoA and PDA and/or VSD 3  
 PDA 3  
 Aberrant subclavian arteries 7  
 Right AA 5

**Legendre, 2017**

ASD 35  
 VSD 18  
 AVSD 8  
 TOF 9  
 TGA 4  
 DORV 2  
 Hypo LV 1  
 PDA 30  
 Aberrant subclavian artery 6  
 CoA 5  
 Anomalous pulmonary venous drainage 3  
 AA abnormalities 1  
 right AA 2  
 dextrocardia 1

AS, aortic stenosis; CoA, aortic coarctation; PDA, persistent ductus arteriosus; Hypo-LV, hypoplastic left ventricle; VSD, ventricular septal defect; ASD, atrial septal defect; AP, aortopulmonary; IAA, interrupted aortic arch; TGA, transposition of the great arteries; DORV, double outlet right ventricle; TAPVC, total anomalous pulmonary venous connection; DILV, double inlet left ventricle; SRAVV, straddling right atrioventricular valve; DOLV, double outlet left ventricle; DIRV, double inlet right ventricle; AV, atrioventricular; AA, aortic arch; LSA, left subclavian artery; RSA, right subclavian artery; SVC, superior vena cava; RCA, right coronary artery; AVSD, atrioventricular septal defects; TAPVR, total anomalous pulmonary venous return; SVC, superior vena cava; TOF, tetralogy of Fallot.