

Repeated chest wall reconstruction after resection of a sternal chondroid chordoma with long-term postoperative infection of the reconstructive material

Uyen-Thao Le,¹ Jurij Kiefer,² Johannes Zeller,² Ömer Senbaklavaci,³ Filip Simunovic,² Laurin Titze¹

¹Department of Thoracic Surgery, Faculty of Medicine, Medical Center - University of Freiburg, Germany; ²Department of Plastic Surgery, Faculty of Medicine, Medical Center - University of Freiburg, Germany; ³Department of Thoracic Surgery, Faculty of Medicine, Medical Center - University of Bern, Switzerland

Correspondence: Uyen-Thao Le, Department of Thoracic Surgery, Faculty of Medicine, Medical Center - University of Freiburg, Hugstetter Straße 55, 79106 Freiburg, Germany.
Tel. +49 761 270 24710.
Fax: +49 761 270 96 24990.
E-mail: antonia.uyen-thao.le@uniklinik-freiburg.de

Key words: chest wall resection, chest wall reconstruction, extra-axial chondroid chordoma, infection of reconstructive material.

Contributions: all authors have contributed significantly to the content of this article.

Conflict of interest: the authors have no conflicts of interest or financial ties to disclose.

Ethics approval and consent to participate: as this patient's treatment did not include any experimental approach, approval of the local ethics committee was unnecessary.

Patient consent for publication: the patient presented in this case report consented to all procedures and has given written consent to the publication of this article.

Availability of data and material: raw data and materials are available upon reasonable request.

Funding: none.

Conference presentation: this case has been reported as a poster presentation at the 23rd annual chest wall international group congress on June 24, 2023, in Istanbul, Turkey.

Received: 23 July 2023.

Accepted: 4 December 2023.

Early view: 15 December 2023.

Publisher's note: all claims expressed in this article are solely those of the authors and do not necessarily represent those of their affiliated organizations, or those of the publisher, the editors and the reviewers. Any product that may be evaluated in this article or claim that may be made by its manufacturer is not guaranteed or endorsed by the publisher.

©Copyright: the Author(s), 2023

Licensee PAGEPress, Italy

Monaldi Archives for Chest Disease 2024; 94:2728

doi: 10.4081/monaldi.2023.2728

This article is distributed under the terms of the Creative Commons Attribution-NonCommercial International License (CC BY-NC 4.0) which permits any noncommercial use, distribution, and reproduction in any medium, provided the original author(s) and source are credited.

Abstract

We present the case of a 23-year-old man with a chondroid chordoma of the sternum. The patient underwent chest wall resection, followed by stabilization using a sandwich graft of Prolene mesh and methylmethacrylate, covered with bilateral pedicled musculus pectoralis flaps. After adjuvant radiotherapy and 2 years of follow-up, the patient developed a graft-associated infection. We removed the allogeneic material and the encapsulated abscess, and the wound was conditioned through negative wound pressure therapy. This time, wound closure and chest wall stabilization were achieved with a Prolene mesh covered by a free anterolateral thigh flap. This case demonstrates the importance of carefully considering the material for chest wall stabilization and establishing multidisciplinary cooperation.

Introduction

Chest wall reconstruction can be performed in many ways with exclusive soft tissue coverage of the defect or additional implantation of prosthetic material. Choosing the extent of reconstruction and suitable materials is crucial to prevent complications such as postoperative infection, chest wall deformation, or chronic pain [1]. Complex chest wall reconstruction and management of postoperative complications require a multidisciplinary setting.

Case Report

A 23-year-old man presented to our hospital for thoracic pain and a 2×3 cm parasternal lump in the right fifth intercostal space. Computed tomography (CT) showed a paracardial hypodense 10×10×8 cm tumor, extending into the middle lobe and through the chest wall into the musculus pectoralis major (Figure 1).

Incision biopsy revealed a chondroid chordoma. CT of the abdomen and magnetic resonance imaging scan of the cervical spine showed no distant metastasis, and our interdisciplinary tumor conference recommended tumor resection.

Intraoperative thoracoscopy showed a capsulated 12 cm tumor, which adhered to the lung. The internal mammary artery was cut cranially, and a transverse sternotomy was performed in the upper and lower third of the sternum to access the tumor. Parts of the third to fifth ribs on the right side and the fourth and fifth on the left side were resected. After pleurolysis, the mass was detached from the right lower lung (Figure 2). Frozen section analysis confirmed com-

plete tumor resection. Two chest tubes were inserted (Figure 3). As was the usual method in our department at that time, the chest wall defect was reconstructed with a sandwich graft made from Prolene mesh and methylmethacrylate. The Prolene mesh was covered with bilateral pedicled pectoralis major flaps. On the right side, the flap was raised as a myocutaneous pectoralis major island flap, but since there was no skin defect, the epidermis was de-epithelized, and the dermis was used to cover the mesh. The left-sided pectoralis major muscle was raised as a muscle flap and advanced contralaterally towards the de-epithelized skin island of the right-sided flap. To aid

advancement, the humeral insertion of the muscle was divided on the left side. Tension-free closure of both pectoralis flaps and complete coverage over the mesh was achieved. Redon drains were inserted subcutaneously, and the skin closed.

The patient received antibiotic prophylaxis with ampicillin/sulbactam for 7 days, and the postoperative course was uneventful. Because of narrow safety margins, our interdisciplinary tumor conference recommended adjuvant radiation therapy with a total dose of 60 Gy, applied in 5 weekly sessions with fractions of 2 Gy each for 6 weeks.

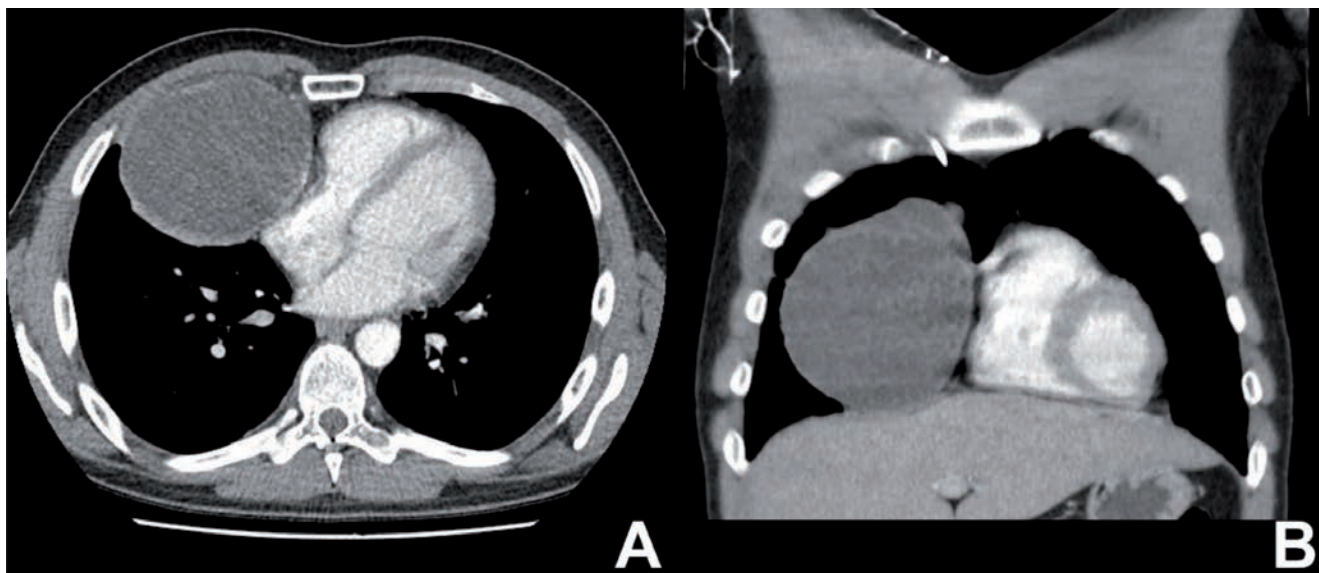


Figure 1. The preoperative computed tomography scan shows the right paracardial hypodense tumor in the axial (A) and coronal (B) plane.

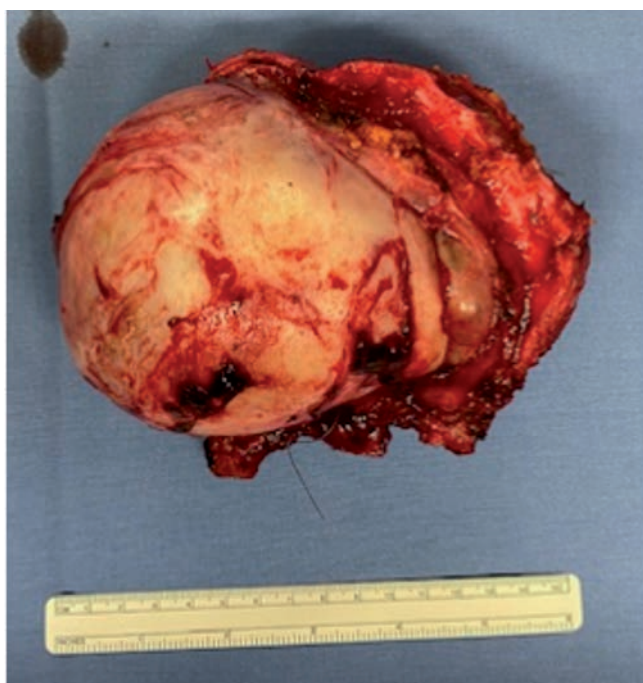

Figure 2. The tumor was resected completely (R0).

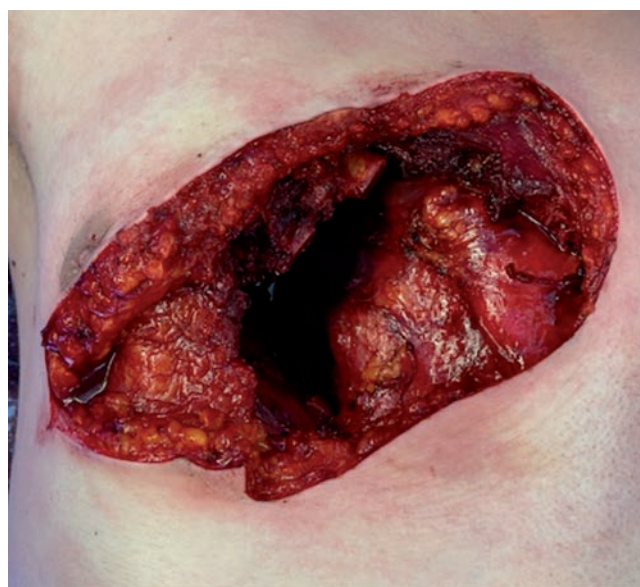


Figure 3. The operative site after resection of the tumor. The osseous defect was then reconstructed with a sandwich graft made from Prolene mesh and methylmethacrylate. The alloplastic material was covered with a right-sided myocutaneous pectoralis major island flap and a left-sided pectoralis major advancement flap.

On follow-up 9 months after surgery, imaging showed no signs of recurrence, but the patient complained of chest wall pain. Physical examination showed healed wounds. However, we noticed a marked hypesthesia over the right ventral thorax and a discreet friction between the Prolene mesh and the cranial part of the sternum, possibly contributing to the pain. Thorax was stable, and the patient showed neither paradoxical breathing nor dyspnea. Thus, the patient was referred to a pain specialist.

Two years later, the patient presented to our outpatient clinic with increased chest and upper back pain and reddening of the chest, which occurred mainly in the evenings. In retrospect, the symptoms had been present since the end of the radiotherapy. Physical examination showed no signs of chest wall instability or skin infection. Notably, the discreet friction between the Prolene mesh and the cranial part of the sternum was still persistent. Blood tests did not show elevated inflammatory markers. The CT scan showed air pockets and fluid collection around the Prolene mesh and methylmethacrylate graft, which led to the suspicion of local graft infection although there were no signs of a systemic infection.

Revision surgery confirmed the clinical suspicion (Figure 4). Microbacterial probes detected *Streptococcus mitis/oralis* and *Gemella* species. Debridement of the wound and negative pressure wound therapy were performed. The foam dressing was changed three times over a period of 10 days. Antibiotic treatment with ampicillin/sulbactam was administered throughout the perioperative course until 10 days after secondary wound closure. The final operation was performed in an interdisciplinary setting with a team of thoracic and plastic surgeons.

To minimize the risk of another graft infection, the chest wall was only stabilized with a duplicated Prolene mesh, stretched tautly, and attached to the ribs and sternum with non-absorbable 2-0 Mersilene suture (Figure 5). The soft tissue defect was covered with a free myocutaneous anterolateral thigh flap (ALT flap), raised from the left thigh. Arterial supply was ensured by

microsurgical end-to-side anastomosis of the flap artery to the right common carotid artery. Venous drainage was established by end-to-end anastomosis of the flap vein to a side branch of the

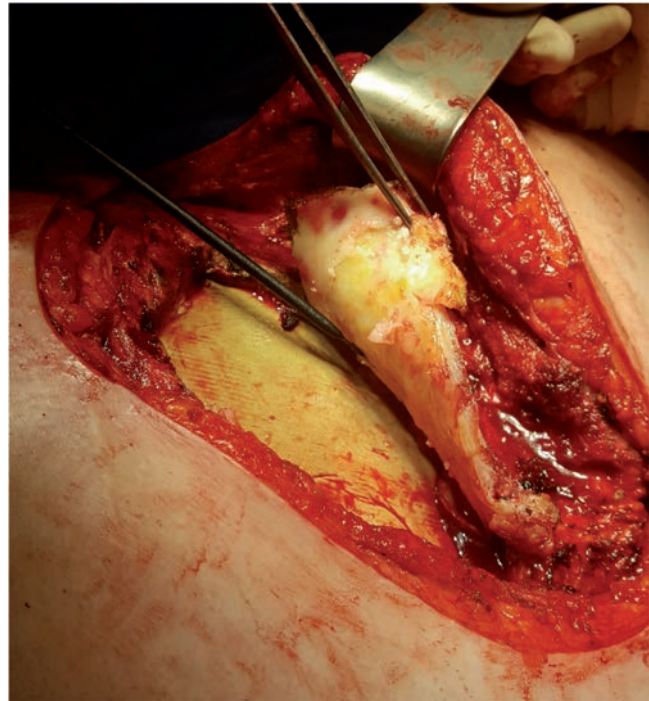


Figure 4. Revision surgery after two years showed fibrous remodeling of the upper and lower Prolene mesh (upper mesh lifted with forceps) as well as an accumulation of pus between the methylmethacrylate and the lower Prolene mesh.

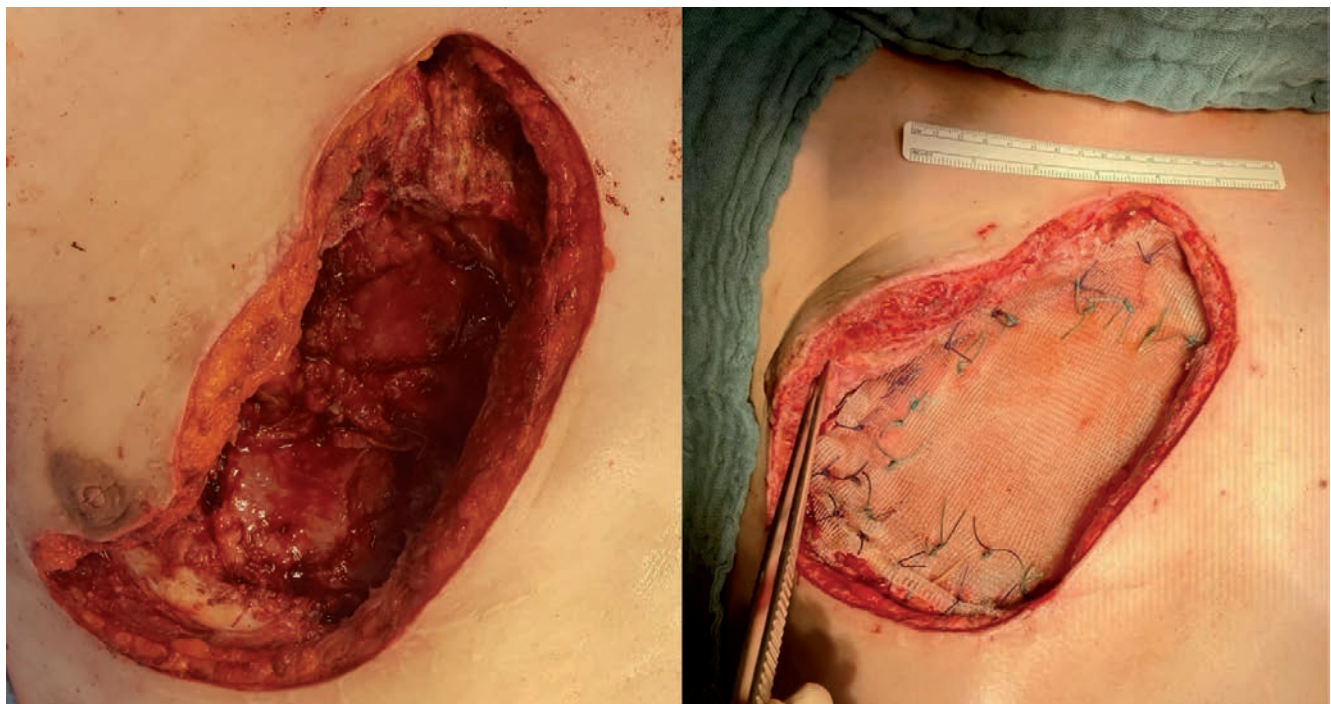


Figure 5. Chest wall reconstruction and stabilization were achieved with a Prolene mesh.

internal jugular vein. A Cook ultrasound probe was attached to the vein to monitor the blood flow postoperatively. A chest tube was inserted into the right thoracic cavity, and a suction pressure of -10 cmH₂O was applied. After implantation of the ALT flap, the defect was closed without tension (Figure 6). The patient was extubated in the operating room and transferred to the intermediate care unit. Postoperatively, he suffered from severe pain, which required administering high doses of morphine and the placement of an epidural catheter. Analgetic therapy could be gradually reduced during the postoperative course. A postoperative CT scan for sudden dyspnea and increased need for oxygen on postoperative day 8 showed a segmental pulmonary embolism and therapeutic anticoagulation was administered. The patient was discharged on postoperative day 13. Oral anticoagulation with rivaroxaban was prescribed for six months, as well as home oxygen therapy.

On follow-up 2 weeks after surgery, the physical examination showed a well-healed ALT flap and a stable chest wall. A yearly follow-up was recommended. The patient was again referred to a specialized pain center.

Discussion

Chordomas are rare, malignant, and locally aggressive neoplasms derived from primitive notochord remnants. They are most commonly found along the axial axis; extra-axial manifestation is the rarest subtype [2]. The gold standard in therapy is complete surgical resection, including the initial biopsy track and adjuvant radiotherapy. More common indications for chest wall resections are primary chest wall tumors such as sarcomas or desmoid tumors, chest wall infiltrating primary tumors or metastases of for example lung or breast cancers, and infections such as radiation necrosis or osteomyelitis of the chest wall [1].

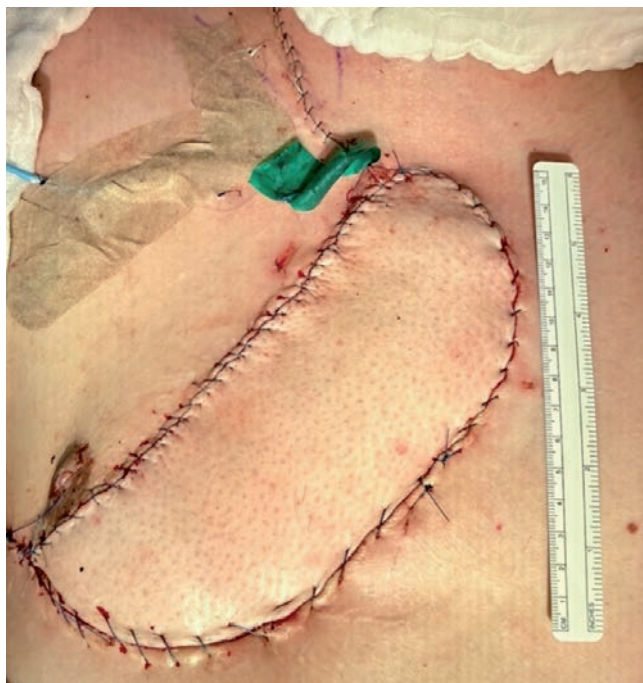


Figure 6. Final result after the insertion of the anterolateral thigh flap and vascular connection.

After full-thickness chest wall resection, as in the presented case, the defects can be covered exclusively by soft-tissue reconstruction or additional implantation of prosthetic material, flexible or rigid, such as mesh or methylmethacrylate.

In our experience, chest wall stabilization should be performed with as little allogeneic material as possible due to the increased risk of infection introduced by the artificial material. Especially in chest wall resection followed by radiation therapy, reconstruction should be achieved preferably without prosthetic material [1].

When reconstructing the thoracic wall with alloplastic material, coverage with well-vascularised flaps is recommended to avoid dead space and seroma accumulation, which would predispose to infection [3,4]. Based on the thoracoacromial vessels, the pedicled myocutaneous pectoralis major island flap is an established procedure and our flap of first choice for ventral thoracic and sternal reconstruction [5]. It is a reliable and robust flap with constant anatomy and rapid flap elevation. The pectoralis major muscle can also be used as a muscle flap without a skin island. It can, especially after transection of the humeral tendon, be advanced over the midline for sternal coverage. However, the pedicled pectoralis major flap is less versatile in reconstructing the inferior chest wall unless used as a turnover flap. Free flaps are a suitable alternative for revision cases or larger defects of the inferior chest wall. The myocutaneous or adipocutaneous ALT flap combines all qualities of an ideal soft tissue flap, such as the possibility of harvesting large skin paddles, simultaneous flap harvesting of the recipient site, potential of reinnervation, and a long vascular pedicle, which allows for isolating the anastomotic site away from the infected area [6,7]. Previous studies have consistently reported low donor site morbidity, with lateral thigh paresthesia as the most common complication [8]. However, unstable hemodynamics might limit the application of the free ALT flap to extended sternal defects due to requiring inotropic agents, which potentially compromise flap perfusion.

Conclusions

Complex chest wall resection and reconstruction should be performed in multidisciplinary settings and according to oncological guidelines. Implantation, type of prosthetic material, and the use of local or distant muscle flaps for soft tissue reconstruction must be carefully considered and individually adapted to the respective situation.

References

1. Merritt RE. Chest wall reconstruction without prosthetic material. *Thorac Surg Clin* 2017;27:165-9.
2. Stacchiotti S, Sommer J, Chordoma Global Consensus Group. Building a global consensus approach to chordoma: a position paper from the medical and patient community. *Lancet Oncol* 2015;16:e71-83.
3. Fricke A, Bannasch H, Klein HF, et al. Pedicled and free flaps for intrathoracic fistula management. *Eur J Cardiothorac Surg* 2017;52:1211-7.
4. Momeni A, Kovach SJ. Important considerations in chest wall reconstruction. *J Surg Oncol* 2016;113:913-22.
5. Simunovic F, Koulaxouzidis G, Stark GB, Torio-Padron N. Infraareolar pectoralis major myocutaneous island flap as treatment of first choice for deep sternal wound infection. *J Plast Reconstr Aesthet Surg* 2013;66:187-92.

6. Weise H, Naros A, Blumenstock G, et al. Donor site morbidity of the anterolateral thigh flap. *J Craniomaxillofac Surg* 2017;45:2105-8.
7. Wee SJ, Hsu SY, Shih PK, et al. Free extended anterolateral thigh myocutaneous flap versus combined pedicled pectoralis major-latissimus dorsi myocutaneous flaps in deep and extensive sternal wound reconstruction. *Microsurgery* 2022;42:810-6.
8. Kimata Y, Uchiyama K, Ebihara S, et al. Anterolateral thigh flap donor-site complications and morbidity. *Plast Reconstr Surg* 2000;106:584-9.