



## Monaldi Archives for Chest Disease

eISSN 2532-5264

<https://www.monaldi-archives.org/>

**Publisher's Disclaimer.** E-publishing ahead of print is increasingly important for the rapid dissemination of science. The **Early Access** service lets users access peer-reviewed articles well before print / regular issue publication, significantly reducing the time it takes for critical findings to reach the research community.

These articles are searchable and citable by their DOI (Digital Object Identifier).

The **Monaldi Archives for Chest Disease** is, therefore, e-publishing PDF files of an early version of manuscripts that have undergone a regular peer review and have been accepted for publication, but have not been through the typesetting, pagination and proofreading processes, which may lead to differences between this version and the final one.

The final version of the manuscript will then appear in a regular issue of the journal.

E-publishing of this PDF file has been approved by the authors.

*All legal disclaimers applicable to the journal apply to this production process as well.*

Monaldi Arch Chest Dis 2023 [Online ahead of print]

*To cite this Article:*

Rathi V, Ish P. **Comments on “Mucoepidermoid carcinoma of the bronchus: a rare early diagnosis”** *Monaldi Arch Chest Dis* doi: 10.4081/monaldi.2023.2747

 ©The Author(s), 2023  
Licensee [PAGEPress](https://www.pagepress.org/), Italy

Note: The publisher is not responsible for the content or functionality of any supporting information supplied by the authors. Any queries should be directed to the corresponding author for the article.

All claims expressed in this article are solely those of the authors and do not necessarily represent those of their affiliated organizations, or those of the publisher, the editors and the reviewers. Any product that may be evaluated in this article or claim that may be made by its manufacturer is not guaranteed or endorsed by the publisher.



## **Comments on “Mucoepidermoid carcinoma of the bronchus: a rare early diagnosis”**

Vidushi Rathi, Pranav Ish

Department of Pulmonary and Sleep Medicine, Vardhman Mahavir Medical College and Safdarjang Hospital, New Delhi

**Contribution-** VR, PI involved in literature search, planning, conduct, writing the original draft of manuscript, literature search, and editing. All the authors have agreed with the submitted manuscript. PI is corresponding author and guarantor for all.

**Corresponding author:** Pranav Ish, Department of Pulmonary and Sleep Medicine, Vardhman Mahavir Medical College and Safdarjang Hospital, Room Number 638, 6th floor, Ansari Nagar West, New Delhi 110029, India. Tel. +91.9958356000. E-mail: [pranavish2512@gmail.com](mailto:pranavish2512@gmail.com)

**Acknowledgements:** None

**Conflict of interest:** The authors declare that they have no conflict of interest regarding current study

**Funding:** The current study is not funded.

**Availability of data and material:** The clinical data and the study materials available from the corresponding author on reasonable request.

Ethics approval: Not applicable

**Patient’s consent:** Written informed consent taken

**Key words:** mucoepidermoid cancer, trachea, follow-up, biopsy

Dear Editor,

An article published in 2020 in this journal reported a rare case of a young medical student presenting with low grade mucoepidermoid carcinoma (MEC) of central airway. Curative sleeve resection was done, with negative margins and no evidence of lymph nodal involvement [1]. The current letter presents a 3-year follow up of the same individual and a short review of the evidence available for post-resection monitoring in such patients.

After the successful surgery of the patient in 2020, a close follow-up was done with annual check bronchoscopies (Figure 1). Each of these showed a healthy anastomotic site in the left main bronchus with pallor and a raised healing scar. There was no endobronchial lesion or recurrence of growth. The patient was asymptomatic but apprehensive regarding recurrence. Due to paucity of literature on follow-up in MEC, a biopsy of the original site of the lesion was planned which revealed granulation fibrous tissue consistent with a healthy anastomotic site reaction. Thus, there was no clinical, radiological, Bronchoscopic or pathological evidence of recurrence for follow-up of 3 years till date.

MECs of the airways are rare tumours and thus, no separate treatment or follow-up guidelines are available. A PubMed search of [mucoepidermoid carcinoma] and [{trachea or bronchus or airway}] revealed only 46 studies till date. The literature regarding follow-up of such tumors in adult patients is limited to a few case series and reports enlisted in Table 1.

A review of the above listed studies makes it evident that MEC of airways is an uncommon malignancy. It is often located in the trachea or near the carina. Most patients require a surgical dissection, which could be a sleeve resection or an extensive surgery depending on the extent of the tumour. Low grade tumours have good prognosis and survival, and can be followed-up clinically together with radiological investigations. There is no recommendation regarding the need for a repeat biopsy during post resection follow-up of MEC. Most case studies followed-up with only radiological surveillance. However, a high-grade tumour with lung or lymph node metastases needs to be followed up diligently because of poor overall survival.

Our three-year follow-up with annual check bronchoscopy showed that MEC did not recur post-resection. Additionally, healthy scar tissue was maintained at the anastomotic site. There were no intra-airway complications during the three-year follow-up. The rare incidence of MEC makes it difficult to reach consensus for or against bronchoscopy-based follow-up.

Currently, it may be advisable to use bronchoscopy as a complementary modality on an individual basis to survey for recurrence of MEC.

## References

1. Kumar R, Puri HV, Gupta N, et al. Mucoepidermoid carcinoma of the bronchus: a rare early diagnosis. *Monaldi Arch Chest Dis* 2020;90:1258.
2. Al-Halawani M, Abdeen Y. Mucoepidermoid carcinoma of the trachea. *Quant Imaging Med Surg* 2018;8:259-60.
3. Abu Saleh WK, Aljabbari O, Ramchandani M. Mucoepidermoid carcinoma of the tracheobronchial tree. *Methodist DeBakey Cardiovasc J* 2015;11:192-4.
4. Kawano O, Yuki D, Fukai I, Tsubota N. Successful treatment of mucoepidermoid carcinoma in the left main bronchus. *Surg Case Rep* 2015;1:85.
5. Breyer RH, Dainauskas JR, Jensik RJ, Faber LP. Mucoepidermoid carcinoma of the trachea and bronchus: the case for conservative resection. *Ann Thorac Surg* 1980;29:197-204.
6. Sonobe S, Inoue K, Tachibana S, et al. A case of pulmonary mucoepidermoid carcinoma responding to carboplatin and paclitaxel. *Jpn J Clin Oncol* 2014;44:493-6.
7. Kim TS, Lee KS, Han J, et al. Mucoepidermoid carcinoma of the tracheobronchial tree: radiographic and CT findings in 12 patients. *Radiology* 1999;212:643-8.
8. Heitmiller RF, Mathisen DJ, Ferry JA, et al. Mucoepidermoid lung tumors. *Ann Thorac Surg* 1989;47:394-9.
9. Chen F, Tatsumi A, Miyamoto Y. Successful treatment of mucoepidermoid carcinoma of the carina. *Ann Thorac Surg* 2001;71:366-8.
10. Zheng X, Herth FJF, Sun J. Initial experience with hybrid argon plasma coagulation as a novel local treatment method for tracheobronchial mucoepidermoid carcinoma. *Respiration* 2019;98:461-6.
11. Abdennadher M, Rivera C, Gibault L, et al. [Tumeurs muco-épidermoïdes trachéo-bronchiques chez l'adulte. À propos d'une série de 22 cas]. [Article in French]. *Rev Pneumol Clin* 2015;71:27-36.

Figure 1. Serial bronchoscopy done over 3 years. showing a healthy line of anastomosis in left main bronchus. Image of the carina in 2021 (A), 2022 (C) and 2023 (E) with an image of the left main bronchus 2021 (B), 2022 (D) and 2023 (F) showing a healthy line of anastomosis in left main bronchus.

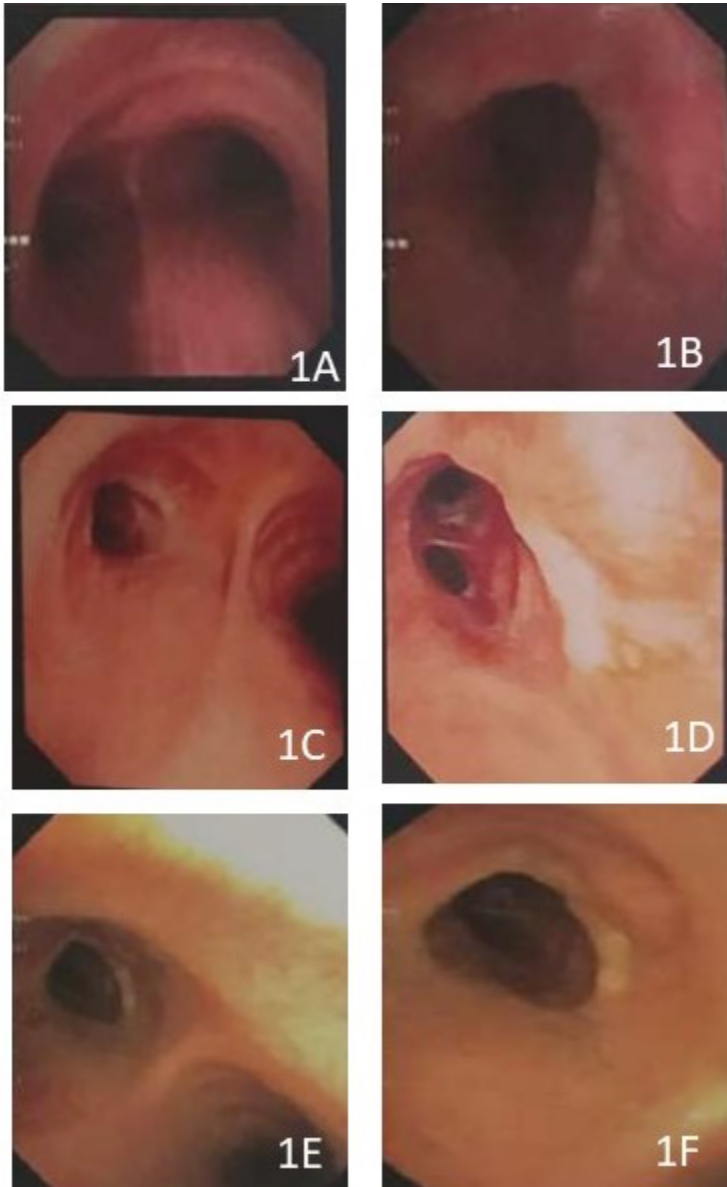


Table 1. Studies showing follow-up of mucoepidermoid carcinoma of airways.

Author	Patients	Treatment	Follow-up duration	Follow-up modality
Al-Halawani et al. [2]	1	Open thoracotomy	2 Years	Bronchoscopy
Abu Saleh et al. [3]	1	Open thoracotomy	6 months	CT
Kawano et al. [4]	1	Open thoracotomy	2 years	Clinical
Breyer et al. [5]	5	Bronchoplasty and lobectomy	4-15 years	Clinical and bronchoscopy
Sonobe et al. [6]	1	Chemotherapy in view of lung metastasis	25 months	Clinicoradiological
Kim et al. [7]	8	Surgery	8-103 months	Clinicoradiological
Heitmiller et al. [8]	18	Surgery	12 low-grade tumours had 100% survival at mean 4.7 years and all 8 high grade died in 16 months	Clinicoradiological
Chen et al. [9]	1	Carina resection	1 year	Clinicoradiological
Zheng et al. [10]	2	Argon plasma coagulation	3 months	Not mentioned
Abdennadher et al. [11]	22	Surgery	10 high grade tumour patients had 0% survival at 6 years	Not mentioned