



Monaldi Archives for Chest Disease

eISSN 2532-5264

<https://www.monaldi-archives.org/>

Publisher's Disclaimer. E-publishing ahead of print is increasingly important for the rapid dissemination of science. The **Early Access** service lets users access peer-reviewed articles well before print / regular issue publication, significantly reducing the time it takes for critical findings to reach the research community.

These articles are searchable and citable by their DOI (Digital Object Identifier).

The **Monaldi Archives for Chest Disease** is, therefore, e-publishing PDF files of an early version of manuscripts that have undergone a regular peer review and have been accepted for publication, but have not been through the typesetting, pagination and proofreading processes, which may lead to differences between this version and the final one.

The final version of the manuscript will then appear in a regular issue of the journal.

E-publishing of this PDF file has been approved by the authors.

All legal disclaimers applicable to the journal apply to this production process as well.

Monaldi Arch Chest Dis 2024 [Online ahead of print]

To cite this Article:

Sharma D, V V, Saini JK, et al. **Assessing the effectiveness and safety of transbronchial lung cryobiopsy utilizing a flexible bronchoscope with an endobronchial blocker in diffuse parenchymal lung lesions.** *Monaldi Arch Chest Dis* doi: 10.4081/monaldi.2024.2887

 ©The Author(s), 2024
Licensee [PAGEPress](#), Italy

Note: The publisher is not responsible for the content or functionality of any supporting information supplied by the authors. Any queries should be directed to the corresponding author for the article.

All claims expressed in this article are solely those of the authors and do not necessarily represent those of their affiliated organizations, or those of the publisher, the editors and the reviewers. Any product that may be evaluated in this article or claim that may be made by its manufacturer is not guaranteed or endorsed by the publisher.



Assessing the effectiveness and safety of transbronchial lung cryobiopsy utilizing a flexible bronchoscope with an endobronchial blocker in diffuse parenchymal lung lesions

Deepak Sharma,¹ Vinay V,² Jitendra Kumar Saini,³ Prabhpreet Sethi,⁴
Lokender Kumar,⁴ Praveen Kumar Dubey⁵

¹Department of Pulmonary and Critical Care Medicine, King George's Medical University, Lucknow; ²Department of Pulmonary, Critical Care and Sleep Medicine, All India Institute of Medical Sciences, Patna; ³Thoracic Oncology Clinic, National Institute of Tuberculosis and Respiratory Diseases, New Delhi; ⁴National Institute of Tuberculosis and Respiratory Diseases, New Delhi; ⁵Department of Pulmonary, Critical Care and Sleep Medicine, All India Institute of Medical Sciences, Raipur, India

Correspondence: Jitendra Kumar Saini, Thoracic Oncology Clinic, National Institute of Tuberculosis and Respiratory Diseases, Sri Aurobindo Marg (Near Qutab Minar), New Delhi, 110030, India.

Tel.: +91-9818012841/ 8700977853.

E-mail: jk.saini@nitrd.nic.in

Contributions: DS, VV, JKS, PS, LK, PKD, concepts; DS, VV, JKS, PS, definition of intellectual content; DS, VV, literature research; DS, VV, JKS, manuscript preparation; VV, manuscript editing. All authors reviewed the manuscript review and gave final approval.

Conflict of interest: the authors declare that they have no competing interests, and all authors confirm accuracy.

Ethics approval and consent to participate: this study was extended in conjunction with the research project labeled as Office letter no: NITRD/PGEC/2017/6109, obtained from the Institutional Research and Ethical Committee.

Patient consent for publication: written informed consent was obtained.

Funding: none.

Availability of data and materials: all data generated or analyzed during this study are included in this article.

Abstract

Transbronchial lung cryobiopsy (TBLC) with flexible bronchoscope represents an encouraging modality to obtain a larger size specimen without crush artifact, and a higher diagnostic yield in patients with diffuse parenchymal lung lesions/diseases as compared to conventional transbronchial lung biopsy, and fewer complications as opposed to surgical lung biopsy. Artificial airway is preferred as it provides better airway protection in cases of severe bleeding. Although various researchers have published data on different modalities, the data is not sufficient to standardize a single technique. This study describes the procedural technique, safety, and yield of TBLC using a flexible bronchoscope with an endobronchial blocker. We performed a retrospective analysis of 100 consecutive patients who underwent TBLC using flexible bronchoscopy from May 2018 to June 2022. TBLC samples were obtained under moderate sedation without the use of artificial airway or fluoroscopy. Among the 100 patients, the majority were male (63%). The mean age of the enrolled patients was 44.43 ± 15.92 years. The predominant diagnoses in our study were hypersensitivity pneumonitis (27%), followed by sarcoidosis (12%) and tuberculosis (10%). We obtained alveolated lung tissue in 90 out of 100 cases with a median biopsy size of 5 mm (in greatest dimension, interquartile range 5-4 mm), resulting in a specific histopathological diagnosis in 82 cases. The most frequent complications were bleeding and pneumothorax (13%). Mild bleeding occurred in 58% of the patients, and moderate bleeding occurred in 20% of the patients. There was no episode of severe/life-threatening bleeding. None of the patients required intensive care unit admission or endotracheal intubation. In conclusion, the use of TBLC through flexible bronchoscopy with an endobronchial blocker emerges as a minimally invasive, secure, time-efficient, and readily reproducible technique. Significantly, this procedure can be seamlessly executed in the bronchoscopy suite, eliminating the requirement for an artificial airway or general anesthesia.

Key words: diffuse parenchymal lung lesions, transbronchial lung cryobiopsy, endobronchial blocker, diagnostic yield, safety.

Introduction

Diffuse parenchymal lung disease (DPLD) encompasses a diverse range of over 200 pulmonary disorders, classified into various subtypes according to their clinical, radiological, and histopathological characteristics. The diagnosis of DPLD poses a significant challenge. When the clinical evaluation, laboratory testing, imaging and lung function data do not suffice to reach a definitive diagnosis, lung biopsy with histopathological examination of the tissue is often necessary to obtain a conclusive diagnosis. A recent expert panel report has recommended that TBLC may be considered as an alternative to surgical lung biopsy owing to fewer complications and acceptable diagnostic yield, by adopting precautionary measures such as fluoroscopy and endobronchial blocker [1]. Different operators have described various techniques to perform TBLC [1-9]. Due to associated high morbidity and non-availability of surgical lung biopsy, computed tomography followed by TBLB continues to remain the mainstay of diagnosis of DPLDs in majority of the centers. The small size of TBLB specimen makes it a "histopathologist's nightmare," leading to difficulty in categorization within the spectrum of DPLDs. Although rigid bronchoscopy with bronchial blocker is preferred modality for TBLC, requirement of general anesthesia and rigid bronchoscopy setup are the reasons for its limited utilization. Development of a safe and efficacious technique to perform TBLC with flexible bronchoscope in bronchoscopy room should address these practical issues. The present study was undertaken to evaluate yield and safety of TBLC using flexible bronchoscope with Arndt endobronchial blocker.

Materials and Methods

Study design, population and settings

This retrospective analysis involved one hundred consecutive cases of suspected diffuse parenchymal lung diseases in whom TBLC was performed using flexible bronchoscope under sedation at our tertiary care referral centre from May 2018 to June 2022. Ethical clearance was obtained from the institutional ethical committee. Patients with diffuse parenchymal lung infiltrates for whom a definitive diagnosis could not be established following clinical, radiological, and laboratory assessments were included in this study. Patients with platelet count $<70,000/\text{mm}^3$, an international normalized ratio >1.5 , or an activated partial thromboplastin time >50 seconds were excluded from the study. Additionally, exclusion criteria included a forced expiratory capacity (FVC) less than 50%, forced expiratory volume in the first second (FEV1) below 0.8 L, diffuse bullous disease, or any major comorbidities

like severe cardiac, renal, liver disease or history of bleeding disorder. Patients with pulmonary hypertension and those requiring oxygen were high-risk candidates and detailed risk-benefit assessment was done prior to procedure. Procedural complication including bleeding, pneumothorax, and histopathological diagnosis were analyzed.

Aim of the study

The objective of this study was to assess the safety, diagnostic yield and potential complications associated with Transbronchial Lung Cryobiopsy (TBLC) in patients with diffuse parenchymal lung lesions.

Procedural technique

Equipment

Therapeutic flexible bronchoscope (instrument channel diameter 2.8 mm), Cryostation with gas (cryogen) cylinder, 1.9 mm outer diameter flexible cryoprobe (ERBE, Germany), 9.0 Fr Arndt endobronchial blocker set (Cook inc. Bloomington, USA), Bite block, and airway resuscitation equipment. The bronchoscopist should be proficient in handling the airway emergencies and performing endotracheal intubation if need arises during the procedure.

Patient preparation and procedure

A comprehensive clinical history was obtained, encompassing details on smoking habits, occupational hazards, and drug and pet exposure. Additionally, a chest radiograph and high-resolution computed tomography (HRCT) scan of the thorax were performed along with blood tests comprising of complete blood profile, liver function test, renal function test and coagulation profile. All procedures were carried out in the bronchoscopy suite as a day care procedure without the presence of an anesthetist. Subjects on anticoagulants and aspirin, we performed the procedure after discontinuing the drug for 2-5 days (depending on the drug patient was taking) and ensuring that the international normalized ratio (INR) was less than 1.5. Patients were kept fasting (2 hours for liquids and 6 hours for solids prior to procedure) for the bronchoscopy and a written informed consent was obtained prior to the procedure. No premedication was given. Topical anesthesia included 2 ml of 4% lignocaine and 2ml normal saline nebulization for 5 minutes, 10minutes prior to procedure. For pharyngeal anesthesia, 3-5 sprays of 10% lignocaine was used and loss of gag reflex was used an indicator of adequate anesthesia. Intravenous midazolam and fentanyl were used for

sedation. Starting with 1mg of midazolam and 25µg of fentanyl, intermittent bolus of same dose was repeated to achieve desired level of sedation during the procedure. Average required dose of Midazolam and fentanyl was 2 mg and 75 µg respectively. Supplemental oxygen was provided through nasal cannula and patients had spontaneous breathing without any support of artificial airway or assisted ventilation. After ensuring that the patient was sedated, bite block was placed in mouth. No CO₂ monitor was used. The pulmonologist assessed sedation through clinical monitoring, utilizing indicators such as heart rate, blood pressure, level of consciousness, and pupil size. Adult therapeutic broncho-videoscope (Olympus BF-1TQ170, Olympus Corporation, Japan, channel diameter: 2.8 mm, outer diameter: 6.0 mm) was utilized and adjustable guide loop of the Arndt Blocker was coupled with the distal end of bronchoscope (Figure 1A). Bronchoscope with Arndt blocker was then simultaneously introduced through mouth and method of applying a 1% lignocaine solution through a "spray-as-you-go" approach was employed for providing topical anesthesia to the vocal cords and tracheobronchial tree. Before the sampling procedure, a bronchoscopic examination of the bronchial tree was conducted and Arndt blocker was released into target lobar bronchus by loosening the loop. An assistant held the blocker in place at the level of bite block. The video bronchoscope was kept proximal to the Arndt blocker. Blocker balloon was inflated and deflated to ensure patient's tolerance and adequacy of balloon to block target bronchus. Flexible bronchoscope was then advanced into the segment to be biopsied. Prior to biopsy, cryoprobe was tested in room temperature saline to determine optimal freezing time. Flexible cryoprobe of 1.9-mm (outer diameter) size and length: 900 mm (ERBE, Germany) was inserted through the bronchoscope instrument channel port and advanced till resistance was felt. Once resistance was encountered (up to pleura), probe was retracted by 1.5cm and activated for 3-6s. No fluoroscopic guidance was used. The flexible bronchoscope and cryoprobe were then quickly removed en-block. Immediately, the second assistant inflated the Arndt blocker to block off the target segments (Figure 1B) and secured it in place at the bite block to prevent any displacement. The biopsy sample was taken off after thawing in room temperature saline. The bronchoscope was quickly reintroduced to confirm the inflation and correct positioning of Arndt blocker and to look for bleeding (Figure 1C). The balloon was deflated after 30–40s and airways were observed for bleeding (Figure 1D). Typically, only one biopsy was taken from the area of significant radiographical abnormality from the lower lobes, however, up to 3 biopsies were performed if specimen was found inadequate on visual inspection. The Arndt blocker was removed after ensuring adequate

hemostasis. Subsequently, bronchoscope was removed after performing airway toileting. Patient was kept under observation for 2 hours; continuous monitoring was in place for ECG, heart rate, blood pressure, and oxygen saturation. Chest x-ray was done in the all patients within 3 hours of procedure to rule out pneumothorax. Post-biopsy bleeding was classified as per British Thoracic Society bronchoscopy guidelines [10]. Mild bleeding requiring bronchoscopic aspiration, and bleeding halted on its own. Moderate bleeding, intubation with the bronchoscope in a wedge position, and use of adrenaline (1:10000) or cold saline to stop bleeding. Severe bleeding demanded interventions like bronchial blocker placement, resuscitation, blood transfusion, Critical Care Unit admission, or death.

The study focused on primary endpoints, including the pathological diagnostic yield, the final multidisciplinary diagnosis, the sample size (in greatest dimension), and the complication rate (specifically, the occurrence of pneumothorax and bleeding). These endpoints collectively served as crucial measures to evaluate the effectiveness and safety of the procedures conducted in the study. Clinicians, radiologists, and pathologists subsequently reviewed clinical information, radiological characteristics, and biopsy findings obtained from TBLC. Final diagnosis was made based on institutional multidisciplinary diagnosis (MDD) committee.

Statistics

The collected data were transformed into variables, coded, and entered in Microsoft Excel. The data were analyzed and statistically evaluated using Statistical Package for Social Studies (SPSS) IBM manufacturer, Chicago, USA, Windows version 23.0. Continuous variables were expressed in Mean \pm SD (Standard deviation) while discrete variables were expressed in number and percentage.

Results

Among 100 patients, 63 were male and 37 were female. The mean age of the enrolled patients was 44.43 \pm 15.92 years. Alveolated lung tissue was obtained in 90 patients, specimen size ranging between 4 mm to 8 mm with a median size of 5mm (In greatest dimension; IQR:5-4mm). Biopsy specimen size of the tissue is shown in Figure 2. The biopsy reports confirmed the existence of pleural tissue in 15 patients. No crush artifact was observed in any of the biopsy samples obtained.

Diagnostic yield

Definitive histopathological diagnosis was made in 82 patients and for 8 patients, confident diagnosis could not be ascertained based on histology. Remaining 10 samples were reported as inadequate bronchial mucosal tissue or non-specific inflammation. The most frequently identified diagnoses comprised Hypersensitivity Pneumonitis (n=27), followed by Sarcoidosis (n=12), Tuberculosis (n=10), Adenocarcinoma (n=6), Lymphangioleiomyomatosis (n=4), Nonspecific Interstitial Pneumonia (n=4), Idiopathic Pulmonary Fibrosis (n=3), Langerhans Cell Histiocytosis (n=3), Organizing Pneumonia (n=2), Respiratory Bronchiolitis Associated Interstitial Lung Disease (n=2), and various less common conditions (such as Lymphocytic Interstitial Pneumonia, Follicular Bronchiolitis, Chronic Bronchitis with Emphysema, Anthracosis, Diffuse Panbronchiolitis, Anthrosilicotic Fibrosis, Obliterative Bronchiolitis, Lipoid Pneumonia, and Non-Small Cell Carcinoma of the Lung). Diagnosis with their histopathological findings obtained in the study is shown in Table 1.

Complications

In terms of safety, mild bleeding was observed in 58 patients while twenty patients experienced moderate bleeding. Minimal or no bleeding was seen in 22 patients and there were no mortality or significant bleeding attributable to the procedure. Pneumothorax occurred in 13 patients, with six of them necessitating intercostal drainage tube placement, while the remaining cases were managed conservatively with high flow oxygen therapy. Eight out of 13 patients with pneumothorax (61.5%) had pleural tissue in the biopsy. Complications are detailed in Table 2.

Discussion

Timely diagnosis holds significant importance in effectively managing patients with diffuse parenchymal lung diseases (DPLD). Presently, the diagnosis of DPLD typically involves the use of high-resolution computed tomography (HRCT) and bronchoalveolar lavage (BAL), with the option of performing a lung biopsy and subsequent histopathological examination when deemed necessary. While surgical lung biopsy remains the most efficacious sampling method, it is associated with an elevated risk of infection, acute exacerbation, and a reported 3–4% mortality rate within 30 days [11,12]. The indications for transbronchial lung cryobiopsy in the diagnosis of diffuse parenchymal lung diseases/lesions are currently being assessed within the framework of a multidisciplinary discussion. Additionally, the

comparison of its risks and benefits with those of surgical lung biopsy (SLB) is under examination. However, the recent European Respiratory Society (ERS) guidelines recommend performing TBLC for unclassifiable ILD when histopathological diagnosis is needed. For undiagnosed ILD patients with inconclusive TBLC results, the Task Force suggests proceeding to step-up SLB if histopathological data is required [13]. The reported diagnostic yields of TBLC in the literature range from 60% to 100% [6,7,9,14-18], and observed complications, such as pneumothorax (0–30%) and bleeding, exhibit considerable variability across different studies [6,7,9,14,19]. The standardization of the technique is currently under consideration. In our study, TBLC was performed as a day-care procedure in a specialized bronchoscopy suite. The most prevalent diagnoses included hypersensitivity pneumonitis (27%), followed by sarcoidosis (12%), and tuberculosis (10%). This observation could be attributed to the contrast between India and the developed Western world. While 65% of interstitial lung disease (ILD) cases in Western countries are categorized as idiopathic interstitial pneumonia (IIP), the predominant ILD diagnosis in India is hypersensitivity pneumonitis (HSP), constituting approximately 47.3% of cases [20]. In our study, 10% of patients received a tuberculosis diagnosis following a biopsy indicating necrotizing granuloma. In a tuberculosis-endemic country such as India, it is crucial to consider infectious causes when faced with patients exhibiting radiological features suggestive of ILD, as pulmonary tuberculosis (PTB) can closely resemble ILD [21]. In inadequately treated PTB cases, diagnosing becomes challenging due to subtle clinical features and misleading radiological signs like fibrosis or lymphadenopathy, often leading physicians to consider ILD.

Out of the 100 patients, alveolated lung tissue was successfully obtained in 90 cases. The tissue diagnosis along with the clinico-radiological information was integrated to establish a final multidisciplinary diagnosis for comprehensive patient management. A definitive histopathological diagnosis was provided for 82 patients. The diagnostic and clinical yields in our study stood at 82% and 90%, respectively. Notably, these values align closely with those reported by Ravaglia et al., (87.8% and 90.1%) [14]. In a study by Anne M. O'Mahony et al., utilizing the same modality documented a diagnostic yield of 67.1% and a clinical yield of 93.3% [6]. Bango-Alvarez et al. reported an 86% yield in their study employing two bronchoscopes in a sequential manner for TBLC [9]. Approximately 10% of cryobiopsies were deemed non-diagnostic, primarily due to limited alveolar tissue, bronchial mucosal tissue, and non-specific inflammation. The ideal biopsy size that allows for effective pattern recognition remains undetermined. In our study, biopsy specimen sizes varied between 4 mm and 8 mm

with a median size of 5mm. Pathologists generally regard a specimen size of at least 5 mm (in greatest dimension) as appropriate for histological evaluation [22], and a greater diagnostic yield is typically associated with larger biopsy samples containing more alveolated lung tissue [15,23]. Recent research conducted by Loo K et al. revealed the efficacy of TBLC in diagnosing acute rejection and assessing its severity among mechanically ventilated lung allograft patients. The study showed that utilizing a cryoprobe enabled the retrieval of more alveolar tissue and samples containing increased blood vessels. The researchers concluded that employing cryoprobes, whether 1.9mm or 2.4mm, significantly improved diagnostic accuracy compared to forceps. Furthermore, the diagnostic performance was notably enhanced when specifically using the 2.4mm cryoprobe [24].

Pneumothorax occurred in 13% of our patients, representing a relatively common adverse event associated with TBLC. Among the 13 cases, seven were managed conservatively, while six required chest tube drainage. The indwelling chest drain (ICD) was removed within 1-5 days after achieving complete lung expansion in all patients. The incidence of pneumothorax in our study was higher than that reported by Bango et al. (4.7%) [9], and lower than the reported incidence (17%) observed in the study by Anne M. O'Mahony et al. [6], both of which had a similar sample size to ours. Notably, the incidence of pneumothorax in TBLC varies widely across studies [6,7,9,14,19]. In a study by Dhooria et al., a lower occurrence of pneumothorax was noted in patients undergoing TBLC under fluoroscopic guidance (5.9%) compared to those without fluoroscopy (20.9%) [25]. However, this trend is not consistently observed in all studies [23,26], suggesting the involvement of other factors, including patient characteristics, procedural factors, and the operator's level of skill. The presence of pleural tissue in histopathological examinations is recognized as a correlated risk factor for pneumothorax [23].

Bleeding represents a prevalent and apprehension-inducing complication associated with lung cryobiopsy, yet it is generally manageable through bronchoscopic intervention employing endobronchial blockers, ice-cold saline, and topical epinephrine instillation [6,9,23,25]. Literature describes bleeding rates ranging from 0% to 56% [6,9,14,18,27], although there exists considerable variation in the definition of bleeding severity across different studies. In our study, 58% had mild bleeding, and 20% of patients experienced moderate post-biopsy bleeding necessitating interventions such as iced saline and/or topical epinephrine, along with prolonged inflation of the Arndt blocker. None of these cases required endotracheal intubation or ICU admission. In our study, echocardiography was not

included in the pre-procedural assessment. We hypothesize that the absence of a diagnosis for pulmonary hypertension in certain patients may have contributed to the comparatively elevated incidence of bleeding observed in our study. All bleeding incidents were effectively managed within the confines of the bronchoscopy room, and no procedure-related fatalities occurred. A study by Hetzel et al. reported a significantly higher incidence of moderate or severe bleeding following TBLC compared to TBLB (16.2% vs. 4.2%) [27]. In a meta-analysis [28], Johansson et al. identified substantial heterogeneity across studies reporting bleeding following TBLC, with a mean incidence of 26.6% and a range of 0% to 78%. They proposed that the diverse rates of bleeding could be attributed to variations in procedural techniques, such as the duration of freeze time and probe positioning. A recent meta-analysis also underscored a higher risk of moderate to severe bleeding in patients undergoing cryobiopsy compared to those undergoing forceps biopsy [29]. Notably, the majority of severe bleeding episodes reported in the literature were successfully controlled through the placement of a bronchial blocker or catheter [30]. The routine use of an endobronchial blocker has demonstrated a significant reduction in the occurrence of moderate to severe bleeding in recent studies [6,25,31].

The procedures were conducted in a dedicated bronchoscopy suite with an experienced team of bronchoscopists and nursing staff with standard monitoring equipment, intubation tools, and access to ICU care if deemed necessary. The approach to conducting TBLC varies, encompassing factors such as the setting (bronchoscopy room versus operating theater), the method of bronchoscopy (flexible versus rigid), sedation (moderate sedation with a conscious patient versus general anesthesia), and strategies for managing complications, such as bleeding. While this study did not specifically address these issues, it employed a straightforward and standard bronchoscopic approach utilizing an Arndt endobronchial blocker, which is easily replicable. Conducting flexible bronchoscopy in a bronchoscopy room with moderate sedation is a more cost-effective alternative than performing it in an operating room under general anesthesia. Depending on the institution, this approach may prove advantageous in countries with a high disease burden, where scheduling constraints in the operating room and economic considerations are prominent. Drawbacks associated with this approach primarily center around the potential for complications, particularly severe bleeding. While rigid bronchoscopy is the preferred option, but its availability is limited in many centers. Our approach involved incorporating TBLC as a standard bronchoscopic procedure, implementing thorough precautionary measures.

Our study is subject to certain limitations, including retrospective study design and single-center experience. Notably, a significant portion of our cases involved hypersensitivity pneumonitis, sarcoidosis, and tuberculosis, which can be diagnosed with a small lung tissue sample. However, this stands in contrast to DPLDs with usual interstitial pneumonia (UIP) and other idiopathic interstitial pneumonias, where disease characterization necessitates both peripheral and larger lung tissue. Consequently, the use of a single biopsy sample may restrict the generalizability of our findings to other causes of DPLDs. It's important to note that we did not employ fluoroscopy due to its non-availability at our institute. The incorporation of fluoroscopy could potentially enhance the patient safety. Additionally, the absence of an artificial airway/conduit influenced our decision to limit the number of biopsies to mitigate the risk of bleeding. However, it's crucial to highlight that this technique is not suitable for cases suspected to have UIP and other idiopathic interstitial pneumonias, where more lung tissue and peripheral sampling are required for disease characterization. The increased complexity of these cases raises the risk of potential complications, necessitating the use of general anesthesia with an airway conduit in such situations.

Ongoing studies aim to address the limitation of insufficient lung tissue for histopathological diagnosis in many cases. These investigations seek to enhance the efficacy and safety of TBLC through initiatives such as incorporating rapid on-site examination (ROSE) of the acquired tissue [32], and employing a sheathed cryoprobe with a 1.1 mm diameter [33].

Conclusions

Our study demonstrates that TBLC using flexible bronchoscopy with Arndt blocker is a complex but high-yielding and safe procedure with low prevalence of complication. To facilitate a successful execution, seamless collaboration among team members is essential during the procedure. Predefined roles should be assigned in advance, and a stepwise review of the process is recommended to enhance the communication. Nevertheless, our current recommendation is that operators proficient in handling airway complications, preferably with prior experience in TBLC, should exclusively perform this procedural modality. It is advisable that such procedures take place in an institution equipped to manage respiratory emergencies.

References

1. Maldonado F, Danoff SK, Wells AU et al. Transbronchial cryobiopsy for the diagnosis of interstitial lung diseases: CHEST guideline and expert panel report. *Chest* 2020;157:1030-42.
2. Hetzel J, Maldonado F, Ravaglia C, et al. Transbronchial cryobiopsies for the diagnosis of diffuse parenchymal lung diseases: expert statement from the cryobiopsy working group on safety and utility and a call for standardization of the procedure. *Respiration* 2018;95:188-200.
3. Dhooria S, Bal A, Sehgal IS, et al. Transbronchial lung biopsy with a flexible cryoprobe: first case report from India. *Lung India* 2016;33:64-8.
4. Madan K, Mittal S, Hadda V, Mohan A. Cryoprobe transbronchial lung biopsy with flexible bronchoscope using Arndt endobronchial blocker. *Lung India* 2019;36:241-3.
5. Madan K, Mittal S, Gupta N, et al. Cryoprobe transbronchial lung biopsy: how we do it? *Lung India* 2018;35:520-2.
6. O'Mahony AM, Burke L, Cavazza A, et al. Transbronchial lung cryobiopsy (TBLC) in the diagnosis of interstitial lung disease: experience of first 100 cases performed under conscious sedation with flexible bronchoscope. *Ir J Med Sci* 2021;190:1509-17.
7. Ramaswamy A, Homer R, Killam J, et al. Comparison of transbronchial and cryobiopsies in evaluation of diffuse parenchymal lung disease. *J Bronchology Interv Pulmonol* 2016;23:14-21.
8. Dhooria S, Sehgal IS, Bal A, et al. Transbronchial lung biopsy with a flexible cryoprobe during rigid bronchoscopy: standardizing the procedure. *Lung India* 2016;33:248-9.
9. Bango-Álvarez A, Ariza-Prota M, Torres-Rivas H, et al. Transbronchial cryobiopsy in interstitial lung disease: experience in 106 cases - how to do it. *ERJ Open Res* 2017;3:00148-2016.
10. Du Rand IA, Blaikley J, Booton R, et al. British Thoracic Society guideline for diagnostic flexible bronchoscopy in adults: accredited by NICE. *Thorax* 2013;68:i1-44.
11. Raghu G, Collard HR, Egan JJ, et al. An official ATS/ERS/JRS/ALAT statement: idiopathic pulmonary fibrosis: evidence-based guidelines for diagnosis and management. *Am J Respir Crit Care Med* 2011;183:788-824.
12. Kaarteenaho R. The current position of surgical lung biopsy in the diagnosis of idiopathic pulmonary fibrosis. *Respir Res* 2013;14:43.

13. Korevaar DA, Colella S, Fally M, et al. European Respiratory Society guidelines on transbronchial lung cryobiopsy in the diagnosis of interstitial lung diseases. *Eur Respir J* 2022;60:2200425.
14. Ravaglia C, Wells AU, Tomassetti S, et al. Diagnostic yield and risk/benefit analysis of trans-bronchial lung cryobiopsy in diffuse parenchymal lung diseases: a large cohort of 699 patients. *BMC Pulm Med* 2019;19:16.
15. Babiak A, Hetzel J, Krishna G, et al. Transbronchial cryobiopsy: a new tool for lung biopsies. *Respiration* 2009;78:203-8.
16. Griff S, Ammenwerth W, Schönfeld N, et al. Morphometrical analysis of transbronchial cryobiopsies. *Diagn Pathol* 2011;6:53.
17. Chou CL, Wang CW, Lin SM, et al. Role of flexible bronchoscopic cryotechnology in diagnosing endobronchial masses. *Ann Thorac Surg* 2013;95:982-6.
18. Pajares V, Puzo C, Castillo D, et al. Diagnostic yield of transbronchial cryobiopsy in interstitial lung disease: a randomized trial. *Respirology* 2014;19:900-6.
19. Fruchter O, Fridel L, El Raouf BA, et al. Histological diagnosis of interstitial lung diseases by cryo-transbronchial biopsy. *Respirology* 2014;19:683-8.
20. Khot MS, Chakraborti A, Saini JK, et al. Comparison of the diagnostic yield of transbronchial lung biopsies by forceps and cryoprobe in diffuse parenchymal lung disease. *Afr J Thorac Crit Care Med* 2023;29:10.7196/AJTCCM.2023.v29i3.799.
21. Vinay V, Abdullah Y, Garg A, et al. The master impersonator: pulmonary tuberculosis mimicking diffuse cystic lung disease – a mini case series of a rare presentation. *J Family Med Prim Care* 2022;11:6590-2.
22. Colby T V., Tomassetti S, Cavazza A, et al. Transbronchial cryobiopsy in diffuse lung disease update for the pathologist. *Arch Pathol Lab Med* 2017;141:891-900.
23. Casoni GL, Tomassetti S, Cavazza A, et al. Transbronchial lung cryobiopsy in the diagnosis of fibrotic interstitial lung diseases. *PLoS One* 2014;9:e86716.
24. Loor K, Culebras M, Sansano I, et al. Lung allograft transbronchial cryobiopsy for critical ventilated patients: a randomised trial. *Eur Respir J* 2023;61:2102354.
25. Dhooria S, Mehta RM, Srinivasan A, et al. The safety and efficacy of different methods for obtaining transbronchial lung cryobiopsy in diffuse lung diseases. *Clin Respir J* 2018;12:1711-20.

26. Tomassetti S, Wells AU, Costabel U, et al. Bronchoscopic lung cryobiopsy increases diagnostic confidence in the multidisciplinary diagnosis of idiopathic pulmonary fibrosis. *Am J Respir Crit Care Med* 2016;193:745-52.
27. Hetzel J, Eberhardt R, Petermann C, et al. Bleeding risk of transbronchial cryobiopsy compared to transbronchial forceps biopsy in interstitial lung disease - a prospective, randomized, multicentre cross-over trial. *Respir Res* 2019;20:140.
28. Johansson KA, Marcoux VS, Ronksley PE, Ryerson CJ. Diagnostic yield and complications of transbronchial lung cryobiopsy for interstitial lung disease: a systematic review and metaanalysis. *Ann Am Thorac Soc* 2016;13:1828-38.
29. Giri M, Huang G, Puri A, et al. Efficacy and safety of cryobiopsy vs. forceps biopsy for interstitial lung diseases, lung tumors, and peripheral pulmonary lesions: an updated systematic review and meta-analysis. *Front Med (Lausanne)* 2022;9:840702.
30. Hagemeyer L, Theegarten D, Treml M, et al. Validation of transbronchial cryobiopsy in interstitial lung disease - Interim analysis of a prospective trial and critical review of the literature. *Sarcoidosis Vasc Diffuse Lung Dis* 2016;33:2-9.
31. Deasy KF, Walsh LJ, Kennedy MP, Henry MT. Endobronchial balloon blockers: a retrospective analysis of their implementation for use in transbronchial cryobiopsy under conscious sedation. *Lung* 2021;199:187-93.
32. Chen X, Luo J, Yang L, et al. The diagnostic value of transbronchial lung cryobiopsy combined with rapid on-site evaluation in diffuse lung diseases: a prospective and self-controlled study. *BMC Pulm Med* 2022;22:124.
33. Safety of a sheath cryoprobe bronchoscopic transbronchial biopsy technique (FROSTBITE). 2022. Available from: <https://clinicaltrials.gov/ct2/show/study/NCT04486560>.

Table 1. Different histological diagnosis obtained in the study.

Diagnosis	Histopathological findings	Number (n=100)
Hypersensitivity Pneumonitis	Thickened interstitium with mononuclear cell infiltrates and fibrosis, ill-defined histiocytic cells	27
Sarcoidosis	Non-necrotizing granuloma with multinucleated giant cells	12
Tuberculosis	Necrotizing granulomatous inflammation with central necrotic zone and mononuclear cells	10
Adenocarcinoma	Malignant epithelial cells forming glandular and tubular pattern	6
Lymphangioleiomyomatosis (LAM)	Lung cysts, abnormal smooth muscle cell (LAM cell) clusters surrounding the cysts	4
Non-specific interstitial pneumonia (NSIP)	Interstitial and chronic inflammation with varying degrees of mononuclear cell inflammation	4
Idiopathic pulmonary fibrosis (IPF)	Clusters of fibroblasts and myofibroblasts, loss of alveolar architecture with patchy subpleural distribution	3
Langerhans cell histiocytosis (LCH)	Cysts and variably aggregates of Langerhans cells	3
Organizing pneumonia (OP)	Buds of granulation tissue within alveoli with mild chronic inflammation	2
Respiratory bronchiolitis-associated interstitial lung disease (RB-ILD)	Pigmented macrophages in the bronchiolar lumens with chronic inflammation and fibrosis	2
Diagnosis not made based on histology alone	Unclassifiable fibrosis, airway centered interstitial inflammation	8
Others		9
Inadequate tissue/ bronchial mucosal tissue/non-specific inflammation	Hyperplastic epithelium of bronchial mucosa, squamous metaplasia, infiltrates in lamina propria, atypical cells, and normal lung parenchyma	10

Table 2. Complications observed in the study.

Complications	Number
Bleeding	n=100
No or minimal bleeding	22
Mild	58
Moderate	20
Severe	0
Pneumothorax	n=13
Required ICD	6
Managed conservatively	7

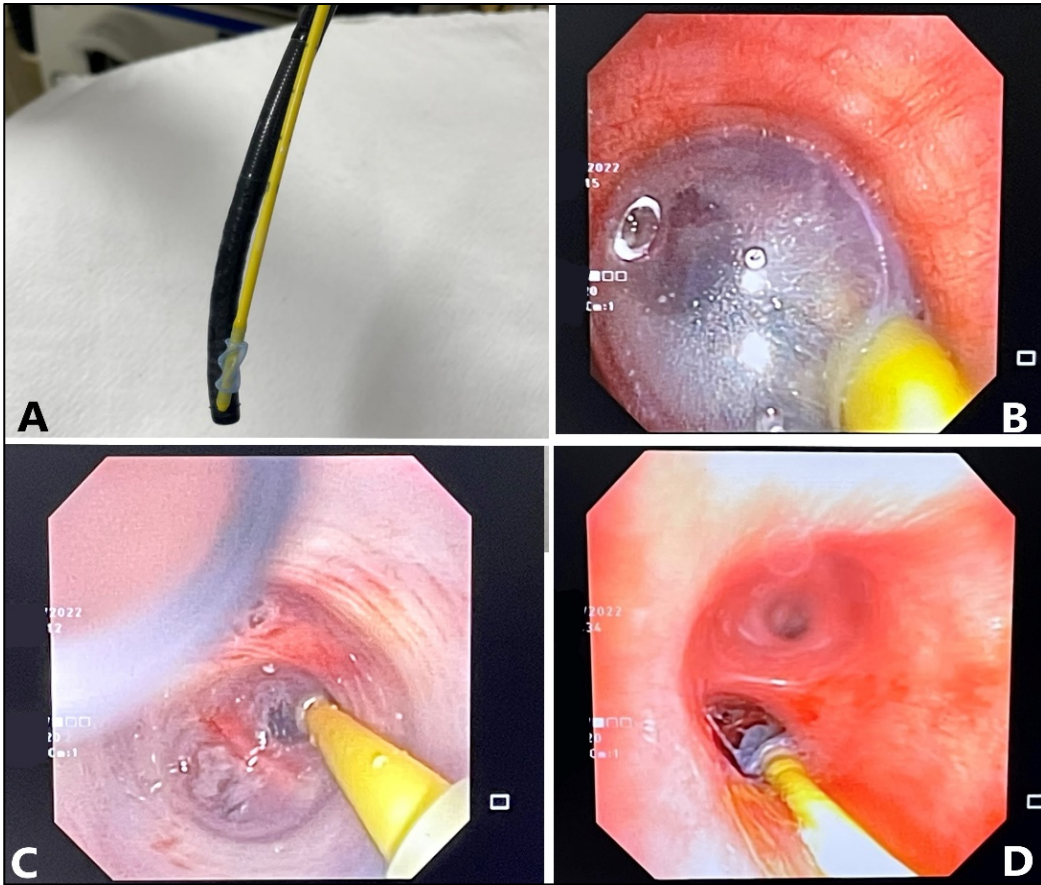


Figure 1. A) Securing the Arndt blocker to the bronchoscope before introducing the scope; B) bronchoscope view with the Arndt blocker inflated; C) bronchoscope view through the inflated balloon; D) bronchoscope view with the Arndt blocker deflated.

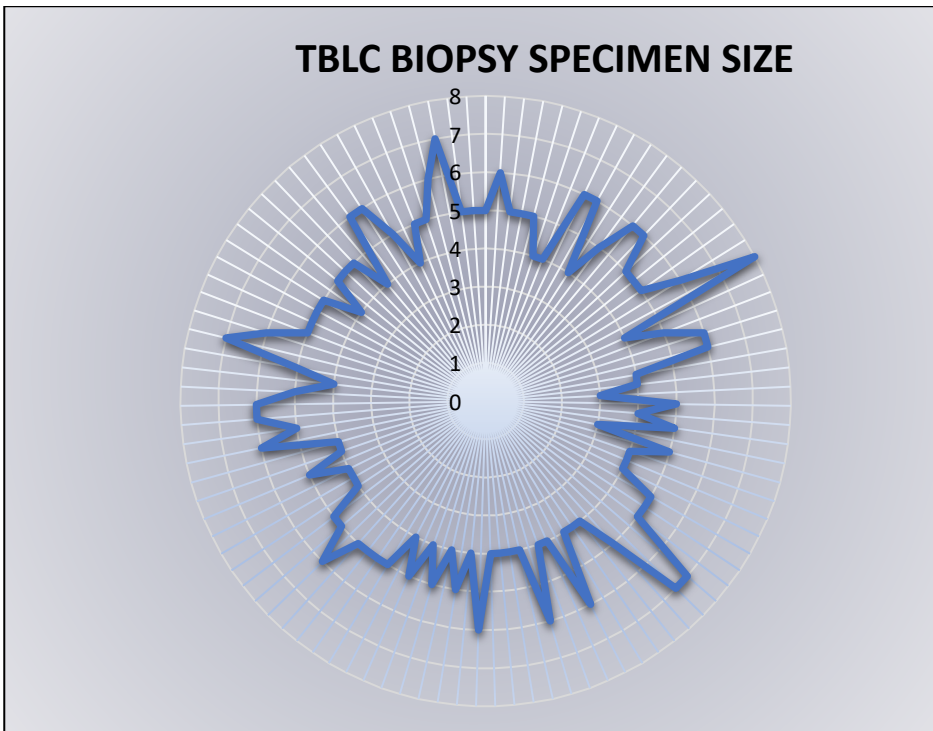


Figure 2. Radar graph depicting the tissue size obtained through TBLC (100 participants) ranging from 0mm at the inner circle to 8mm at the outer circle.