



Monaldi Archives for Chest Disease

eISSN 2532-5264

<https://www.monaldi-archives.org/>

Publisher's Disclaimer. E-publishing ahead of print is increasingly important for the rapid dissemination of science. The **Early Access** service lets users access peer-reviewed articles well before print / regular issue publication, significantly reducing the time it takes for critical findings to reach the research community. These articles are searchable and citable by their DOI (Digital Object Identifier).

The **Monaldi Archives for Chest Disease** is, therefore, e-publishing PDF files of an early version of manuscripts that have undergone a regular peer review and have been accepted for publication, but have not been through the typesetting, pagination and proofreading processes, which may lead to differences between this version and the final one.

The final version of the manuscript will then appear in a regular issue of the journal.

E-publishing of this PDF file has been approved by the authors.

All legal disclaimers applicable to the journal apply to this production process as well.

Monaldi Arch Chest Dis 2024 [Online ahead of print]

To cite this Article:

Romeo MG, Pilato E, Giordano R, et al. **Asymptomatic giant ascending aortic aneurysm: a challenging surgical strategy for a silent bicuspid aortopathy.** *Monaldi Arch Chest Dis* doi: 10.4081/monaldi.2024.2936

 ©The Author(s), 2024
Licensee [PAGEPress](#), Italy

Note: The publisher is not responsible for the content or functionality of any supporting information supplied by the authors. Any queries should be directed to the corresponding author for the article.

All claims expressed in this article are solely those of the authors and do not necessarily represent those of their affiliated organizations, or those of the publisher, the editors and the reviewers. Any product that may be evaluated in this article or claim that may be made by its manufacturer is not guaranteed or endorsed by the publisher.



**Asymptomatic giant ascending aortic aneurysm:
a challenging surgical strategy for a silent bicuspid aortopathy**

Maria Grazia Romeo,¹ Emanuele Pilato,¹ Raffaele Giordano,¹ Giuseppe Comentale,¹
Gabriele Iannelli,¹ Domenico Romeo,² Bruna Miserrafiti,³ Luigi Di Tommaso¹

¹Department of Advanced Biomedical Sciences, Cardiac Surgery, University "Federico II", Naples; ²Department of Biomedical Sciences and Morphologic and Functional Imaging, University of Messina; ³Division of Cardiology, Tiberio Evoli Hospital, Melito Porto Salvo, Italy

Correspondence: Maria Grazia Romeo, Department of Advanced Biomedical Sciences, Cardiac Surgery, University "Federico II", Via Sergio Pansini 5, 80138, Naples, Italy.

Tel.: +39 3297630244.

E-mail: mariagrazia2791@gmail.com

Contributions: MGR, wrote the paper; GC, LDT, RG, GI, BM, DR, EP, revised and accepted the final manuscript. All authors read and approved the final version of the manuscript.

Conflict of interest: the authors declare no conflict of interest.

Ethics approval and consent to participate: no ethical committee approval was required for this case report.

Informed consent: informed consent was obtained from the patient included in this study.

Patient consent for publication: informed consent was obtained from the patient for anonymized information to be published in this article.

Funding: none.

Availability of data and materials: all data underlying the findings are fully available.

Abstract

We report the case of an incidental finding of a huge aneurysm of the ascending aorta with a congenital bicuspid aortic valve type 0-lateral. This severe condition was totally unknown to the patient, who was asymptomatic for cardiovascular disease. The aneurysmal mass involved the entire mediastinum, altering the normal anatomical relations, so the operative strategy was modified intraoperatively, tailoring the surgical technique to the anatomical conditions found. Despite a delayed awakening, the patient had an uncomplicated postoperative course. Therefore, this case highlights the importance of not underestimating nonspecific, seemingly harmless symptoms and signs that may reveal potentially catastrophic pathologies, while also focusing on the surgical technique used. The modified Cabrol procedure, while an underutilized technique, if present in the cardiac surgeon's "arsenal," can represent a life-saving strategy in complex cases requiring an aortic valve and ascending aorta replacement.

Key words: ascending aorta, giant aneurysm, bicuspid aortopathy, modified-Cabrol technique, cardiac-surgery.

Introduction

Giant ascending aortic aneurysm (GAAA) is defined as an aneurysm greater than 10 cm in diameter [1]. This is a life-threatening but very unusual entity, as in most cases complications, such as dissection or rupture, occur before the aneurysm reaches this size. Considering that the risk of complications is related to the aneurysm size, current guidelines recommend surgery for ascending aortic aneurysms (AAA) with a diameter greater than 55 mm; this parameter drops to 50 mm in cases of concomitant bicuspid aortic valve (BAV). BAV is the most common congenital heart defect, occurring in 0.5–2.0% of the general population. BAV-related histological changes include abnormal processing of fibrillin 1 by vascular smooth muscle cells (VSMCs), increased release of metalloproteinases, increased apoptosis of VSMCs and abnormalities in the medial layer, probably due to collagen and elastin. Mutations in genes including NOTCH1 and GATA5, FBN1 and GATATGFBR1/2 and ACTA2 are implicated in the etiology of BAV [2]. The prevalence of AAA is reported to be between 40% and 70% in patients with BAV [3], this condition is therefore considered a predisposing factor for the occurrence of AAA, as hemodynamic changes resulting from atypical valve morphology predispose individuals to turbulent hemodynamics and the appearance of valve degeneration earlier [4]. Bicuspid aortopathy that is clinically manifested by dilatation of the ascending aorta is the most common complication of BAV. The increased risk of aortic dilatation highlights the importance of accurately assessing the size and shape of the aorta in individuals diagnosed with BAV [5].

Therefore, considering that for aneurysms greater than 60 mm in diameter the annual rupture rate is 14%, the diagnosis of an unruptured or dissected GAAA is an extremely rare clinical finding [1].

Case Report

A 56-year-old male was referred to our division after an episode of dyspnea and chest pain arising for the first time following physical exertion. Past medical history revealed no previous or familiar pathologies, among cardiovascular diseases, only hypertension was found, already under pharmacological treatment, blood tests were normal. A physical examination revealed a 4/6 Levine holodiastolic murmur in Erbs area, so a transthoracic echocardiography (TTE) was performed, which to our surprise, showed a monstrous aneurysmal dilatation involving the aortic root and the entire ascending thoracic aorta. The aortic valve was bicuspid with a moderate eccentric regurgitation jet. The aortic arch and descending aorta had normal size. Therefore, a transesophageal echocardiography (TEE) confirmed the presence of a voluminous AAA, in absence of dissection, with estimated dimensions of 118 mm x 116 mm, a BAV, type 0 - lateral, according to Sievers classification, with a 30 mm dilated aortic ring (Figure 1). Biventricular systolic function was preserved (ejection fraction 60%, end-diastolic volume 130 mL). An urgent angiocomputed-tomography (ACT) confirmed, also with three-dimensional rendering, the real expansion of the fusiform aneurysm. The mass involved the entire mediastinum, such as to displaced heart in a posterior position and crushed it on diaphragm. (Figure 2). Having assessed the life-threatening condition given by the enormous aneurysm size and the consequent increased risk of rupture, an emergency surgical approach became mandatory, thus a modified Cabrol operation was performed. At the time of surgery, right axillary artery and femoral vein were cannulated and cardiopulmonary bypass was established prior to open the sternum.

The choice of this surgical technique was modified intraoperatively, when the aneurysmal sac was transversally opened and approximately 1400 cc of blood were aspirated, because we observed that the distance between coronary artery ostia (CAO) and aortic annulus was less than 1.5 cm, aortic root was heavily calcified, CAO also were very dislocated, fixed and difficult to mobilized to perform a direct anastomosis on the aortic valved conduit. Assessed that anatomy of aortic annulus and CAO, distorted by the presence of the aneurysm, was unsuitable for the surgical technique of replacement with valved conduit and direct reimplantation of the coronary buttons on the graft and considering the risk of laceration and bleeding of conventional coronary artery anastomosis, a modified-Cabrol technique was adopted, in order to interpose two separate short 8 mm Dacron tubular grafts between CAO

and aortic valved conduit. The surgical procedure was performed without complications. Subsequently genetic tests were performed which did not reveal any mutations.

Despite a delayed awakening into intensive care unit, the patient had an uncomplicated post-operative course. On 16th post-operative day he was discharged home following an ACT examination which confirmed good functioning and positioning of the prosthesis and an excellent grafts patency, scheduling follow-up with ACT and TTE one, six and twelve months after surgery.

Discussion

An unruptured, asymptomatic GAAA is extremely rare in clinical practice. Initially they can develop subtly being asymptomatic, however, when excessive dimensions are reached, a variety of clinical manifestations can occur, including compressive symptoms such as dyspnea, dry cough, dysphagia, dysphonia and chest pain. Only two cases of unruptured and asymptomatic GAAA are reported in literature [1-6].

Because the risk of catastrophic rupture or dissection is proportional to the diameter of the aneurysm, aneurysmal size is the criterion for elective surgical repair. Nevertheless, operative mortality for GAAA remains high, especially when surgery is performed in an emergency basis and the aneurysmal size exceeds those recommended for surgery by guidelines, because GAAA present with an extreme clinical variability, it's difficult to establish standardized principles for their treatment, therefore it need to be tailored on an individual basis, adapting surgical strategy to variability of this pathology. Hence their surgical management is a technical challenge [7].

The modified Cabrol procedure has a smaller indication for aortic surgery, but in some particularly indicated cases, it may be the most appropriate choice. This technique still remains an important surgical procedure used as an option to treat widely spaced coronary buttons in aortic root surgery, however it is not usually applied as a first choice technique as its use is related to complications such as kinking or thrombosis of the graft, resulting in reduced graft patency.

The strengths of modified-Cabrol technique lay in its ability to provide a safe and tension-free anastomosis of the CAO to the aortic conduit when conventional reimplantation techniques fail to do so. The conditions that make use of modified-Cabrol anastomosis necessary are: poor mobilization of the CAO which can occur when ostia are less than 1.5 cm above the annulus, extreme aortic dilatation, friable or torn CAO that cannot be implanted with the conventional button approach, heavily calcified aortic root.

When CAO are very dislocated, fixed and difficult to mobilized to perform a direct anastomosis on the aortic valved conduit, modified- Cabrol procedure can be used to obtain a tension-free

anastomosis [8]. In our case all the conditions described were present; furthermore, the aortic annulus was strongly dilated and aortic valve was bicuspid, classifiable as type 0-lateral with no raphe. Although BAV is related to development of AAA, evidence of type 0-lateral BAV with insufficiency occurs in only 2% of cases, making it a very rare subcategory of BAV [9].

Conclusions

Despite the modified Cabrol technique may be considered obsolete, when the conventional button reimplantation technique is not feasible, it can be used as a bailout procedure that can be pulled by cardiac surgeons as a “trump card”, for complex aortic root replacements, in order to achieve tension-free anastomoses, limit bleeding and reduce development of suture-line pseudoaneurysms.

Considering that GAAAs can develop insidiously with extreme clinical variability, even in the absence of symptoms, and that their finding is usually incidental, this case also highlights the importance of not underestimating nonspecific symptoms such as dyspnea on exertion and to always deepen the evaluation of diastolic murmurs that may underlie BAV aortopathy, also investigating family medical history, even in young and healthy subjects without a clinical history of cardiovascular disease.

References

1. Shah P, Gupta N, Goldfarb I, Shamoan F. Giant dissecting aortic aneurysm in an asymptomatic young male. *Case Rep Vasc Med* 2015;2015:958464.
2. Yamashita T, Hayashi T, Tabata T, et al. Bicuspid aortic valve-associated aortic dilatation - what is the mechanism of bicuspid aortopathy?. *Circ J* 25;82:2470-1.
3. Michelena HI, Della Corte A, Evangelista A, et al. International consensus statement on nomenclature and classification of the congenital bicuspid aortic valve and its aortopathy, for clinical, surgical, interventional and research purposes. *J Thorac Cardiovasc Surg* 2021;162:e383-e414.
4. Isselbacher EM, Preventza O, Hamilton Black J 3rd, et al. 2022 ACC/AHA guideline for the diagnosis and management of aortic disease: a report of the American Heart Association/American College of Cardiology Joint Committee on clinical practice guidelines. *Circulation* 2022;146:e334-e482.
5. Di Michele S, Parato VM, Di Giannuario G, et al. Unlocking insights in bicuspid aortic valve management in adult patients: the vital role of cardiac imaging. *Monaldi Arch Chest Dis* 2023;94(1).

6. Okura T, Kitami Y, Takata Y, et al. Giant unruptured aneurysm of the thoracic aorta-a case report. *Angiology* 1999;50:865-9.
7. Pape LA, Tsai TT, Isselbacher EM, et al. Aortic diameter \geq 5.5 cm is not a good predictor of type A aortic dissection: observations from the International Registry of Acute Aortic Dissection (IRAD). *Circulation* 2007;116:1120-7.
8. Mossuto E, Milano A, Bortolotti U. The Cabrol technique for replacement of the aortic valve and totally calcified ascending aorta: a case report. *J Heart Valve Dis* 1994;3:98-100.
9. Sievers HH, Schmidtke C. A classification system for the bicuspid aortic valve from 304 surgical specimens. *J Thorac Cardiovasc Surg* 2007;133:1226-33.

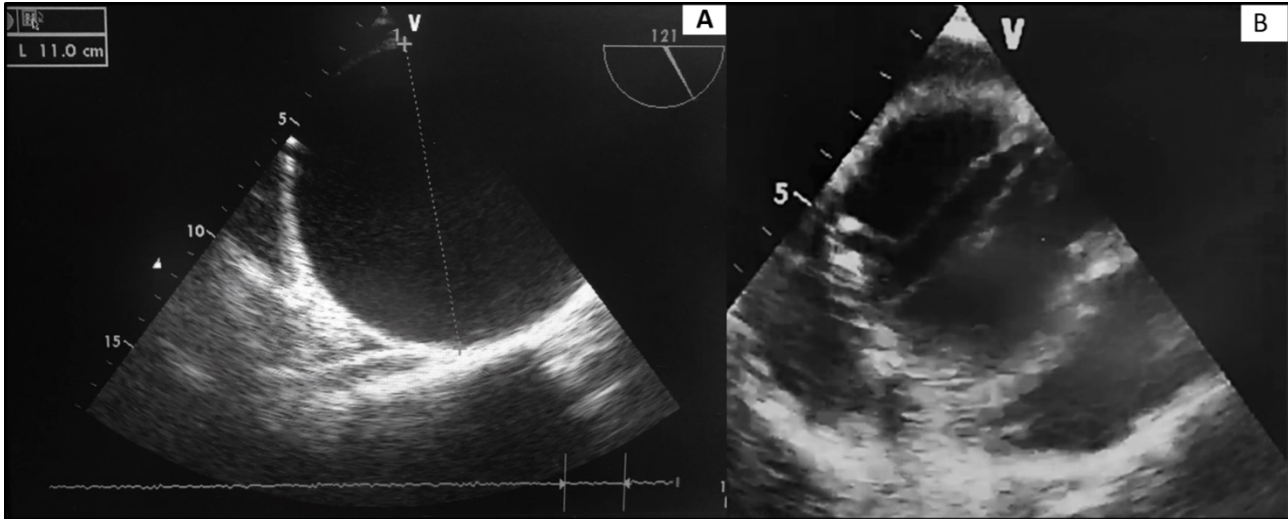


Figure 1. A) TEE in long axis aortic view showed GAAA (11 cm) parcelar calcifications of the aortic wall, in the absence of dissection and pericardial effusion; B) zoomed view of the aortic valve at 45° in short axis, showing "true" aortic valve bicuspid type 0-lateral, without raphe with moderate regurgitation jet. Presence of calcifications of the aortic ring.

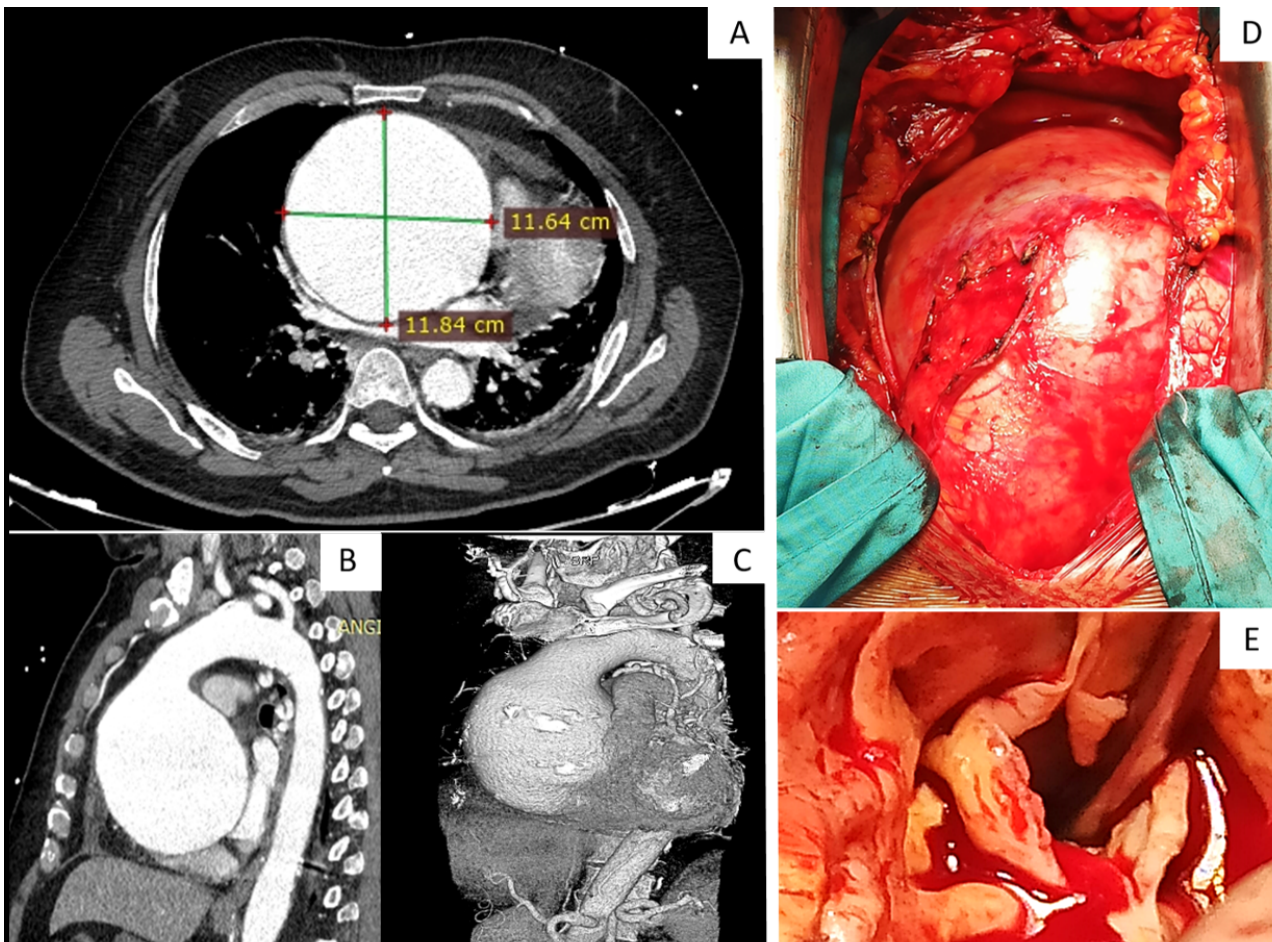


Figure 2. A) ACT Sagittal scan shows expansion of the aneurysm into the mediastinum; B) longitudinal scan; C) three-dimensional rendering shows that physiological anatomical relation are altered by the aneurysm, which has displaced heart into a more posterior-lateral position; D) surgical view after sternal opening, the aneurysm occupies the entire mediastinum, preventing the vision of the heart, which is crushed on the diaphragm; E) intraoperative view of the aortic valve, which is confirmed as bicuspid without raphe, with sclerotic and calcified cusps. The subtype 0-lateral is confirmed by viewing the right coronary ostium as this phenotype has one coronary artery arising from each sinus.