



Monaldi Archives for Chest Disease

eISSN 2532-5264

<https://www.monaldi-archives.org/>

Publisher's Disclaimer. E-publishing ahead of print is increasingly important for the rapid dissemination of science. The **Early Access** service lets users access peer-reviewed articles well before print / regular issue publication, significantly reducing the time it takes for critical findings to reach the research community.

These articles are searchable and citable by their DOI (Digital Object Identifier).

The **Monaldi Archives for Chest Disease** is, therefore, e-publishing PDF files of an early version of manuscripts that have undergone a regular peer review and have been accepted for publication, but have not been through the typesetting, pagination and proofreading processes, which may lead to differences between this version and the final one.

The final version of the manuscript will then appear in a regular issue of the journal.

E-publishing of this PDF file has been approved by the authors.

All legal disclaimers applicable to the journal apply to this production process as well.

Monaldi Arch Chest Dis 2024 [Online ahead of print]

To cite this Article:

Kedia Y, Madan M, Kaushik R, et al. **Thoracoscopic blood patch instillation for persistent air leak in pneumothorax: a case series and systematic review.** *Monaldi Arch Chest Dis* doi: 10.4081/monaldi.2024.2994

 ©The Author(s), 2024
Licensee [PAGEPress](#), Italy

Note: The publisher is not responsible for the content or functionality of any supporting information supplied by the authors. Any queries should be directed to the corresponding author for the article.

All claims expressed in this article are solely those of the authors and do not necessarily represent those of their affiliated organizations, or those of the publisher, the editors and the reviewers. Any product that may be evaluated in this article or claim that may be made by its manufacturer is not guaranteed or endorsed by the publisher.



Thoracoscopic blood patch instillation for persistent air leak in pneumothorax: a case series and systematic review

Yash Kedia,¹ Manu Madan,² Rajnish Kaushik,² Rohit Kumar,³ AJ Mahendran,²
Pranav Ish,² Neeraj Gupta,² Tanmaya Talukdar,² Nitesh Gupta²

¹Department of Pulmonary and Critical Care Medicine, VMMC and Safdarjung Hospital, New Delhi; ²Department of Pulmonary and Critical Care Medicine, VMMC and Safdarjung Hospital, Delhi; ³Department of Pulmonary Medicine, VMMC and Safdarjung Hospital, New Delhi, India

Correspondence: Nitesh Gupta, Department of Pulmonary Medicine, VMMC and Safdarjung Hospital, New Delhi - 110029, India.

Tel.: +91-0-98730 96364.

E-mail: niteshgupta2107@gmail.com

Contributions: YK, MM, RK, MAJ, PI, RK, NG, TT, NG, were involved in the literature search, planning, conduct, writing the original draft of the manuscript, and editing of the study; NG, is corresponding author and guarantor for all. All the authors have agreed with the submitted manuscript.

Conflict of interest: the authors declare that they have no conflicts of interest regarding the current study.

Ethics approval and consent to participate: not applicable. No ethical clearance is required for case series and systematic reviews.

Informed consent: written informed consent has been taken from all patients for publication of the data.

Funding: none.

Availability of data and materials: data available from the corresponding author upon request.

Abstract

Persistent air leaks in patients with pneumothorax can lead to significant morbidity. If a patient with persistent air leak is medically unfit for thoracic surgery, medical pleurodesis *via* chest tube or thoracoscopy is either an option. Thoracoscopy offers the advantage of visualizing the site of the air leak and enabling direct instillation of the pleurodesis agent or glue at that location. Autologous blood patch instillation *via* chest tube has been reported to be a cheap and very effective technique for the management of persistent air leaks. However, thoracoscopic blood patch instillation has not been reported in the literature. We report two cases of secondary spontaneous pneumothorax in which patients had persistent air leaks for more than seven days and were subjected to thoracoscopy to locate the site of the leak. In the same sitting, 50 mL of autologous blood patch was instilled directly at the leak site. Post-procedure, the air leak subsided in both patients, and the chest tube was removed with complete lung expansion. We also conducted a systematic review of the use of medical thoracoscopic interventions for treating persistent air leaks.

Key words: thoracoscopy, persistent air leak, autologous blood patch pleurodesis, pneumothorax.

Introduction

An air leak is defined as the flow of air into the pleural space, generally through a fistulous tract either alveolar-pleural fistula or bronchopleural fistula. Most air leaks resolve spontaneously with conservative treatment and the resolution of the underlying disease. However, in some cases, the leak may persist for a prolonged period, typically more than 5 to 7 days. This is known as a persistent air leak, and it can cause significant morbidity [1]. British Thoracic Society (BTS) 2023 recommends thoracic surgical consultation in case of persistent air leak, and if a patient is not considered fit for surgery, autologous blood pleurodesis or endobronchial therapies should be considered for the treatment of pneumothorax with a persistent air leak in adults [2]. Studies have shown that an autologous blood patch via the chest tube leads to faster healing of postoperative air leaks than conservative treatment [3]. Thoracoscopy provides the advantage of visualizing the site of the air leak and direct instillation of the agent at the site of the leak. As compared to video-assisted thoracic surgeries

(VATS), medical thoracoscopies can be done under moderate sedation with spontaneous ventilation. Combining the two techniques, i.e., autologous blood patch via thoracoscopy can be an effective and cheap method to seal air leaks and improve pneumothorax.

Case Report 1

A 52-year-old female from Nepal, a beedi smoker with a smoking history of 30 pack years, presented to the casualty department with complaints of shortness of breath. She had been classified as mMRC grade 1 for one year, which suddenly escalated to grade 4 over the last four hours. This was accompanied by a dry cough and left-sided chest pain. Upon examination, the patient exhibited tachypnea, tachycardia, and an oxygen saturation of 80% on room air. A chest X-ray revealed a pneumothorax on the left side, necessitating the insertion of a 20 French intercostal drainage (ICD) tube into the left pleural space.

The patient had a history of admission with a left-sided pneumothorax approximately one month before this presentation, which was also managed with ICD insertion and resolved within five days. Subsequently, the ICD was removed, and the patient was discharged. However, she experienced persistent air leaks for 12 days following the ICD insertion, resulting in a non-expanding lung (Figure 1). Consequently, she was scheduled for a thoracoscopy (Figure 2A, B, C) to visualize the site of the leak.

During the procedure, 200 ml of normal saline was instilled into the pleural cavity to confirm the site of the air leak, which was identified by observing the bubbling of air through the saline. The patient's position was adjusted to ensure that the site of the leak was in a dependent position. After suctioning out all the saline, a guide sheath was passed through the working channel of the thoracoscope. Subsequently, 50 ml of the patient's venous blood was instilled via the guide sheath at the site of the leak, and the patient remained in the same dependent position for about 5 minutes until a blood clot was visualized at the site of the leak. The thoracoscope was then removed, and the ICD was reinserted via the same port.

Following the procedure, the air leak subsided, and the patient experienced complete resolution of the pneumothorax within the next 48 hours. The ICD was clamped for 24 hours, and a repeat chest X-ray showed an expanded lung. To prevent the recurrence of pneumothorax, pleurodesis using betadine was performed, after which the ICD was removed. A post-ICD removal chest X-ray demonstrated a completely expanded lung (Figure 3). No complications were observed post-procedure.

Case Report 2

A 22-year-old male patient, a nonsmoker, presented with sudden-onset left-sided chest pain lasting for one day. On examination, the patient exhibited tachypnea, tachycardia, and an oxygen saturation of 95 percent on room air. A chest X-ray revealed a pneumothorax on the left side, necessitating the insertion of a 20 French intercostal drainage (ICD) tube into the left pleural space. A CT scan of the thorax (Figure 4) showed multiple bizarre-shaped cysts in bilateral lung fields with paraseptal emphysematous changes in addition to the pneumothorax. A bronchoscopy and transbronchial lung biopsy were performed with the intercostal tube in situ. The immunohistochemistry of the lung biopsy was positive for CD1a, S100, and langerin, confirming the diagnosis of Langerhans cell histiocytosis. Despite the presence of the ICD, the patient experienced persistent air leaks.

A thoracoscopy was subsequently performed, revealing multiple large cysts arising from the visceral pleura. Normal saline (250 ml) was instilled into the pleural cavity via the thoracoscope, and the site of the air leak was identified by observing the bubbling of air through the saline. The patient was positioned such that the site of the leak was in a dependent position. After suctioning out all the saline using the thoracoscope, a guide sheath was passed via the working channel, and 50 ml of the patient's blood was instilled at the site of bubbling via the guide sheath. The patient remained in the dependent position for about five minutes until a blood clot was visualized. The thoracoscope was then removed, and the ICD was reinserted via the same port. No complications occurred during the procedure.

Following the procedure, the air leak gradually subsided, and column movement persisted via the ICD. Once complete lung expansion was achieved, the ICD was clamped for 24 hours, and a repeat chest x-ray revealed a completely expanded lung. To prevent the recurrence of pneumothorax, pleurodesis using betadine was performed, after which the ICD was removed (Figure 5).

Discussion

Persistent air leaks, characterized by continuous airflow from the alveoli into the pleural space, pose challenges in the management of pneumothorax. The severity of these leaks is graded using the Cerfolio classification, ranging from grade 1, observed during forced expiration, to grade 4, with continuous bubbling present during both inspiration and expiration [4].

While surgical closure followed by pleurodesis is the recommended treatment for persistent air leaks lasting more than 5 to 7 days, recent guidelines from the British Thoracic Society

highlight the lack of consensus on the optimal management strategy [2,5]. For patients deemed unfit for surgery, options such as autologous blood pleurodesis or endobronchial therapies may be considered.

One such approach, autologous blood patch pleurodesis, involves injecting 50 to 100 mL of the patient's peripheral venous blood into the pleural cavity via a chest tube. Studies have demonstrated its efficacy, with success rates ranging from 78.3% to 85%, surpassing those of conservative management [6-9]. In a randomized controlled trial (RCT) conducted by Ibrahim et al., the success rate of autologous blood pleurodesis (50 ml) in the experimental group was 78.3%, compared to only 8.33% in the control group receiving conservative treatment [8]. Similarly, Cao et al., in their RCT, found that administering 1-2 ml/kg of autologous blood pleurodesis on Day 7 post-ICD insertion resulted in the resolution of air leaks in 82% of patients, compared to just 9% in the conservative treatment group by Day 13 [9]. A recent systematic review supported these findings, concluding that autologous blood patch significantly reduces the time to cessation of air leak without increasing the risk of complications such as infection, pain, or fever when compared to conservative management. Video-assisted thoracoscopic surgery (VATS)-guided bullectomy or surgical pleurodesis is commonly chosen as the primary treatment for persistent air leaks. Studies have indicated that VATS-guided stapling with pleurectomy [10], and bullectomy with partial pleurectomy are effective approaches for managing persistent air leaks [11]. Intraoperative use of fibrin sealants has also been explored to mitigate air leaks. In an RCT comparing the efficacy of absorbable fibrin sealant patch (AFSP) to standard surgical treatment in patients undergoing lobectomy, bilobectomy, or anatomical segmentectomy for lung cancer, AFSP demonstrated superiority over manual suturing as an adjunct to primary stapling in reducing intraoperative air leak intensity and the duration of postoperative air leak [12].

Use of medical thoracoscopic interventions for persistent air leaks has rarely been reported. We systematically searched the PubMed and Google Scholar databases for studies demonstrating the usefulness of medical thoracoscopy in managing persistent air leaks. We used the key search terms ("thoracoscopy" OR "pleuroscopy") AND ("persistent air leak" OR "persistent pneumothorax" OR "bronchopleural fistula" OR "alveolopleural fistula"). Through our search, we identified studies, case reports, and case series involving patients with pneumothorax and persistent air leaks who underwent medical thoracoscopy-guided management for their air leaks. Exclusion criteria included patients treated using video-assisted thoracoscopic surgeries (VATS), bronchoscopic interventions, pleurodesis, or other

interventions via a chest tube, as well as reports where thoracoscopic interventions were performed to prevent recurrence of pneumothorax rather than treat persistent air leaks. A total of 5193 searches were screened for eligibility as of 12/02/2024 (5010 on Google Scholar and 183 on PubMed). After screening abstracts and titles and applying our inclusion and exclusion criteria, we included 3 studies in the review. Figure 6 illustrates the flowchart used for article selection, and details of the included studies are presented in Table 1 [13-17]. Additionally, two more studies were included via cross-references.

The management of persistent air leaks encompasses various interventions, each with its level of effectiveness and potential complications. In a case report by Tschopp et al, a patient developed a persistent air leak following right upper lobe resection. Initial attempts to seal the leak via endobronchial fibrin glue failed, followed by an unsuccessful thoracoplasty. Ultimately, the leak was successfully closed by instillation of talc into the pleura via thoracoscopy (Tschopp et al, 1990) [13].

In a subsequent large prospective study by Tschopp et al, 89 patients with recurrent and persistent pneumothorax underwent thoracoscopic talc pleurodesis. A total of 93 procedures were performed, with 78 for recurrent pneumothorax and 15 for persistent air leaks. No serious complications were reported, although one patient required thoracotomy with pleurectomy, and nine cases required additional procedures. However, the authors did not provide a separate analysis for patients with persistent air leaks versus those with recurrent pneumothorax [14].

Györik S et al conducted an observational long-term follow-up study involving 63 patients with a primary spontaneous pneumothorax who underwent talc pleurodesis [15]. Of these patients, 68% underwent the intervention for recurrent pneumothorax, 29% for persistent air leaks, and 3% for immediate relief of symptoms. Over a mean follow-up duration of 118 months, 95% of the patients experienced successful pleurodesis, and no cases of acute respiratory failure were reported. However, three patients developed recurrent pneumothorax post-pleurodesis, all occurring at least 8 weeks after the procedure.

In a case report, thoracoscopy-guided external fibrin sealant application was utilized in an 80-year-old patient with chronic obstructive pulmonary disease (COPD) [16]. Initial attempts to seal the air leak with bronchoscopic autologous blood patch instillation failed twice. Subsequently, a thoracoscopy was performed, and 20 mL of fibrin sealant successfully sealed the air leak. Doxycycline pleurodesis was then performed to prevent pneumothorax recurrence [16].

Another series of three patients with COPD and multiple bullae underwent thoracoscopy-guided argon plasma coagulation (APC) to shrink the bullae. Autologous blood patch instillation via chest tube successfully resolved persistent air leaks in two patients, while the third patient's leak subsided completely with APC alone [17].

We hypothesized that combining autologous blood patch and thoracoscopy could lead to higher success rates in patients with persistent air leaks. Additionally, autologous blood patch may offer a cost-effective alternative to talc pleurodesis. In our cases, thoracoscopy-guided localization of the air leak allowed for precise instillation of autologous blood, resulting in rapid resolution of pneumothorax and early removal of intercostal drainage (ICD). While this approach holds promise, limitations include challenges in visualizing the leak site in all patients and difficulty in achieving a dependent position in certain cases. Nevertheless, for patients where the leak is identified and a dependent position can be achieved, autologous blood patch via thoracoscopy may prove to be an effective technique for sealing air leaks in persistent cases.

Conclusions

Medical thoracoscopy is a powerful tool in patients with unresolved pleural diseases. Thoracoscopy-guided autologous blood patch instillation could be an effective method to resolve persistent air leaks in patients with pneumothorax.

References

1. Dugan KC, Laxmanan B, Murgu S, Hogarth DK. Management of persistent air leaks. *Chest* 2017;152:417-23.
2. Roberts ME, Rahman NM, Maskell NA, et al. British Thoracic Society guideline for pleural disease. *Thorax* 2023;78:s1-42.
3. Karampinis I, Galata C, Arani A, et al. Autologous blood pleurodesis for the treatment of postoperative air leaks. A systematic review and meta-analysis. *Thorac Cancer* 2021;12:2648-54.
4. Cerfolio RJ. Advances in thoracostomy tube management. *Surg Clin North Am* 2002;82:833-48.
5. Baumann MH, Strange C, Heffner JE, et al. Management of spontaneous pneumothorax: an American College of Chest Physicians Delphi consensus statement. *Chest* 2001;119:590-602.

6. Lang-Lazdunski L, Coonar AS. A prospective study of autologous "blood patch" pleurodesis for persistent air leak after pulmonary resection. *Eur J Cardiothorac Surg* 2004;26:897-900.
7. Robinson CL. Autologous blood for pleurodesis in recurrent and chronic spontaneous pneumothorax. *Can J Surg* 1987;30:428-9.
8. Ibrahim IM, Elaziz MEA, El-Hag-Aly MA. Early autologous blood-patch pleurodesis versus conservative management for treatment of secondary spontaneous pneumothorax. *Thorac Cardiovasc Surg* 2019;67:222-6.
9. Umar Z, Nassar M, Ashfaq S, et al. The efficacy and safety of autologous blood patch for persistent air leaks: a systematic review and meta-analysis. *Cureus* 2023;15:e36466.
10. Majeed FA, Khan YS, Raza A, et al. Video assisted thoracoscopic management of primary spontaneous pneumothorax. *J Pak Med Assoc* 2021;71:210-4.
11. Fung S, Kivilis M, Krieg A, et al. Video-assisted thoracoscopic surgery with bullectomy and partial pleurectomy versus chest tube drainage for treatment of secondary spontaneous pneumothorax-a retrospective single-center analysis. *Medicina (Kaunas)* 2022;58:354.
12. Lopez C, Facciolo F, Lequaglie C, et al. Efficacy and safety of fibrin sealant patch in the treatment of air leakage in thoracic surgery. *Minerva Chir* 2013;68:559-67.
13. Tschopp JM, Évéquoz D, Karrer W, et al. Successful closure of chronic BPF by thoracoscopy after failure of endoscopic fibrin glue application and thoracoplasty. *Chest* 1990;97:745-6.
14. Tschopp JM, Brutsche M, Frey JG. Treatment of complicated spontaneous pneumothorax by simple talc pleurodesis under thoracoscopy and local anaesthesia. *Thorax* 1997;52:329-32.
15. Györik S, Erni S, Studler U, et al. Long-term follow-up of thoracoscopic talc pleurodesis for primary spontaneous pneumothorax. *Eur Respir J* 2007;29:757-60.
16. Holtzclaw A, McKay S, Mullenix P, Browning R. Novel treatment of a refractory alveolopleural fistula using medical pleuroscopy. *J Bronchology Interv Pulmonol* 2021;28:e4-7.
17. Zhang L, Xie T, Fu Y, Wu H. Assessment and review of treatment for secondary spontaneous pneumothorax using medical thoracoscopy-assisted argon plasma coagulation in association with autologous blood pleurodesis. *Ther Adv Respir Dis* 2021;15:1753466620986390.

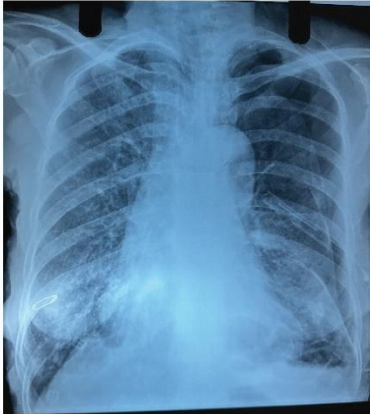

Figure 1. Chest X-ray after 12 days of intercostal drainage (ICD) insertion s/o left-sided pneumothorax with ICD *in situ*.

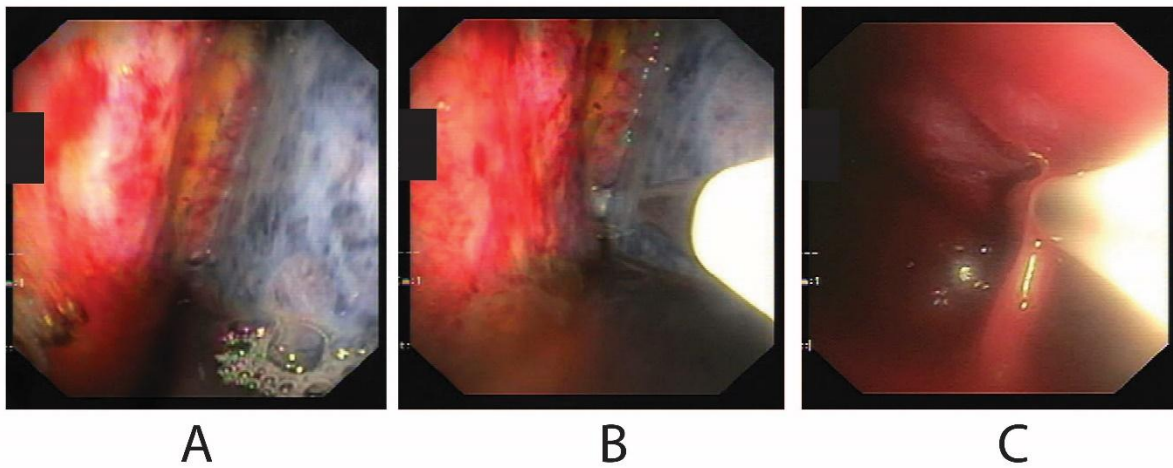


Figure 2. Thoracoscopy images. A) Bubbling visualized after instilling normal saline; B) guide sheath passed through the working channel of the thoracoscope; C) blood patch instilled at the site of the leak.

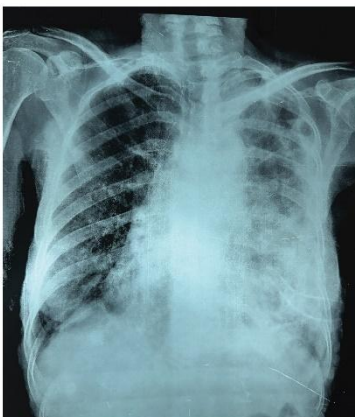

Figure 3. Chest X-ray after complete lung expansion and removal of intercostal drainage.

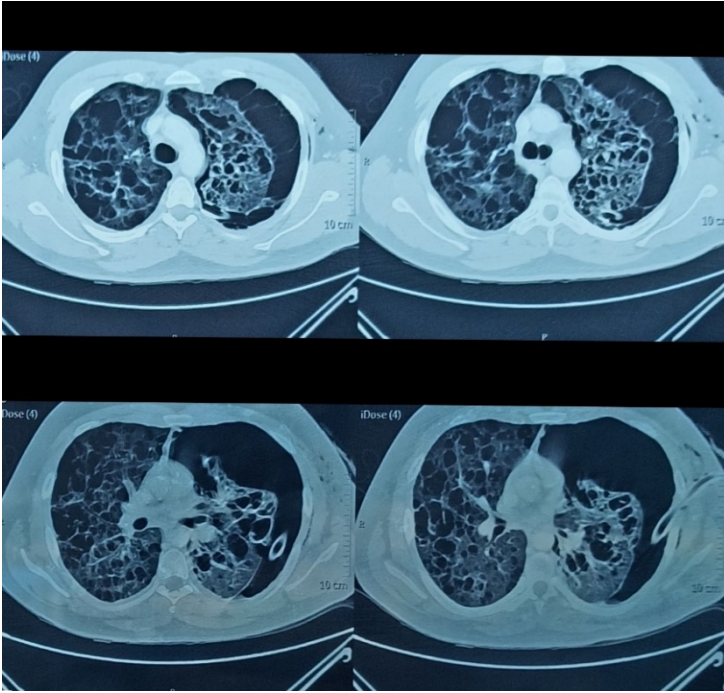


Figure 4. Computed tomography scan of thorax. Multiple bizarre-shaped cysts in bilateral lung fields with para septal emphysematous changes, pneumothorax on left, and intercostal drainage tube *in situ*.

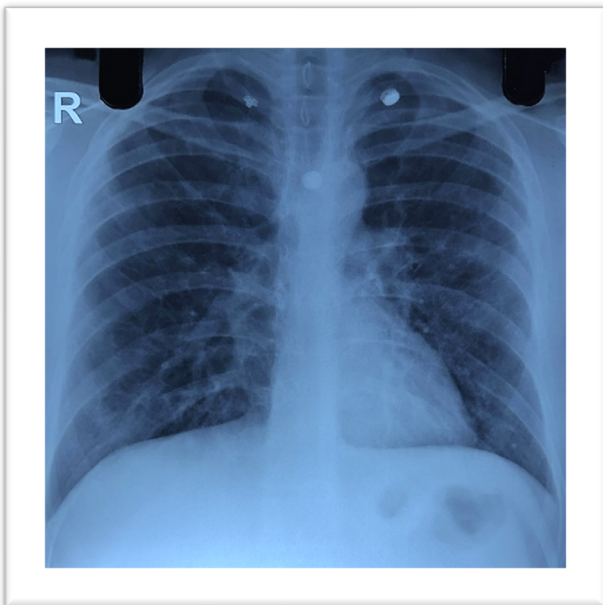


Figure 5. Chest X-ray after removal of intercostal drainage suggestive of completely expanded lung.

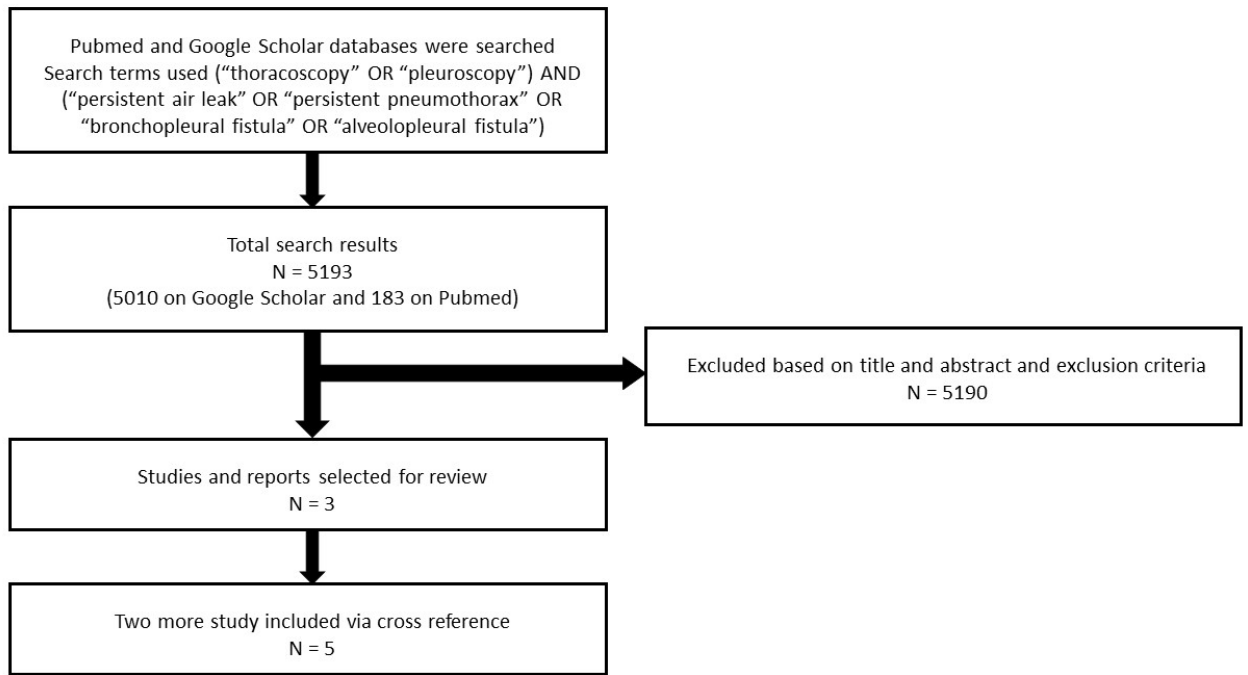


Figure 6. Studies evaluated for the systemic review.

Table 1. Details of studies demonstrating the usefulness of medical thoracoscopy interventions for persistent air leaks.

Author	Study type	Number of patients	Intervention done	Outcome and Complications
Tschopp <i>et al.</i> (1990) [13]	Case report	1	Thoracoscopic talc instillation	Successful resolution of air leak
Tschopp <i>et al.</i> (1997) [14]	Prospective study	89 (93 thoracoscopies - 78 for recurrent pneumothorax, 15 for persistent air leak)	Thoracoscopic talc instillation	1 patient required thoracotomy with pleurectomy, 9 cases required a second procedure, 3 cases required surgical procedure. No serious complications like empyema or re-expansion pulmonary edema or death
Györik <i>et al.</i> (2007) [15]	Observational, long term follow up study	63	Thoracoscopic talc pleurodesis	95% had successful resolution of air leak, 5% required surgical interventions. No episodes of acute respiratory distress post pleurodesis
Holtzclaw <i>et al.</i> (2021) [16]	Case report	1	Thoracoscopic external fibrin sealant application	Successful resolution of air leak. The patient expired after three months (cause unrelated to the procedure)
Zhang <i>et al.</i> (2021) [17]	Case report	3	Argon plasma coagulation (APC) via thoracoscopy to shrink subpleural bullae, followed by autologous blood patch instillation via chest tube	Successful resolution of air leak. No reported complications