

# Managing venous thromboembolic events in daily practise: "time is never enough"

D. Anyfantakis<sup>1</sup>, E.K. Symvoulakis<sup>2</sup>, I. Mitrouska<sup>3</sup>

**ABSTRACT:** *Managing venous thromboembolic events in daily practise: "time is never enough". D. Anyfantakis, E.K. Symvoulakis, I. Mitrouska.*

Pulmonary embolism is an insidious life-threatening condition. Its diagnosis represents a challenging topic in daily clinical practice since the recognition and the appro-

priate management of the condition can lead to the decrease of potentially fatal consequences. We present a clinical case which highlights the necessity for an increased level of 'surveillance' from the involved physicians since features of thromboembolic events may be elusive or vague. *Monaldi Arch Chest Dis 2009; 71: 2, 66-68.*

*Monaldi Arch Chest Dis 2009; 71: 2, 00-00.*

**Key words:** *Chest discomfort, Pulmonary embolism, Diagnosis, Clinical information.*

<sup>1</sup> University General Hospital of Heraklion,

<sup>2</sup> Blood Donation Department, University General Hospital of Heraklion,

<sup>3</sup> Department of Thoracic Medicine, University General Hospital of Heraklion, Greece.

Correspondence: Emmanouil K. Symvoulakis, Blood Donation Department, University General Hospital of Heraklion, Voutes, 71110, Heraklion, Crete, Greece; e-mail: symvouman@yahoo.com

Pulmonary embolism (PE) is a severe clinical problem with consistent rates of mortality and recurrence. Sudden death is the initial clinical manifestation in a quarter of the patients having an episode of PE [1]. As a diagnosis, it is commonly overlooked due to atypical manifestations [2], which easily can be attributable to a variety of clinical disorders including pneumonia, asthma, myocardial infarction, rib fracture, pneumothorax, musculoskeletal pain and others [3]. Genetic and acquired factors can mutually interact and lead to a synergic increase of the occurrence of venous thromboembolism (VTE) [4]. For instance, the presence of both hyperhomocysteinemia and factor V Leiden may result in a multi-fold risk augmentation for thromboembolic manifestations [5]. Infections can further trigger thromboembolic events [6].

## Case Report

We report information from a case of a 34-year old male, with a 20-pack-year history of cigarette smoking, who attended the department of Thoracic Medicine of the University General Hospital of Heraklion reporting symptoms as breathlessness sensation, sharp pleuritic pain during deep inspiration, tachypnoea and anxiety.

A positive history of chest complaints was described. A left-sided, limited pleural effusion was detected by CT scanning five years ago (figure 1A). At that time the main symptom was chest pain during deep inspiration. Thoracentesis was not performed. Immunologic screening was negative. Mantoux testing and sputum examination were not

diagnostically useful. A double antibiotic regimen was administered. Pleural effusion was attributed to a previous lower respiratory infection and the episode was self-limited. Six months before the current episode, a diagnosis of community acquired pneumonia was formulated. Fever and fatigue were the main clinical manifestations. A right middle lobe infiltrate was visualised on the chest x-ray. Pneumonia was successfully treated. Three weeks later and since then, the patient experienced episodes of insistent, vague right-sided chest discomfort and periodic pleural friction rub sensation during deep inspiration, occurring repeatedly and having unexplained remissions. Chronicity of these symptoms, remissions and absence of any radiologic findings led to diagnostic uncertainty and the symptoms were finally overlooked. Periodic use of anti-inflammatory agents was reported.

During the current episode, heart rate was 100 beats/min, blood pressure 145/90 mmHg, respiratory rate 23 breaths/min and body temperature 37.2 °C. Pulmonary examination disclosed diminished breath sounds and dullness to percussion over the right costophrenic angle. The oxygen saturation was 94% while the patient was breathing ambient air.

Cardiac sounds were normal with no murmurs. The ECG revealed a sinus rhythm. Cardiac biomarkers were negative and cardiac ultra-sound was normal. Due to a variety of reasons such as clinical signs of pleural effusion, young age, recent history of pneumonia, the patient was immediately referred for CT scanning. CT thoracic scan demonstrated a large amount of pleural effusion on the

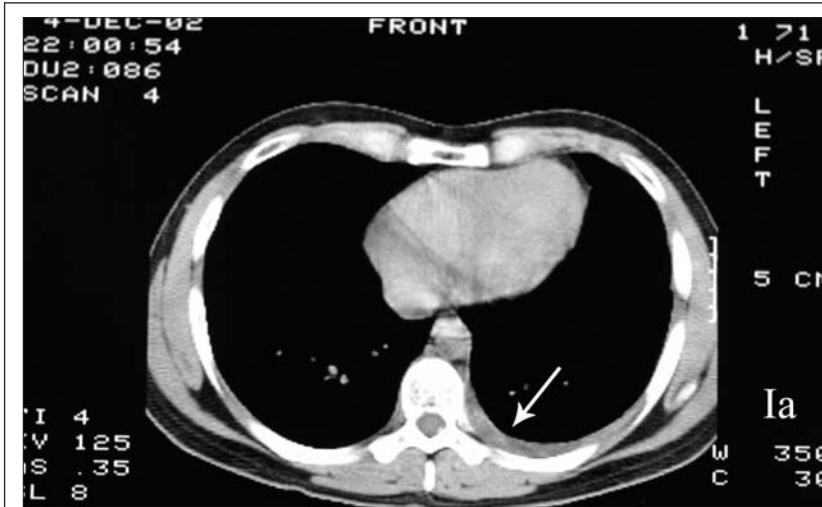


Fig. 1A. - CT scan showing the presence of pleural effusion on the left hemithorax (in 2002).

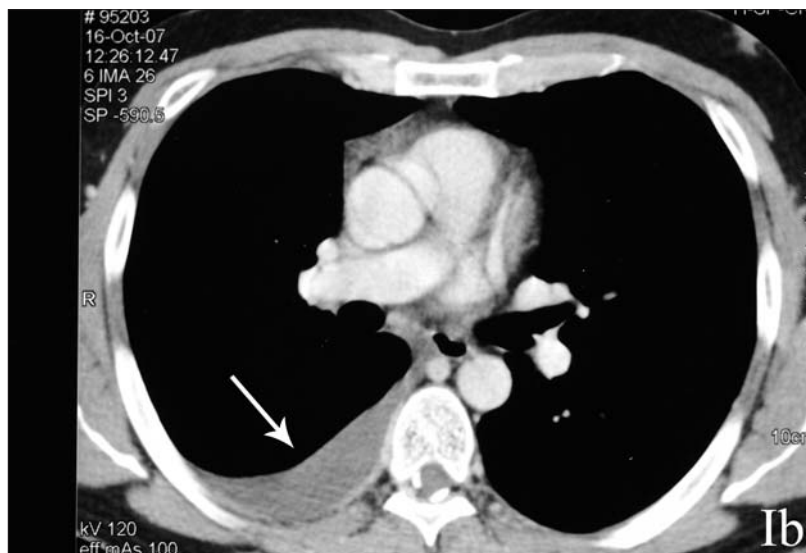


Fig. 1B. - CT scan showing the presence of a pleural effusion on the right hemithorax (in 2007).

right hemithorax (figure 1B). Although usually not to be encouraged in the diagnosis of pulmonary embolism, diagnostic thoracentesis was performed and removed approximately 200 ml of exudative eosinophilic pleural fluid (Polymorfonuclears: 22%, Lymphocytes: 32%, eosinophils: 38%, mononuclear cells: 8%). An elevated serum homocysteine (26  $\mu\text{mol/L}$ , cut off: 11  $\mu\text{mol/L}$ ) was measured. An elevated D-dimer level (2.7  $\mu\text{g/ml}$ , range: 0-0,5  $\mu\text{g/ml}$ ) supported the suspicion of pulmonary embolism (PE). In view of these findings, spiral CT was performed revealing the presence of thrombus within the subsegmental branches of the right descendent pulmonary artery confirming the diagnostic hypothesis. Low-molecular-weight-heparin was initially administered. Subsequently, oral anticoagulation therapy was commenced with acenocoumarol aimed at maintaining an International Normalised Ratio (INR) between 2 and 3. Inherited risk factors for venous thromboembolic events (VTE) were identified. Genetic analyses demonstrated heterozygosis for factor V Leiden and homozygosis for the C677T mutation in the methylenetetrahydrofolate reductase (MTHFR)

gene. Folic acid, B6 and B12 supplements were added in the treatment regimen and smoking cessation was strongly recommended.

### Discussion

A recent study reported that acute infections may have a role in triggering thromboembolic events, and should be considered as related precipitant factors [6]. Recent patient's medical history fairly suggests that pneumonia and the subsequent thromboembolic 'phenomena' cannot be explained as coincidental or independent clinical events. Additionally, one out of five cases of pulmonary embolism is attributed to heredity [3]. A single point mutation in the gene encoding coagulation factor V (G1691A, where adenine replaces guanine), called factor V Leiden, is the most common genetic abnormality associated with VTE [7]. Genetic analyses confirmed high frequencies of geographic distribution of factor V Leiden in Europe with preponderance in Greece [7]. A 15% carrier rate has been reported among Greeks [7]. In this case a possible synergic thrombophilic interaction defined an enhanced susceptibility to VTE. A negative family history of thrombotic events may mask an existent thrombophilic genetic background. Current evidence suggests that unselected screening is unsuitable and should be avoided [8]. However, a selective screening

approach, based on assessment of family and personal VTE history, may improve cost-effectiveness [9].

Pleuritic pain is a well-recognised feature of PE clinical presentation [2]. In the presented case, the atypical chronic course of a vague chest painful discomfort and the absence of major environmental predisposing factors led to a low suspicion for PE. A similar episode of chest pain and pleural effusion supports the eventuality of a misdiagnosed thromboembolic event five years ago. Taking the opportunity offered from this case, we believe that the insidious nature of PE, regardless of age, requires increased vigilance from the involved physicians, especially in the presence of "red flag" symptoms, even subacute or vague, and when other reasonable explanations for them are lacking. PE represents a challenge in daily clinical practice since prevention, correct diagnosis and appropriate treatment of the episodes are factors, which can drastically reduce the overall mortality and morbidity burden of the disease. Life-threatening conditions rarely allow diagnostic revisions. Thus, PE outcomes should be seen as indirect 'quality indicators' of an efficient healthcare provision.

## References

1. Heit JA. The epidemiology of venous thromboembolism in the community: implications for prevention and management. *J Thromb Thrombolysis* 2006; 21: 23-9.
2. Stein PD, Terrin ML, Hales CA, *et al.* Clinical, laboratory, roentgenographic, and electrocardiographic findings in patients with acute pulmonary embolism and no preexisting cardiac or pulmonary disease. *Chest* 1991; 100: 598-603.
3. Goldhaber SZ. Pulmonary embolism. *N Engl J Med* 1998; 339: 93-104.
4. Rosendaal FR. Venous thrombosis: a multicausal disease. *Lancet* 1999; 353:1167-73.
5. Ridker PM, Hennekens CH, Selhub J, Miletich JP, Malinow MR, Stampfer MJ. Interrelation of hyperhomocysteinemia, factor V Leiden, and risk of future venous thromboembolism. *Circulation* 1997; 95: 1777-82.
6. Smeeth L, Cook C, Thomas S, Hall AJ, Hubbard R, Vallance P. Risk of deep vein thrombosis and pulmonary embolism after acute infection in a community setting. *Lancet* 2006; 367: 1075-9.
7. Rees DC, Cox M, Clegg JB. World distribution of factor V Leiden. *Lancet* 1995; 346: 1133-4.
8. Haemostasis and Thrombosis Task Force, British Committee for Standards in Haematology. Investigation and management of heritable thrombophilia. *Br J Haematol* 2001; 114: 512-28.
9. Wu O, Greer IA. Is screening for thrombophilia cost-effective? *Curr Opin Hematol* 2007; 14: 500-3.



Pavia - Almo Collegio Borromeo