

Co-existence of organising pneumonia in a patient with *Mycobacterium Avium Intracellulare* pulmonary infection

R.M. Jones, A. Dawson, E.N. Evans, N.K. Harrison

ABSTRACT: *Co-existence of organising pneumonia in a patient with Mycobacterium Avium Intracellulare pulmonary infection. R.M. Jones, A. Dawson, E.N. Evans, N.K. Harrison.*

Non-tuberculous mycobacterias (NTMs) have many clinical manifestations in humans, depending on the underlying immunological status. We present a patient with *Mycobacterium avium intracellulare* pulmonary infection

and co-existing, biopsy proven non-granulomatous organising pneumonia in distinct regions within the lungs. Treatment consisting of anti-mycobacterial therapy and corticosteroids led to clinico-radiological resolution. This case represents a potential broader clinico-pathological manifestation of *Mycobacterium avium intracellulare*.
Monaldi Arch Chest Dis 2009; 71: 2, 76-80.

Keywords: *Mycobacterium avium intracellulare, Organising pneumonia.*

Correspondence: Dr. R. Mathew Jones, MBBCh, MRCP. Respiratory Unit, Morriston Hospital, Swansea, SA6 6NL, Wales, United Kingdom; e-mail: drmatjones@hotmail.com

Introduction

Mycobacterium avium intracellulare (MAI) is a ubiquitous, saprophytic organism commonly isolated from water and soil. Only a minority of people exposed to the organism develop clinical infection which is usually because of cavitating lung disease or immunosuppression [1]. Organising pneumonia is a non-specific inflammatory process characterised pathologically by the presence of buds of granulation tissue in the distal air spaces [2]. There are numerous causes of organising pneumonia including acute respiratory infections, drugs and radiotherapy. It may also occur in association with connective tissue diseases or appear in isolation when it is known as cryptogenic organising pneumonia (COP) [3].

We present a patient with emphysema who developed MAI infection in the left upper lobe with coexistent bilateral lower lobe consolidation which was subsequently proven to be organising pneumonia.

Case Report

A 58-year-old woman attended the chest clinic with a 2 month history of progressive breathlessness, cough productive of green sputum, lethargy and nausea. She had lost 12 kg in weight over the preceding 6 months. She had a past history of chronic obstructive pulmonary disease (COPD), hypertension, transient ischaemic attacks and coronary artery disease. There were no risk factors for HIV. She gave a 30 pack-year smoking history.

She was a housewife, did not drink alcohol and had no pets or any recent relevant environmental exposure.

Physical examination was unremarkable apart from signs of hyperinflation consistent with emphysema. A chest radiograph demonstrated cavitating left upper zone consolidation and bilateral basal opacities. Blood tests revealed a mild neutrophilia of $11.7 \times 10^9/l$ (normal, $3.6-9.2 \times 10^9/l$) and raised ESR of 67mm/h. Chest computed tomography (CT) scan confirmed cavitating consolidation at the left apex with widespread emphysema (figure 1) and bilateral lower lobe consolidation with air bronchograms (figure 2).

Sputum culture and subsequent specific nucleic acid probes were positive for *Mycobacterium avium complex* (AccuProbe system, Gen-Probe, San Diego). The organism was later identified on multiple cultures and conventional phenotypic methods as MAI.

Due to uncertainty regarding the nature of the lower lobe consolidation, the patient underwent bronchoscopy which demonstrated no endobronchial abnormalities apart from collapsible airways typical of emphysema. Transbronchial lung biopsies (TBLB) and bronchial washings of the left lower lobe were performed.

Histological evaluation revealed evidence of inflamed, ciliated bronchial epithelium with alveolar spaces obliterated by a polypoid cellular combination of fibroblasts, inflammatory cells and foamy macrophages typical of organising pneumonia (OP). No granulomas were seen and stains for Acid Alcohol Fast Bacilli and fungal elements were negative (figure 3).

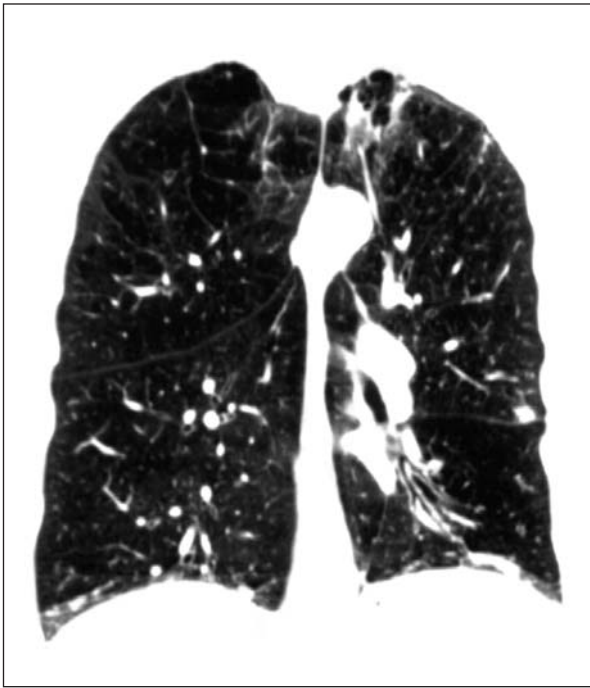


Fig. 1. - Chest CT coronal section demonstrating left upper lobe cavitation on a background of severe emphysema.

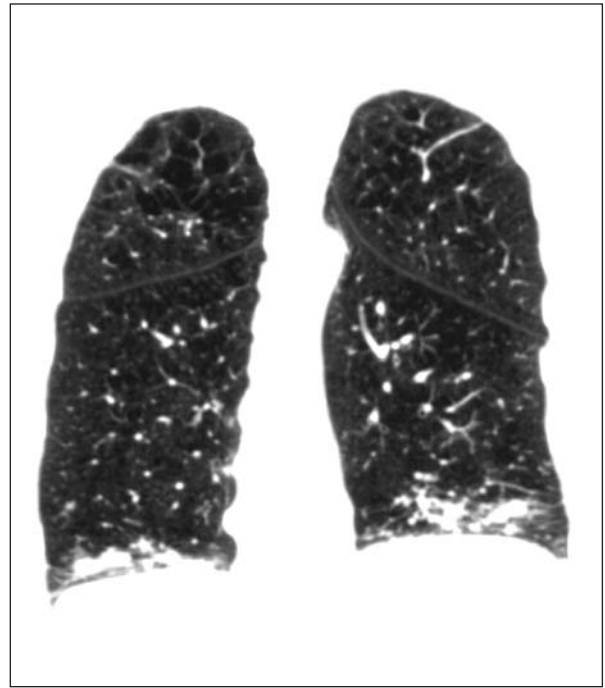


Fig. 2. - Further chest CT coronal section showing bilateral lower lobe alveolar opacities with air bronchograms present on the left.

No infective organisms were cultured from the lower lobe washings. Anti-mycobacterial therapy consisting of rifampicin (600 mg/day) and ethambutol (15 mg/kg/day) was commenced. Macrolides and quinolones were avoided, due to intractable nausea and tendonitis respectively when taken previously. Review of her current medication revealed no drugs implicated in causing OP. In view of the biopsy findings, prednisolone 40 mg/day (0.75 mg/kg) was commenced concurrently. Five weeks later, her symptoms and serum inflammatory markers had improved significantly. A repeat chest radiograph showed partial resolution of the basal opacities. Sputum cultures four months following commencement of therapy were negative for *MAI*. The prednisolone dose was reduced gradually over the course of six months, to a maintenance dose of 10 mg/day. Anti-mycobacterial chemotherapy was withdrawn after 18 months treatment. Two years following diagnosis, she remained clinically in remission and her chest radiograph showed complete resolution of the opacification at both lung bases.

Discussion

We report a patient with emphysema who developed *MAI* pulmonary infection and co-existing organising pneumonia in remote parts of the lung. This association has been reported only twice and in neither case was organising pneumonia in anatomically distinct areas of the lungs [4, 5].

MAI has variable clinical manifestations depending on the immunological status of individual patients. Common symptoms include insidious

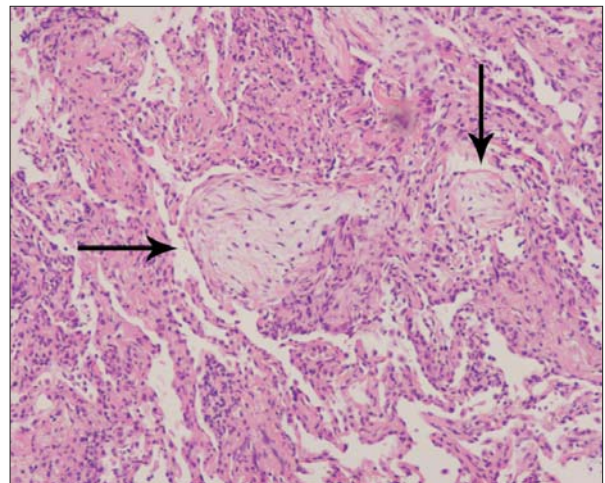


Fig. 3. - Transbronchial lung biopsy specimen from left lower lobe. Intra-alveolar obliteration (arrowed) with buds of fibroblastic tissue in a myxoid matrix of inflammatory cells including macrophages, known as Masson bodies or *Bourgeons conjunctifs*. Adjacent parenchymal chronic inflammatory cell infiltrate is seen (haematoxylin-eosin stain, original x 40).

cough, sputum production, weight loss, malaise, haemoptysis and breathlessness [6]. Patients are usually older and more likely to have underlying lung disease, principally COPD, compared with *Mycobacterium tuberculosis* infection [1].

MAI has been found in association with other interstitial lung diseases. A recent series described reactions similar in clinico-radiological nature to hypersensitivity pneumonitis. This disease manifestation extends from the organism's ability to colonize natural water sources and systems such as those used for hot tubs [7]. These presentations have components of parenchymal inflammation

and infection which differ from other *MAI* infections [8]. Histological examination from lung biopsies in these patients displayed a granulomatous bronchiolitis in association with numerous non-caseating granulomata within the lung parenchyma [9] and is thus a different clinical entity from the pattern of organising pneumonia in our patient.

OP is a non-specific repair process seen in a variety of clinical settings. It has been reported secondary to numerous infectious agents (table 1). Other secondary associations include several connective tissue and autoimmune diseases, vasculitides, various drugs, malignancies (especially haematological) and lung radiotherapy [3].

In cases where no underlying association is found, the OP is termed cryptogenic. Cryptogenic organising pneumonia (COP) was originally described by Davison in 1983 [10]. It is unclear whether COP and secondary OP represent a single disease entity or separate, albeit clinically related conditions.

Symptoms of COP are insidious and non-specific and include a dry cough, mild dyspnoea on exertion, lethargy, fever and weight loss – symptoms which overlap with those of non tubercular mycobacteria pulmonary infection. [11]. Typical radiographic findings of COP and secondary OP are patchy bilateral peripheral alveolar opacities,

often flitting in locality [11, 12]. Chest CT scans principally show focal subpleural consolidation and ground glass shadowing is commonly present. Small (<10 mm) bronchocentric nodules are occasionally seen.

The histopathological hallmark of OP is patchy cellular fibrosis, principally within alveoli and less commonly within the distal bronchiolar lumen (bronchiolitis obliterans) [2]. Foamy macrophages are commonly seen in adjacent alveoli and a mild interstitial infiltrate is often present. To make a diagnosis, it is imperative that the pattern of OP is prominent and not an accessory finding in association with another well defined idiopathic interstitial pneumonia.

OP is commonly seen adjacent to areas of infection, tumour or other fibrosing interstitial lung diseases. A TBLB may give insufficient information to enable confident exclusion of secondary processes [13, 14]. In an appropriate clinico-radiological setting, TBLB may be sufficient for diagnosis. Careful multi-disciplinary evaluation to distinguish COP and secondary OP is important as prognosis in terms of treatment response and survival is worse with secondary OP.

Corticosteroids are currently the standard therapy for both variants of OP [15] although spontaneous remission is known to occur. Recent British Thoracic Society (BTS) guidelines recommend initial doses of prednisolone 0.75-1 mg/kg, weaning over 12 months [15]. Clinical response is frequently dramatic, with improvement within 48 hours of therapy, whilst radiographic improvement usually lags behind by several weeks. However, relapse is common as corticosteroid doses are reduced but seldom occurs when the maintenance dose of prednisolone exceeds 20 mg/day.

To our knowledge, the association of organising pneumonia with *MAI* has been reported only twice [4, 5]. Marchevsky and colleagues reported a 65-year-old lady who presented with multiple discrete infiltrates on chest x-ray with concurrent *MAI* and organising pneumonia on biopsy from a single apical site. Similarly, Hamada *et al* recently reported a 67-year-old woman with no pre-existing lung disease who presented with simultaneous *MAI* infection and organising pneumonia in the same lobar segment [5]. The patient was treated initially for nine months with tapering dosages of corticosteroids only but subsequently relapsed, requiring 18 months of anti-mycobacterial therapy. Omission of anti-mycobacterial therapy led to prolonged and recurrent symptoms, suggesting that *MAI* infection was the principal disease.

Our patient was treated according to existing BTS Guidelines with Rifampicin and Ethambutol [16]. Newer therapeutic regimens for *MAI* infection, such as those endorsed by the American Thoracic Society [6], include the macrolides clarithromycin or azithromycin, which have in vitro and clinical activity against the organism and are concentrated in phagocytes and within the lungs [17, 18]. However, a recent multicentre, prospective, randomised open-label trial conducted by

Table 1. - Infections associated with organising pneumonia

- Bacterial
 - *Burkholderia cepacia*
 - *Chlamydia pneumoniae*
 - *Coxiella burnetii*
 - *Legionella pneumophila*
 - *Mycoplasma pneumoniae*
 - *Nocardia asteroides*
 - *Pseudomonas aeruginosa*
 - *Serratia marcescens*
 - *Staphylococcus aureus*
 - *Streptococcus pneumoniae*
- Viruses
 - Adenovirus
 - Cytomegalovirus
 - Human herpes virus-6 and 7
 - Human Immunodeficiency Virus
 - Influenza
 - Parainfluenza
 - Respiratory syncytial virus
- Parasites
 - *Dirofilaria immitis*
 - *Plasmodium vivax*
- Fungi
 - *Cryptococcus neoformans*
 - *Penicillium janthinellum*
 - *Pneumocystis jiroveci*

the Research Committee of the BTS failed to demonstrate any additional mortality benefit of Clairthormycin when added to Rifampicin and Ethambutol compared to these two agents in combination [19].

Macrolides have also been used with success to treat cases of organising pneumonia, either as monotherapy or as adjuvants to corticosteroid treatment, due to their immunomodulatory and anti-inflammatory effects [20, 21]. Macrolides have a direct immunosuppressive effect on neutrophil and T-cell function, decreasing the production of interleukin-8, IL-1 β , tumour necrosis factor and inhibiting neutrophil oxidation bursts - factors which underlie their utility in the treatment of these diseases [22, 23].

The potential mechanisms by which *MAI* and OP are associated are interesting. *MAI* is known to induce the production of cytokines such as interleukin-8 which is increased in bronchoalveolar lavage fluid of patients with *MAI* infection [24]. Furthermore, *MAI* adheres to fibronectin at areas of denuded extracellular matrix in the respiratory mucosa via fibronectin attachment protein [25]. It has been reported that both interleukin-8 and fibronectin genes undergo increased expression in COP, suggesting a role for cytokine activation by alveolar macrophages in the inflammatory process [26]. Thus *MAI* may act as a trigger for organising pneumonia as in the reported case, although why this would occur in remote areas of the lung is not clear.

In conclusion, we report a patient with emphysema who developed simultaneous OP and fibrocavitary *MAI* infection in remote areas of the lung. Treatment with corticosteroids and anti-mycobacterial therapy led to a complete clinical response. Multiple discrete infiltrates in combination with *MAI* infection in the appropriate clinical context should arouse suspicion of concurrent organising pneumonia. The likely underlying immunopathology provides a rationale for the concurrent use of anti-mycobacterial treatment and anti-inflammatory agents. Further studies are required to confirm whether *MAI* has a causal relationship with organising pneumonia, thus representing a broader clinico-pathological manifestation of *MAI* pulmonary infection.

References

- Rosenzweig DY. Pulmonary mycobacterial infections due to *Mycobacterium intracellulare-avium* complex. Clinical features and course in 100 consecutive cases. *Chest* 1979; 75: 115-119.
- Colby TV. Pathologic aspects of bronchiolitis obliterans organizing pneumonia. *Chest* 1992; 102: 38S-43S.
- Cordier J-F. Cryptogenic organising pneumonia. *Eur Respir J* 2006; 28: 422-446.
- Marchevsky A, Damsker B, Gribetz A, Tepper S, Geller SA. The Spectrum of Pathology of Nontuberculous Mycobacterial Infections in Open-Lung Biopsy Specimens. *Am J Clin Pathol* 1982; 78: 695-700.
- Hamada K, Nagai S, Hara Y, Hirai, Mishima M. Pulmonary Infection of *Mycobacterium avium-intracellulare* Complex with Simultaneous Organizing Pneumonia. *Internal Medicine* 2006; 45: 15-20.
- Griffith DE, Aksamit T, Brown-Elliott B A, *et al.* An official ATS/IDSA statement: diagnosis, treatment, and prevention of nontuberculous mycobacterial diseases. *Am J Respir Crit Care Med* 2007; 175: 367-416.
- Parker B, Ford M, Gruft H, Falkinham J. Epidemiology of infection by nontuberculous mycobacteria: IV. Preferential aerosolization of *Mycobacterium Intracellulare* from natural waters. *Am Rev Respir Dis* 1983; 128: 652-656.
- Aksarnit T R. Hot tub lung: infection, inflammation, or both? *Semin Respir Infect* 2003; 18: 33-39.
- Khoor A, Leslie KO, Tazelaar HD, Helmers RA, Colby TV. The clinicopathologic spectrum of infections due to nontuberculous mycobacteria in immunocompetent people (hot tub lung). *Am J Clin Pathol* 2001; 115: 755-762.
- Davison AG, Heard BE, McAllister WA, Turner-Warwick ME. Cryptogenic organizing pneumonitis. *Q J Med* 1983; 52: 382-394.
- Epler GR, Colby TV, McCloud TC, Carrington CB, Gaensler EA. Bronchiolitis obliterans organizing pneumonia. *N Engl J Med* 1985; 312: 152-158.
- Flowers JR, Clunie G, Burke M, Constant O. Bronchiolitis obliterans organizing pneumonia: the clinical and radiological features of seven cases and a review of the literature. *Clin Radiol* 1992; 45: 371-377.
- Dina R, Sheppard MN. The histological diagnosis of clinically documented cases of cryptogenic organizing pneumonia: diagnostic features in transbronchial biopsies. *Histopathology* 1993; 23: 541-545.
- Poletti V, Cazzato S, Minicuci N, Zompatori M, Burzi M, Schiattone ML. The diagnostic value of bronchoalveolar lavage and transbronchial lung biopsy in cryptogenic organizing pneumonia. *Eur Respir J* 1996; 9: 2513-2516.
- Bradley B, Branley HM, Egan JJ, *et al.* Interstitial lung disease guideline: the British Thoracic Society in collaboration with the Thoracic Society of Australia and New Zealand and the Irish Thoracic Society. *Thorax* 2008; 63 Suppl 5: v1-58.
- Management of opportunist mycobacterial infections: Joint Tuberculosis Committee Guidelines 1999. Subcommittee of the Joint Tuberculosis Committee of the British Thoracic Society. *Thorax* 2000; 55: 210-8.
- Wallace RJ Jr, Brown BA, Griffith DE, Girard WM, Murphy DT. Clarithromycin regimens for pulmonary *Mycobacterium avium* complex: the first 50 patients. *Am J Respir Crit Care Med* 1996; 153: 1766-1772.
- Kanatani MS, Guglielmo BJ. The new macrolides: azithromycin and clarithromycin. *West J Med* 1994; 160: 31-37.
- Jenkins PA, Campbell IA, Banks J, Gelder CM, Prescott RJ, Smith AP. Clarithromycin vs ciprofloxacin as adjuncts to rifampicin and ethambutol in treating opportunist mycobacterial lung diseases and an assessment of *Mycobacterium vaccae* immunotherapy. *Thorax* 2008; 63: 627-634
- Wales D, Woodhead M. The anti-inflammatory effects of macrolides. *Thorax* 1999; 54 (suppl 2): 58S-62S.
- Rubin BK, Henke MO. Immunomodulatory activity and effectiveness of macrolides in chronic airway disease. *Chest* 2004; 125 (suppl 2): 70S-78S.
- Sakito O, Kadota J, Kohno S, Abe K, Shirai R, Hara K. Interleukin 1 β , tumor necrosis factor α , and interleukin 8 in bronchoalveolar lavage fluid of patients with diffuse panbronchiolitis: a potential mechanism of macrolide therapy. *Respiration* 1996; 63: 42-48.
- Aoki Y, Kao PN. Erythromycin inhibits transcriptional

- activation of NF- κ B, but not NFAT, through calcineurin-independent signaling in T-cells. *Antimicrob Agents Chemother* 1999; 43: 2678-2684.
24. Yamazaki Y, Kubo K, Sekiguchi M, Honda T. Analysis of BAL fluid in *M. avium*-intracellulare infection in individuals without predisposing lung disease. *Eur Respir J* 1998; 11: 1227-31.
25. Middleton AM, Chadwick MV, Nicholson AG, *et al.* The role of *Mycobacterium avium* complex fibronectin attachment protein in adherence to the human respiratory mucosa. *Mol Microbiol* 2000; 38: 381-391.
26. Carré PC, King TE Jr, Mortensen R, Riches DW. Cryptogenic organizing pneumonia: increased expression of interleukin-8 and fibronectin genes by alveolar macrophages. *Am J Respir Cell Mol Biol* 1994; 10: 100-105.



Pavia - Almo Collegio Borromeo