

Flow mediated dilation in patient with Berlin Heart Incor left ventricle assist device

Dilatazione flusso-mediata in un paziente con un device di assistenza ventricolare Berlin Heart Incor

Franco Tarro Genta¹, Elena Colajanni¹, Pierluigi Sbarra¹, Massimo Tidu¹,
Mauro Rinaldi², Enzo Bosimini¹

ABSTRACT: *Flow mediated dilation in patient with Berlin Heart Incor left ventricle assist device. F. Tarro Genta, E. Colajanni, P. Sbarra, M. Tidu, M. Rinaldi, E. Bosimini.*

Endothelial function measured with brachial ultrasound (BU) is a validated prognostic factor in heart failure patients. LVAD (left ventricle assist device) application is a promising surgical technique to treat refractory heart failure patients both as a bridge to heart transplantation or as

destination therapy. Clinical recovery in such patients may be associated to normal endothelial function measured by BU but, as recently reported, only in pulsatile flow LVAD patients. The present paper report a case of normal endothelial function even in a axial LVAD patient.

Keywords: endothelial function, LVAD.

Monaldi Arch Chest Dis 2008; 70: 38-40.

¹ Fondazione Salvatore Maugeri, Casa di Cura Major; Via Santa Giulia, 60 - I-10124 Torino, Italy.

² Divisione di Cardiocirurgia, Università degli Studi di Torino.

Corresponding author: Franco Tarro Genta MD, Casa di Cura Major, Fondazione Salvatore Maugeri; Via Santa Giulia, 60 - I-10124 Torino, Italy; E-mail: franco.tarrogenta@fsm.it

Introduction

Due to heart donors shortage, axial flow left ventricle assist device (LVAD) has become an effective mean for patients waiting for heart transplantation when hemodynamic is not more adequately supported by drugs [1]. Endothelial dysfunction has gained the role of an important prognostic marker in heart failure [2]; the influence of the particular almost continuous flow generated by these device on vascular reactivity has not been fully examined. We report our findings on endothelial function in one such patient.

Case report

An 60 years-old male patient with familial dilated cardiomyopathy, 20% left ventricular ejection fraction, with previous biventricular/ICD implantation for NSVT and symptomatic (NYHA III) heart failure despite optimal medical therapy while in active heart transplantation list, converted to NYHA IV heart failure unresponsive to drugs and underwent a Berlin Heart Incor left ventricle assist device (LVAD)(Berlin Heart AG, Germany) application intended as bridge to transplantation with usual technique (figure 1 and 2). Cardiac tamponade (surgically resolved) and MRSA skin infection of electric cable exit (treated with vancomycine) complicated the operation.

Patient was transferred to our rehabilitation centre three months after LVAD implantation in class NYHA III.

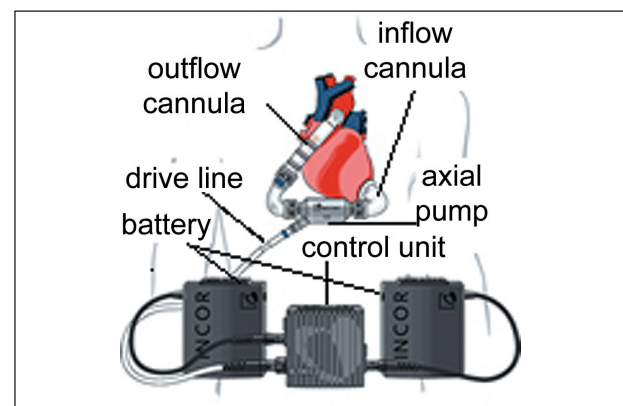


Figure 1.

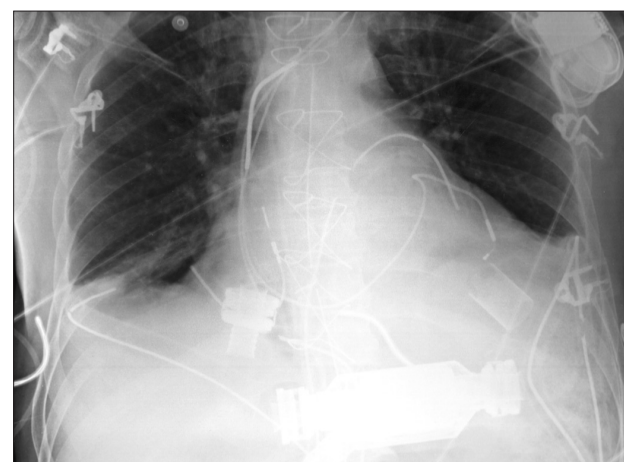

Figure 2. - Patient chest X ray after LVAD insertion.

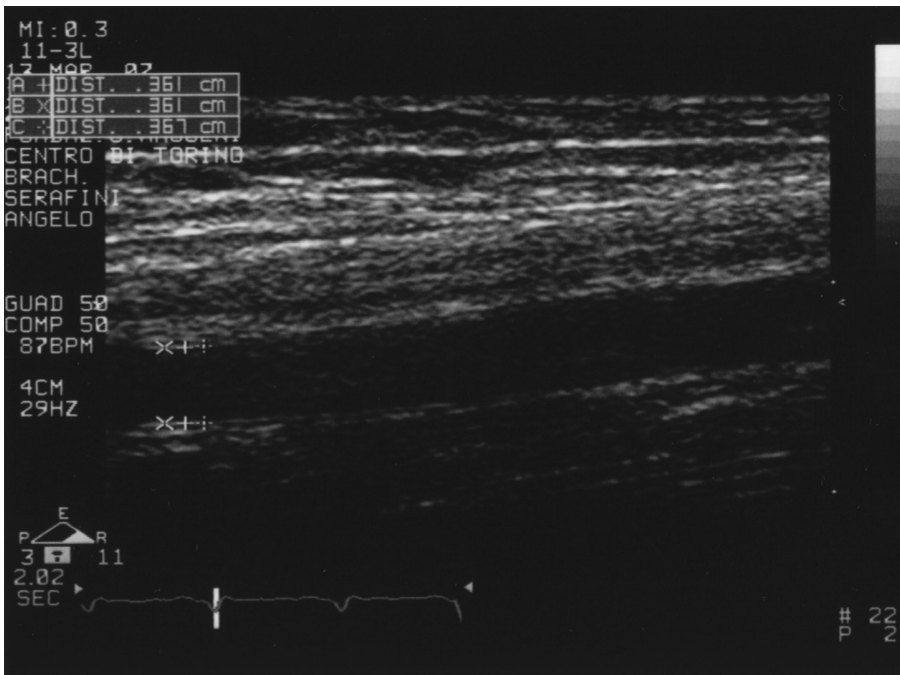


Figure 3. - Basal brachial artery diameter at brachial ultrasound.

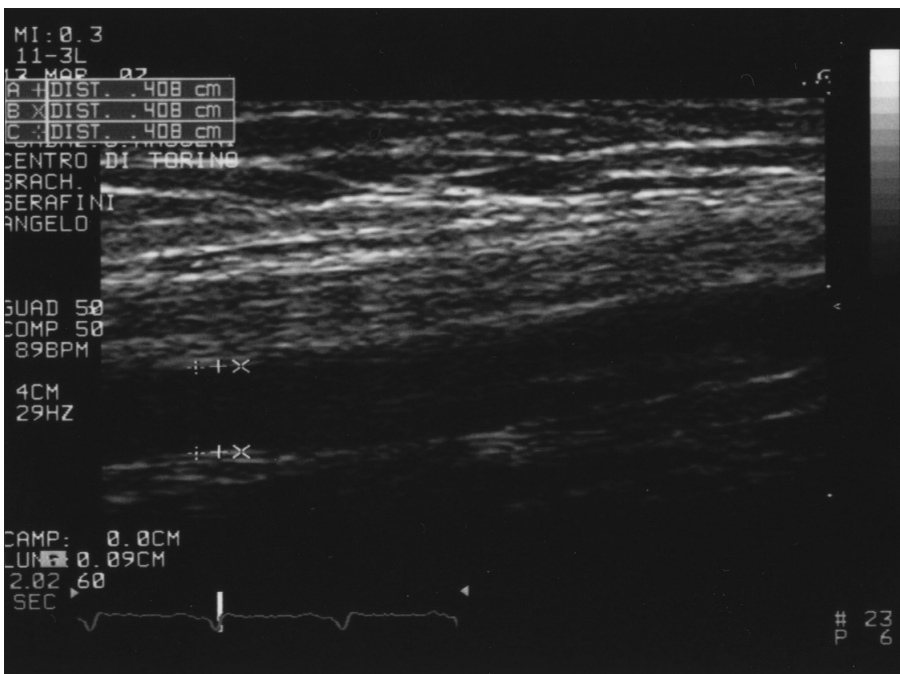


Figure 4. - Brachial artery diameter at brachial ultrasound after cuff release.

Weekly technical device controls were performed by Incor engineer; nearly continuous flow was generated with the following settings: 7800 rpm speed, 4.8 L/minute cardiac output

The patient followed a structured training cycle with daily respiratory, muscular reinforcement and treadmill session (twenty minute session at 2 km/h). Drugs therapy consisted of warfarin, clopidogrel, aspirin, amiodarone, enalapril.

At the end of rehabilitation period we investigated endothelial function with high resolution brachial ultrasound following updated guidelines [3, 4].

Flow mediated dilation (FMD) [(60 second after cuff release artery diameter- basal diameter)/basal

diameter] was 12% (figure 3 and 4); flow, in basal condition and after cuff release showed minimal pulsatility (figure 5 and 6); mean flow velocity showed a 3.5 fold increased 15 second after cuff release compared to basal flow (figure 5 and 6).

After 5 weeks he left our centre in a NYHA II class; he is still waiting heart transplantation, NYHA class is stable and he is followed up weekly in heart transplantation day hospital.

Discussion

The prognostic value of endothelial dysfunction evaluated by flow mediated dilation measure at brachial ultrasound in heart failure patients is well established [2].

Application of left ventricle assist device may improve hemodynamic in advanced drug-refractory heart failure leading to functional class (NYHA) recovery and is intended both as a bridge to transplantation or as a destination therapy [1]. This clinical benefits may also translate in endothelial function recovery assessed as FMD.

The normalization of measured endothelial function in severe heart failure patients after LVAD implantation has recently been investigated by Amir *et coll.* [5] with FMD measured in 10 patients with pulsatile flow LVAD and in 10 patients with axial flow LVAD; they assessed that only pulsatile flow LVAD patients showed normal endothelial function while axial LVAD patients had a significantly reduced endothelial function.

In this case report, in contrast with these results, we measured a normal flow mediated dilation in a patient with axial flow Berlin Heart Incor LVAD implantation after a rehabilitation cycle.

This may be partly explained by the flow that, yet continuous, showed a small but evident pulsatile trend probably due to residual myocardial contractility; anyway the long training cycle may have influenced the endothelial function recovery: as reported physical training may improve endothelial function [6, 7]. Moreover in the above mentioned work [5] only 1 out of 10 axial LVAD was of the

kind implanted in our patient.

Further studies are needed to explore endothelial function measured after any kind of LVAD implantation and its prognostic power.

Riassunto

La valutazione della funzione endoteliale con ecodoppler brachiale (EB) rappresenta un validato fattore prognostico nei pazienti affetti da scompenso cardiaco. L'impianto di LVAD (left ventricle assist device) è una promettente tecnica chirurgica per stabilizzare i pazienti con scompenso cardiaco refrattario sia in attesa di trapianto cardiaco che come terapia definitiva. Il miglioramento clinico in tali pazienti si può associare ad una normale funzione endoteliale valutata con EB che però, secondo un recente studio, si evidenzia solo nei pazienti con LVAD con flusso pulsatile. Il presente case report evidenzia la presenza di buona funzione endoteliale anche in un paziente con impianto di LVAD con flusso assiale continuo.

LEGEND

- ICD: implantable cardiac defibrillator
- NSVT: non sustained ventricular tachycardia
- NYHA: New York Heart association
- Rpm: rounds per minute
- Ecg: electrocardiogram
- MRSA: meticillin resistant staphylococcus aureus

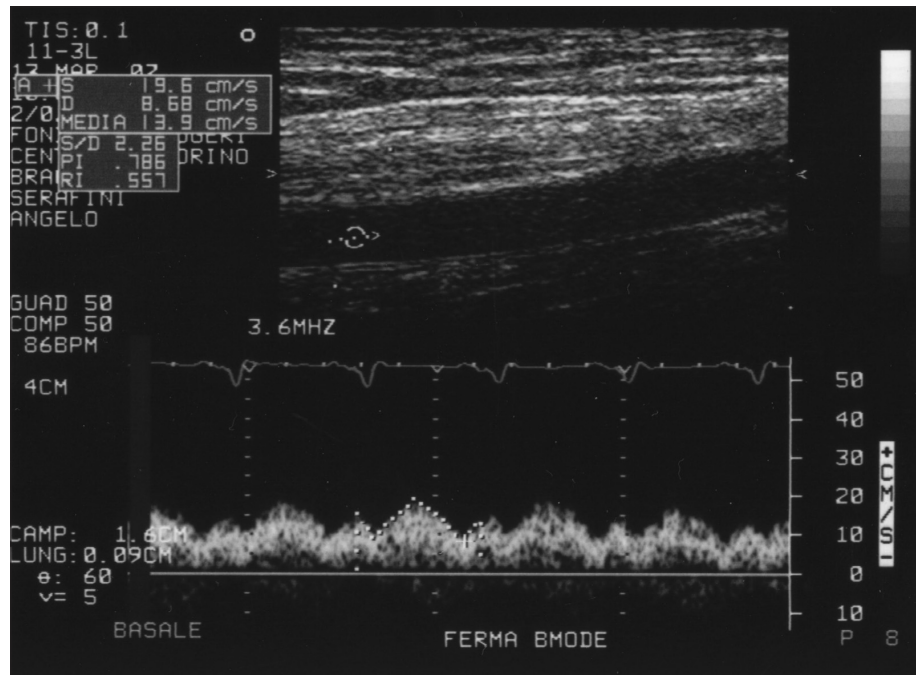


Figure 5. - Basal brachial artery flow at brachial ultrasound.

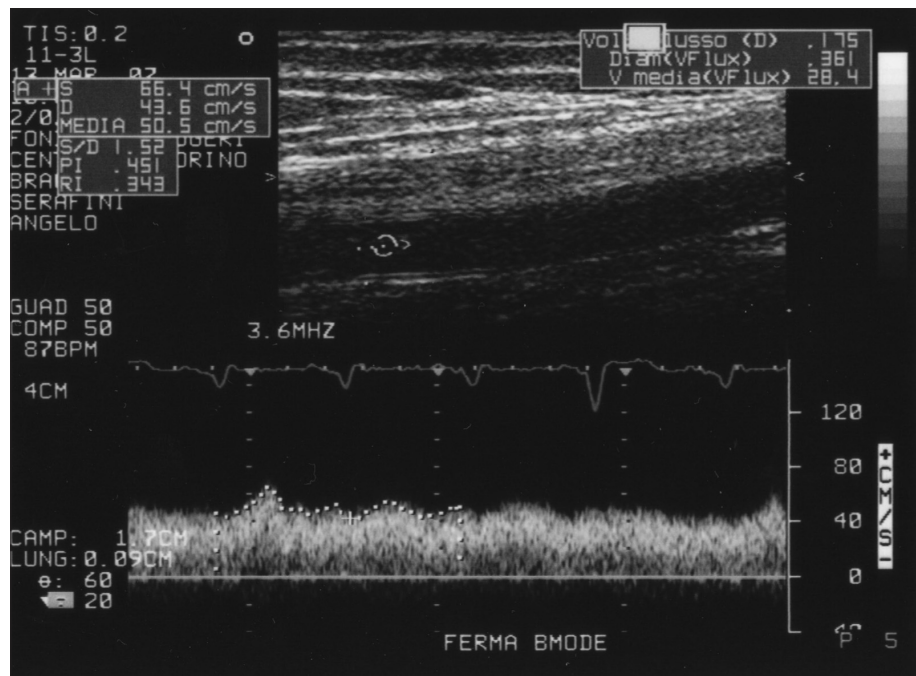


Figure 6. - 15 seconds after cuff release: brachial artery flow at brachial ultrasound.

References

1. Miniauskas S, Ručinskas K, Bubulis R, et coll. Application of Berlin Heart assist devices in the treatment of heart failure. *Seminars in Cardiology* 2005; 11 (3): 115-120.
2. Meyer B, Morti D, Strecker K, et coll. Flow-mediated vasodilation predicts outcome in patients with chronic heart failure: comparison with B-type natriuretic peptide. *J Am Coll Cardiol* 2005 Sep 20; 46 (6): 1011-8.
3. Coretti MC, Anderson TJ, Benjamin EL, Celermajer D, et coll. Guidelines for the ultrasound assessment of endothelial-dependent flow mediated vasodilation of the brachial artery; a report of the international brachial artery reactivity task force. *Jam Coll Cardiol* 2002; 39, 257-265.
4. Pyke KE, Tschakovsky ME. The relationship between shear stress and flow-mediated dilatation: implication for the assessment of endothelial function. *J Physiol* 2005; 568.2: 357-369.
5. Amir O, Radovancevic B, Delgado III RM, et coll. Peripheral Vascular Reactivity in Patients With Pulsatile vs Axial Flow Left Ventricular Assist Device Support. *J Heart Lung Transplant* 2006; 25 (4): 391-4.
6. Kingwell BA, Sherrard B., Jemmings GL, et coll. Four weeks of cycle training increases basal production of nitric oxide from the forearm. *Am J Physiol* 1997; 272: H1010-7.
7. Green DJ, Maiorana A, O'Driscoll G, Taylor R. Effect of exercise training on endothelium-derived nitric oxide function in humans. *J Physiol* 2004; 561: 1-25.