

Extrapleural hematoma: when is surgery indicated?

A.S. Poyraz, D. Kilic, B. Gultekin, M. Ozulku, A. Hatipoglu

ABSTRACT: *Extrapleural hematoma: when is surgery indicated? A.S. Poyraz, D. Kilic, B. Gultekin, M. Ozulku, A. Hatipoglu.*

Extrapleural haematoma (EH) is a rare clinical condition of which four cases are presented. Different etiologies were encountered. Identical findings were found on the

chest X-ray. Two cases were secondary to spontaneous rib fracture and the other two were iatrogenic. Surgical exploration was necessary in one patient following pleural biopsy. Medical treatment and clinical observation were the treatment of choice in the remaining three stable patients. *Monaldi Arch Chest Dis 2005; 63: 3, 166-169.*

Keywords: *Haematoma, extrapleural haematoma, percutaneous catheterisation, pleural biopsy, spontaneous rib fracture.*

Department of Thoracic and Cardiovascular Surgery, Faculty of Medicine, Baskent University, Ankara, Turkey.

Correspondence: A. Serhan Poyraz, Department of Thoracic and Cardiovascular Surgery, Faculty of Medicine, Baskent University, Konya, Turkey; e-mail: ahmetserhanpoyraz@hotmail.com

Introduction

To our knowledge only a few reports of extrapleural haematoma (EH) with different etiology have been presented in literature. We describe four patients with EH referred to our department during a 3-year period, with different etiological factors – both spontaneous and iatrogenic – and with identical findings on the chest X-ray.

Case Reports

Patient 1

A 63-year-old woman was scheduled to undergo dialysis because of end-stage renal disease. A central venous catheter was inserted in the right subclavian vein, but it was removed because of insufficient flow. Haematoma occurred on the insertion site. A postero-anterior chest radiograph revealed an intense, round, homogeneous shadow, 6x5 cm in size, with a broad basis arising from the upper chest wall (fig. 1a). Lateral film was suggesting an extrapleural process (fig. 1b). A chest computed tomographic (CT) scan revealed a loculated extrapleural effusion in the right hemithorax (fig. 1c). EH in this case occurred after an attempt to cannulate the subclavian vein. The haemoglobin level was stable and the patient was merely observed and no other treatment was given. Follow-up chest films showed spontaneous regression and resolution of the haematoma (fig. 1d).

Patient 2

A 55-year-old man presented with pain in the upper chest after forceful paroxysmal coughing. On examination, he had mild tenderness over his right chest. There was no history of thoracic trauma

and etiologic factor was distant osteopenia due to chronic renal disease. A chest roentgenogram revealed spontaneous fracture of 5th right rib and a 4x4 cm homogeneous density having in the middle zone of the right hemithorax suggesting an extrapleural process. The patient was admitted to the hospital for observation. He was symptom-free after spontaneous resolution after one month.

Patient 3

A 52-year-old woman was diagnosed with diabetes mellitus, chronic renal failure and thickening of the left pleura. To evaluate the latter a pleural biopsy was performed. The following day breath sounds were diminished at the base of the left lung and haemoglobin levels started to decrease necessitating blood transfusion and vasopressor therapy. Chest X-ray revealed a poorly delineated left lung field and a haemothorax was suspected. Initially, the patient was thought to have an intrapleural haematoma, which was treated by closed drainage. However, only an extremely small amount of blood-like fluid was evacuated. She was taken into surgery and a left anterolateral mini-thoracotomy with partial resection of the 6th rib was performed. The operative findings did not support a diagnosis of an intrathoracic loculated pleural haematoma. An extrapleural haematoma measuring 10x7 cm diameter was found in the left extrapleural space. The haematoma was evacuated. No bleeding vessel was found. The patient was discharged from hospital without any further complications.

Patient 4

A 32 year-old man suffering from chronic cough presented to the emergency department with

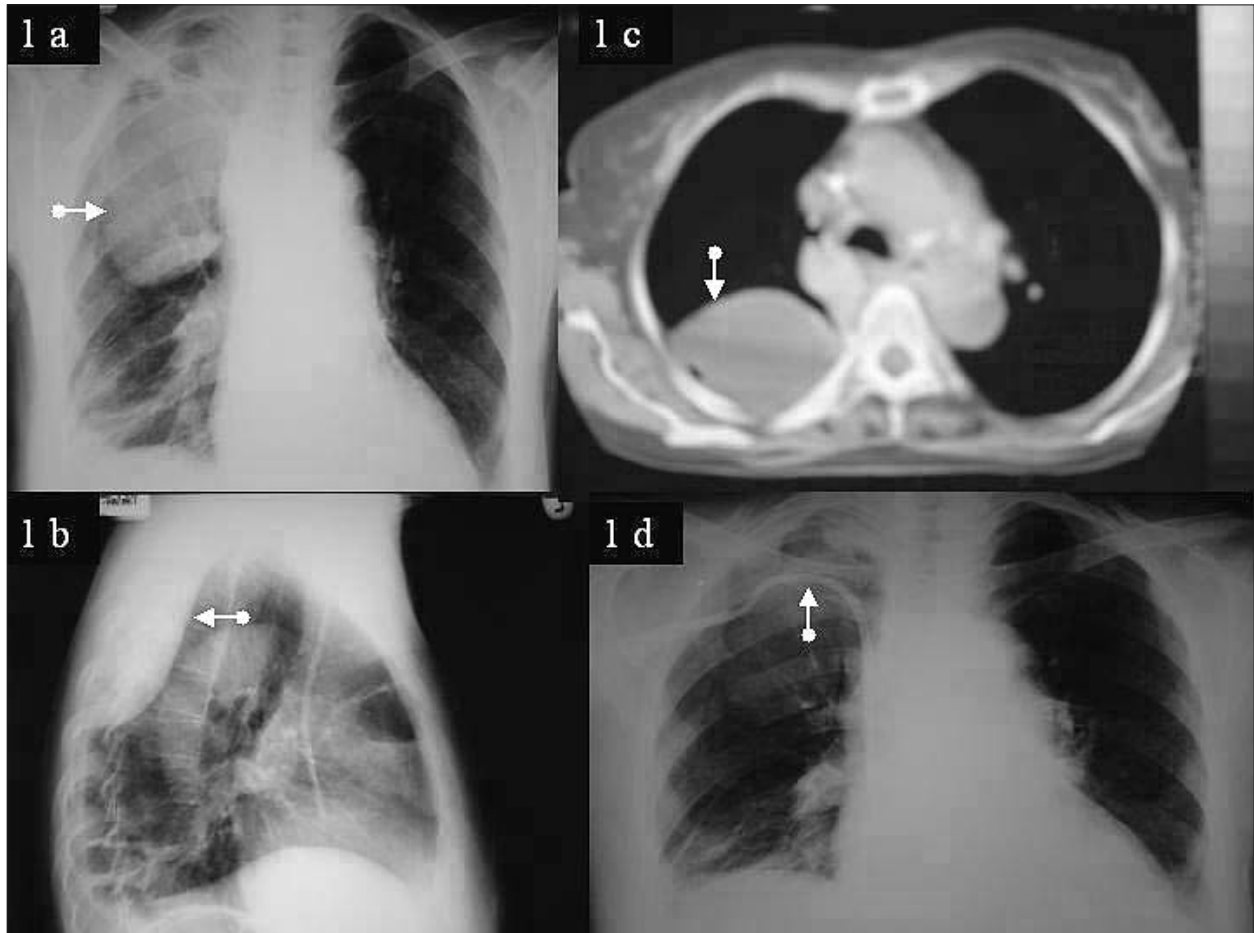


Fig. 1 a-d. - Patient 1. (a) Postero-anterior chest roentgenogram revealing an intense, round, homogeneous shadow, 6x5 cm, in the upper zone (arrow). (b) Lateral chest roentgenogram showing a 7x4 cm intense, homogeneous density, with a broad basis arising from the chest wall, situated near the vertebral column (arrow). (c) Chest CT demonstrating a loculated extrapleural effusion in the right hemithorax (arrow). (d) Follow-up chest X-ray revealing no evidence of any residual disease. A catheter is present in the right subclavian vein (arrow).

upper chest pain of sudden onset associated with dyspnea. There was no specific etiologic factor besides forceful paroxysmal coughing due to influenza. Physical examination revealed a 4x4 cm tender area overlying the right 7th rib. Chest X-ray film revealed a 5x3 cm opacity with a sharply defined convex contour in the lower chest facing the lung. Superior and inferior margins were tapered suggesting an extrapleural process with an EH in relation to a spontaneous fracture of 7th rib (fig. 2a). Follow-up chest films showed spontaneous resolution after 4 days (fig. 2b).

Discussion

EH may occur spontaneously or secondary to various etiologic factors. Rashid *et al.* described a simple etiologic classification of EH which was divided in 3 groups: spontaneous, iatrogenic and traumatic [1]. There are a few case reports in the literature to date in which the etiology and treatment modalities of EH specifically discussed [1-8] (table 1). Three of these reports deal with cases of primary traumatic (TEH). On reviewing the literature, cases of EH as a complication of central venous catheterisation (iatrogenic) are reported as isolated events [2-4]. In our series both iatrogenic and spontaneous EH were present. To our knowl-

edge, this is the first report of EH as a result of spontaneous rib fracture and pleural biopsy.

Rashid *et al.* explain the mechanism of EH as follows: a specific procedure such as cannulation of the subclavian vein, causes rupture of blood vessels of the thoracic wall and the blood cannot escape into pleural space as the thickened parietal pleura prevents its rupture resulting in EH [1].

Clinical manifestations of EH include haemorrhage, pain, and dyspnea as shown in our series.

The diagnosis of EH can be challenging. In particular, when differential diagnosis between loculated intrapleural or extrapleural haematoma is difficult, a chest CT is recommended. With prolonged extrapleural compression of the lung, changes in the pulmonary parenchyma may be observed. We recognized all our cases using chest roentgenogram. In cases of spontaneous EH the absence of penetration of the pleural cavity and absence of a pleural reaction may result in a pleural cavity without effusion. Delay in diagnosis and treatment may have serious, early consequences, with massive haemorrhaging from the large vessels of the upper thorax, the most serious and potentially life-threatening complication. Huge EH might cause ventilatory and circulatory disturbances and even death.

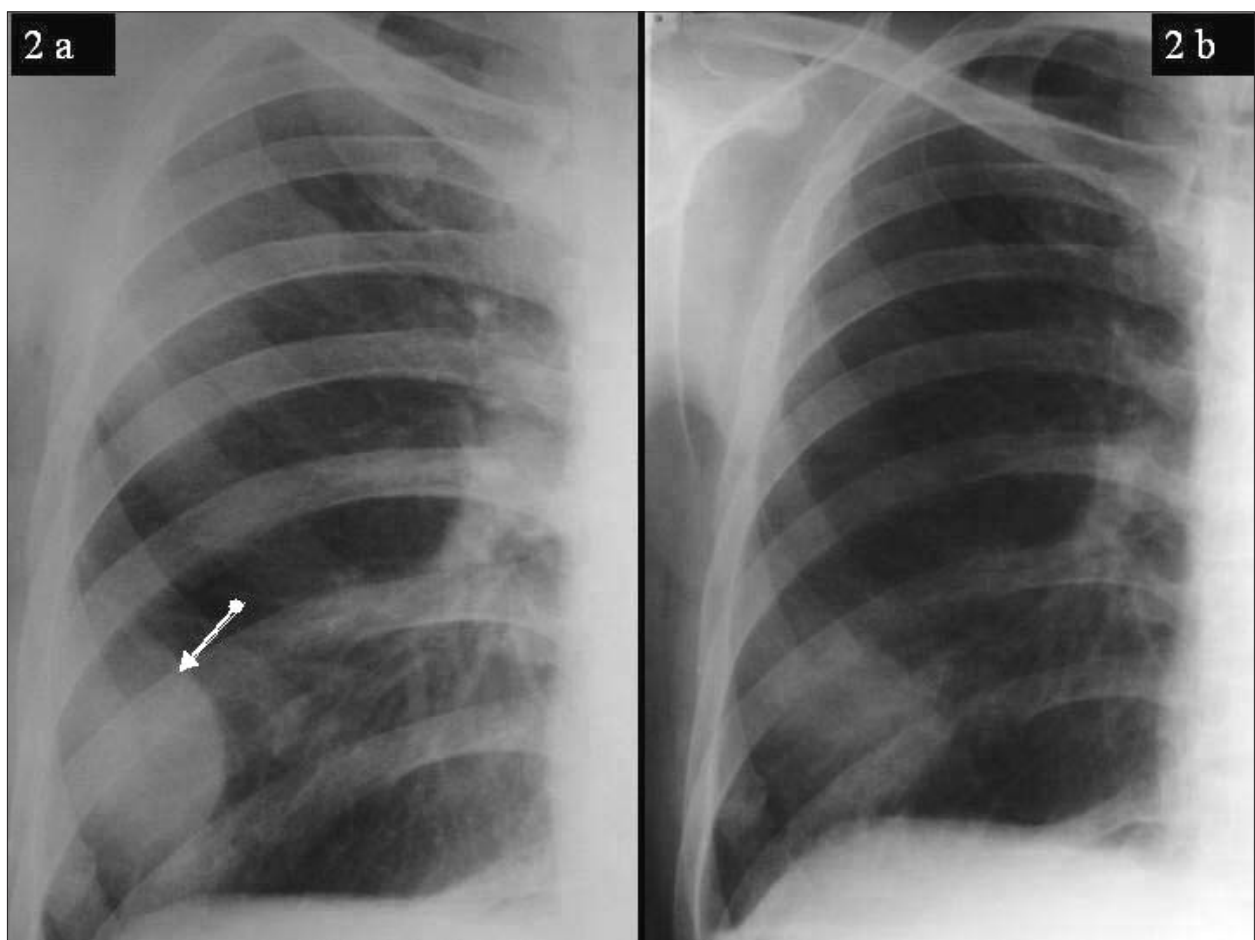


Fig. 2 a, b. - Patient 4. (a) Postero-anterior chest roentgenogram revealing an opacity of 5x3 cm in the lower chest with a sharply defined convex contour facing the lung (arrow) with tapered superior and inferior margins together with a fracture of the 7th rib. (b) Chest roentgenogram showing spontaneous resolution after 4 days.

Table 1. - Different etiology and treatment modalities presented for EH presented in the literature to date

Reference	Year	Patient Number	Etiology	Treatment and outcome
Rashid MA (1)	2000	34	Chest trauma	Spontaneous resolution in 33 patients, thoracotomy in one patient, postoperative course was uneventful
Brandi LS (2)	1984	1	After attempted catheterization of the internal jugular vein	Spontaneous resolution
Ueki R (3)	2000	1	After attempted catheterization of the right jugular vein	Spontaneous resolution
Kay J (4)	1987	1	After attempted catheterization of the internal jugular vein	Neck dissection and median sternotomy, postoperative course was uneventful
Mingoli A (5)	2004	1	After thoracic blunt trauma and rib fractures in an anti-coagulated patient (Trauma)	Emergency surgical treatment, postoperative course was uneventful
Konen O (6)	2002	2	After coronary surgery	Spontaneous resolution in both patients
Moulin G (7)	1992	1	Fracture of the body of the eleventh thoracic vertebra (Trauma)	Surgical treatment, postoperative course was uneventful
Present cases	2005	4	Spontaneous rib fracture (2), pleural biopsy (1), after attempted catheterization of the right subclavian vein (1)	Spontaneous resolution in 3 patients and limited thoracotomy in one patient, postoperative course was uneventful

The differential diagnosis includes encapsulated intrapleural effusion, pleural and extrapleural tumours, pleural plaque, peripheral lung tumor, and plombage, e.g. oleothorax, round atelectasis and mesothelial cyst.

Treatment for EH has been established in literature. Decision-making criteria in surgery are closely related to the clinical condition of patient. In our series, spontaneous complete resolution was observed in three patients whose medical therapies were successful. Closed drainage failed, and a limited thoracotomy to evacuate the haematoma was performed in the fourth patient. The EH may necessitate blood transfusion when an active bleeding vessel is present [4, 5]. Because of poor visualisation as a cause of no anatomical cavity, Rashid MA *et al.* suggested that video-assisted thoracic surgery was not suited to approach and manage the TEH [8]. Unless large sizes, TEH should be considered a relative major contraindication to VATS. This approach is very important in saving time and money. However, we believe that VATS could be useful in exploring the pleural cavity, open up the parietal pleura, drain the haematoma and look for a bleeding vessel. Thus, in the case of an unsuccessful procedure, conversion to thoracotomy is possible. Another treatment option after a CT scan of the chest is obtained, is to insert a drain in the extrapleural space under CT guidance and in case of insufficient drainage due to clotted haematoma, to start thrombolytic treatment as is done for a retained haemothorax.

In conclusion, medical therapy and clinical observations are the treatment of choice in a stable patient in case of a small haematoma. Thoracotomy may be necessary in the presence of a complication such as massive haemorrhages, persisting and large haematomas and in cases of insufficient drainage.

References

1. Rashid MA, Wikstrom T, Ortenwall P. Nomenclature, classification, and significance of traumatic extrapleural hematoma. *J Trauma* 2000; 49: 286-290.
2. Brandi LS, Mosca F, Carmellini M, Nannoni L, Comite C, Manfrini M. An unusual complication of percutaneous catheterization of the internal jugular vein. *Acta Anaesthesiol Belg* 1984; 35: 231-236.
3. Ueki R, Okutani R, Fukushima A, Kurehara H, Sasaki K, Tashiro C. Iatrogenic extrapleural hematoma [abstract]. *Masui* 2000; 49: 37-39.
4. Kay J, Goodman LR, Gurney J. Extrapleural hematoma: a recognizable complication of central venous pressure monitoring. *J Clin Monit* 1987; 3: 64-66.
5. Mingoli A, Assenza M, Petroni R, *et al.* Large extrapleural hematoma in an anticoagulated patient after a thoracic blunt trauma. *Ann Ital Chir* 2004; 75 (1): 83-5.
6. Konen O, Hertz M, Klein HO, Konen E, Zissin R. Extrapleural hematoma as an unexpected finding on a follow-up chest X-ray after coronary surgery. *Eur J Radiol* 2002; 44 (3): 225-7.
7. Moulin G, Bartoli JM, Fighiera M, *et al.* Extrapleural hematoma. *J Radiol* 1992; 73 (5): 327-30.
8. Rashid MA. Value of video-assisted thoracic surgery in traumatic extrapleural hematoma. *Thorac Cardiovasc Surg* 1999; 47: 255-257.



Pavia - Università, Aula Magna