

Fibrosing mediastinitis causing rapidly progressive dyspnea, pulmonary edema and death in a 16 yr old male

K. Malagari¹, S. Papiris²

ABSTRACT: *Fibrosing mediastinitis causing rapidly progressive dyspnea, pulmonary edema and death in a 16 yr old male. K. Malagari, S. Papiris.*

Idiopathic fibrosing mediastinitis is a rare entity involving more severely the more compliant structures within the mediastinum. In this report a rare case of simultaneous involvement of both the superior vena cava (SVC)

and pulmonary veins is described in a 16 – year old male with progressive dyspnea on exertion, cough and a three months' history of blood – tinged sputum. Physical examination and imaging studies revealed signs of pulmonary venous hypertension (PVH) and SVC stenosis. Fibrosing mediastinitis was confirmed by multiple biopsy samples. *Monaldi Arch Chest Dis 2004; 61: 2, 124-127.*

Keywords: *Fibrosing mediastinitis; postcapillary pulmonary hypertension; pulmonary edema; superior vena cava syndrome.*

¹ 2nd Department of Radiology, Athens Medical School, National and Capodistrian University of Athens, "Evgenidion" Hospital, 20 Athens.

² Department of Pulmonary and Critical Care Medicine, Athens Medical School, National and Capodistrian University of Athens, "Evangelismos" General Hospital Athens.

Correspondence: K. Malagari; 19 Monis Kyccou; 15669 Papagou, Athens, Greece; e-mail: kmalag@acn.gr

Introduction

The excessive proliferation of fibrous tissue in fibrosing mediastinitis is often associated with vascular encasement [1-3].

In this case report we describe a rare case of concomitant involvement of SVC and pulmonary veins in a 16-year old boy presenting with severe pulmonary venous hypertension (PVH) not responding to treatment. Imaging features of PVH and SVC syndrome and differential diagnosis are discussed in detail.

Case report

A 16-year old male was referred to our hospital because of rapidly progressive shortness of breath, cough and a 3 month history of hemoptysis. The patient, upon admission, was in apparent distress, cyanotic, tachypneic (30 breaths/min), and tachycardic (120 beats/min). On physical examination the patient presented mild face edema, and rales were audible on auscultation in the lower lung zones bilaterally. Oxygen saturation was 87%. The patient's medical history was unremarkable until 6 months before admission, when a "severe" lower respiratory tract infection was reported.

The chest radiograph in semi-recumbent position obtained on admission (fig. 1) demonstrated superior mediastinal widening, dilatation of the azygos vein, a prominent aortic knob and mild cardiac enlargement. Interstitial opacities were seen bilaterally.

High Resolution Computed Tomography (HRCT) (fig. 2) demonstrated diffuse bronchial wall thickening extending all the way to the hili, marked dilatation of the intrapulmonary veins and thickening of the fissures. In addition, smooth septal (Kerley) lines were noted in some areas associated with areas of ground glass opacities with a

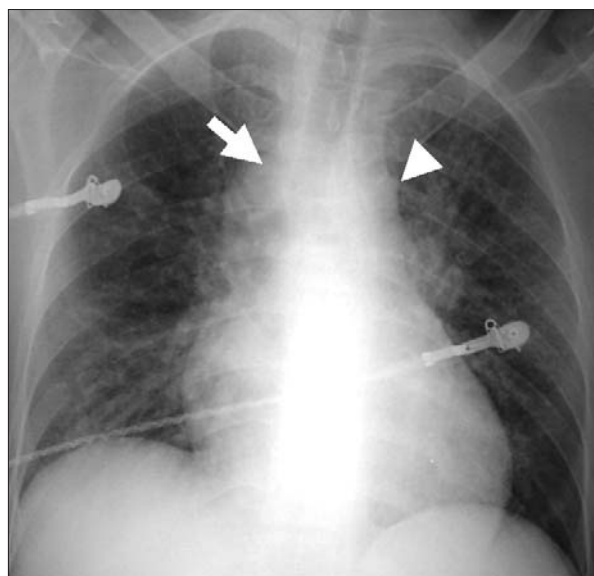


Fig. 1. - Posteroanterior chest-X-ray: minimal superior mediastinal widening with dilatation of the azygos vein (arrow) and a prominent aortic nipple (arrow head) representing a dilated superior left intercostal vein suggestive of collateral venous flow. Mild cardiac enlargement is noted. Interstitial opacities are seen bilaterally.

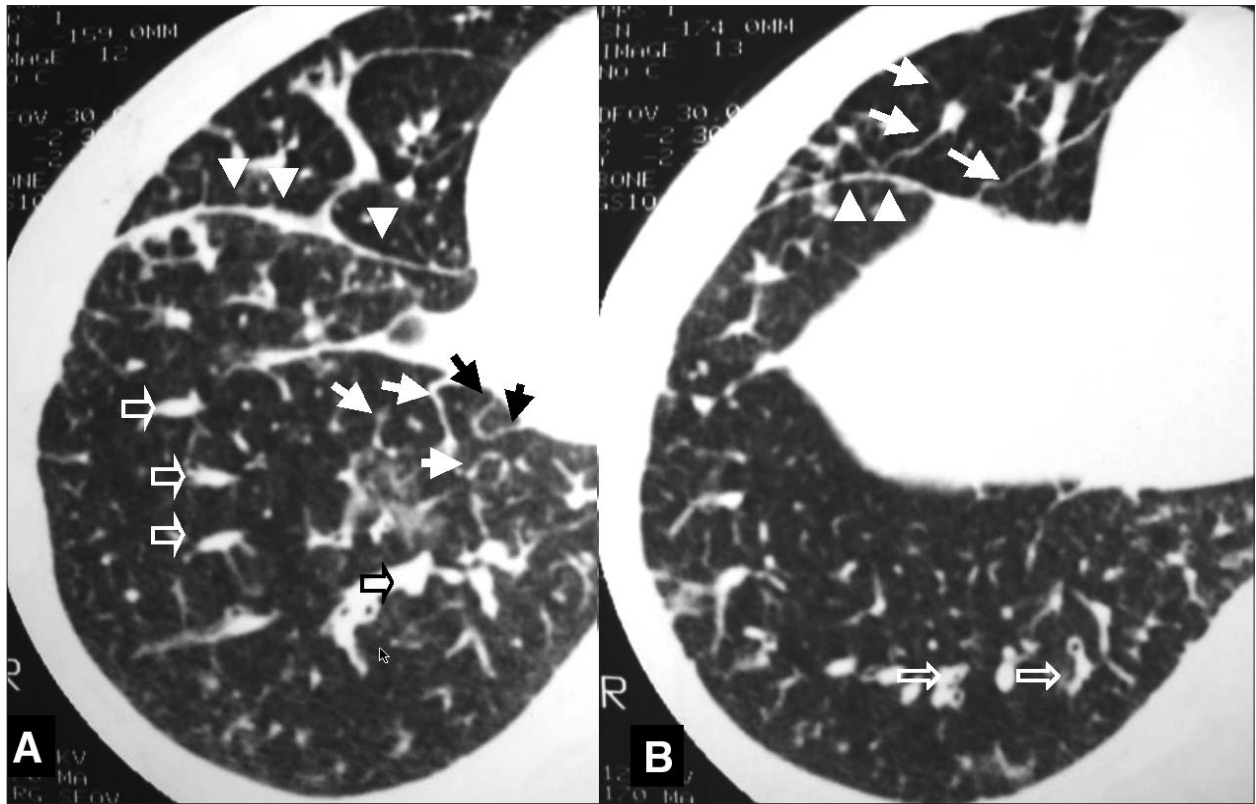


Fig. 2 A, B. - HRCT slices at the lower lung zones demonstrate diffuse bronchial wall thickening, marked dilatation of the intrapulmonary branches of the pulmonary veins (open arrows), and thickening of the fissures (arrow heads). Smooth thickening of the interlobular septa is seen in some areas (solid arrows) associated with areas of ground glass opacities.

rather regional distribution. Mediastinal windows of CT images and Magnetic Resonance confirmed a mediastinal soft tissue mass encasing the SVC (fig. 3 A, B).

The working diagnosis was that of increased post-capillary pressure pulmonary edema and the patient underwent right heart catheterization which disclosed increased pulmonary capillary wedge pressure (28 mm Hg) and moderate pulmonary hypertension. Radiographic images obtained with contrast opacification also revealed severe superior vena stenosis with a well developed collateral flow (fig. 3 C). Cardiac ultrasound showed normal left ventricular contractility. No intracardiac shunts, masses, thrombi or valve dysfunction were detected.

Surgical exploration was decided by the cardiac surgery team because of the rapid deterioration of the patient not responding to conservative treatment with the aim of biopsy and palliation. Exploration revealed abundant dense fibrous tissue in the pulmonary hili extending within the lung parenchyma and multiple biopsies were taken. Excision of fibrous tissue around the veins was not feasible. The patient continued his downfall course rapidly after surgery without response to conservative treatment and died the 4th post operative day.

The histologic examination revealed an invasion of the bronchovascular bundles and pulmonary veins by mature fibrous tissue with venous and arterial thrombi in various stages of organisation. There was no evidence of neoplastic or granulomatous disease and stainings were negative for

fungi. The final diagnosis was idiopathic fibrosing mediastinitis.

Discussion

This patient with rapidly progressive dyspnoea of recent onset presented imaging findings highly suggestive of pulmonary venous hypertension (PVH). Although PVH is an unusual diagnosis in a previously healthy young patient the imaging findings along with the clinical presentation and rales on chest auscultation make the initial diagnosis of venous hypertension and hydrostatic pulmonary edema very likely. Postcapillary venous hypertension was confirmed by the right-heart catheterisation, disclosing a high wedge pressure.

The patient also presented SVC stenosis. The decreased right heart outflow caused by the SVC syndrome might explain the fact that the patient had not developed florid alveolar edema.

The differential diagnosis included the different causes of PVH as well as the different causes of SVC stenosis. Mitral valve disease was reasonably excluded based on cardiac ultrasound. Similarly, left ventricular failure that in this young patient might be associated with a viral myocarditis was reasonably excluded on the basis of cardiac catheterisation and ultrasound. The latter examination also excluded the diagnosis of a left atrial mass and congenital pulmonary venous stenosis or total anomalous venous drainage. Pulmonary venoocclusive disease (PVOD) is a rare cause of pulmonary venous hypertension characterised by

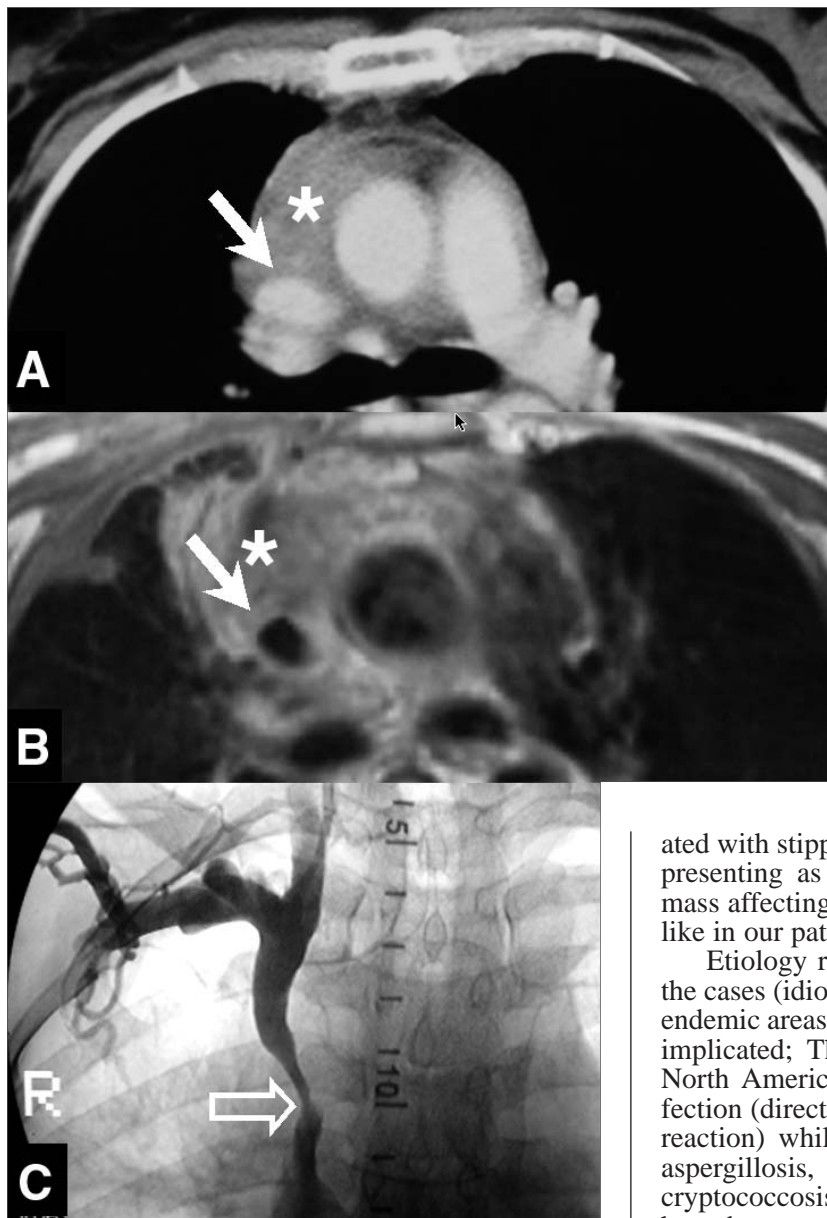


Fig. 3. - (A) Focused CT and magnetic resonance (B) sections show encasement of SVC (arrows) within a mediastinal soft tissue mass (asterisks). (C) SVC venography shows a marked stenosis (open arrow).

obstruction or occlusion of the lumen of the venules within the lung by repeated thrombosis and intimal proliferation of fibrotic tissue [3]. However, typically, normal or low pulmonary arterial wedge pressure (left atrial pressure) is reported in this entity [3]. In addition, in the few HRCT reports all features of PVH are seen in PVOD except for the intrapulmonary venous dilatation due to the fibrotic process that completely obliterates the venous lumens [4].

The only condition, that could explain the combined manifestation of PVH and SVC stenosis would be an infiltrative process affecting both the SVC and the pulmonary veins. Such processes include infiltrative neoplastic disease and fibrosing mediastinitis [5, 6]. Of the neoplastic diseases, a predominantly infiltrative growth pattern is seen in desmoplastic mesothelioma, metastatic carcinomas with fibrogenic inflammatory response, infil-

trative thymomas, low grade sarcomas, sclerosing type of non-Hodgkin lymphoma, and nodular sclerosis subtype of Hodgkin's disease [5]. A definite diagnosis and differentiation from fibrosing mediastinitis is obtained only by histology. Large tissue specimens and adequate sampling are essential to exclude malignancy associated with abundant desmoplastic reaction, making surgical biopsy necessary [6, 7].

Fibrosing mediastinitis is a rare condition, often progressive and potentially lethal, characterised by the proliferation of fibrous tissue and dense a-cellular collagen within the mediastinum occasionally containing patchy infiltrates of mononuclear cells or less commonly granulomas [6, 7].

Two forms of the disease have been recognised; one presenting a relatively localized distribution of the fibrosis most commonly (focused around lymph nodes and usually associated with stippled calcification) and a second form presenting as diffusely infiltrating, non-calcified mass affecting multiple mediastinal compartments like in our patient [8].

Etiology remains unknown in the majority of the cases (idiopathic fibrosing mediastinitis) but in endemic areas granulomatous infections have been implicated; The most common – particularly in North America – is *Histoplasma Capsulatum* infection (direct infection or abnormal immunologic reaction) while rare causes include tuberculosis, aspergillosis, mucormycosis, blastomycosis, and cryptococcosis infection [7-9]. Other diseases that have been associated with fibrosing mediastinitis include autoimmune disease, Behçet disease, rheumatic fever and other idiopathic fibro-inflammatory disorders such as retroperitoneal fibrosis, sclerosing cholangitis, Riedel thyroiditis, and pseudotumor of the orbit [6, 7, 10, 11]. Trauma, radiation, methysergide maleate have also been associated with the development of fibrosing mediastinitis [5, 6, 12]. Idiopathic cases are more often of the diffuse type while post inflammatory cases are more frequently localised [8].

Clinical manifestations vary greatly depending on the compression of the individual mediastinal structures, the type of fibrosing mediastinitis (localised vs diffuse) and the compliance of the structures involved; those more compliant are more often involved notably in order of frequency the SVC, pulmonary veins, oesophagus, airways, pulmonary arteries, heart, pericardium, coronary arteries, and aortic branch vessels. Symptoms include cough, dyspnea, hemoptysis, SCV syndrome, fever and weight loss [1-3, 6].

Similarly, the spectrum of imaging findings in an individual patient depend primarily on distribu-

tion and mediastinal structure/s involved; Imaging manifestations include bilateral widening of the superior mediastinum (from SVC syndrome and/or fibrous tissue), signs of PVH and oedema (compression of pulmonary veins), localized regions of oligemia (compression of pulmonary arteries), or segmental or lobar atelectasis or recurrent pneumonia (compression of airways) [13, 14]. PVH in fibrosing mediastinitis is manifested by the classic signs of interstitial edema such as bronchial cuffing, septal/ Kerley lines, ground glass opacities and subpleural edema. Asymmetry in distribution of edema is frequently seen in this condition (regional edema) [3, 13, 14]. All these features were present in our patient. Calcification within the mediastinum or hili is seen in up to 86% of patients—most frequently encountered in the localized form of the disease (usually associated with histoplasma capsulatum infection) [14].

Systemic antifungal agents, antituberculous treatment and/or corticosteroids have been advocated for treatment if a specific cause is suspected and might assist in stabilisation of the process and/or improvement of symptoms [15]. However, no randomised control trials have been performed to reach solid conclusions. Localised disease may be subject to surgical or endoluminal treatment such as stent positioning, excision of fibrous tissue or lumen reconstruction [16, 17]. Diffuse disease like in our patient usually precludes surgery since it has poor results and is associated with high morbidity and mortality [17].

References

- Berry DF, Buccigrossi D, Peabody J, Peterson KL, Moser KM. Pulmonary vascular occlusion and fibrosing mediastinitis. *Chest* 1986; 89: 296-301.
- Espinosa RE, Edwards WD, Rosenow EC, Schaff HV. Idiopathic pulmonary hilar fibrosis: an unusual cause of pulmonary hypertension. *Mayo Clin Proc* 1993; 68: 778-782.
- Chazova I, Robbins I, Loyd J, et al. Venous and arterial changes in pulmonary veno-occlusive disease, mitral stenosis, and fibrosing mediastinitis. *Eur Respir J* 2000; 15: 116-122.
- Swensen SJ, Tashjian JH, Myers JL, et al. Pulmonary venoocclusive disease: CT findings in eight patients. *Am J Roentgenol* 1996; 167: 937-940.
- Dehner LP, Coffin CM. Idiopathic fibrosclerotic disorders and other inflammatory pseudotumors. *Semin Diagn Pathol* 1998; 15:161-173.
- Mole TM, Glover J, Sheppard MN. Sclerosing mediastinitis: a report on 18 cases. *Thorax* 1995; 50 (3): 280-283.
- Flieder DB, Suster S, Moran CA. Idiopathic fibroinflammatory (fibrosing/sclerosing) lesions of the mediastinum: a study of 30 cases with emphasis on morphologic heterogeneity. *Mod Pathol* 1999; 12: 257-264.
- Sherrick AD, Brown LR, Harms GF, Myers JL. The radiographic findings of fibrosing mediastinitis. *Chest* 1994; 106: 484-489.
- Lagerstrom CF, Mitchell HG, Graham BS, Hammon JW Jr. Chronic fibrosing mediastinitis and superior vena caval obstruction from blastomycosis. *Ann Thorac Surg* 1992; 54 (4):764-765.
- Morgan AD, Loughridge LW, Calne RY. Combined mediastinal and retroperitoneal fibrosis. *Lancet* 1966; 1: 67-70.
- Othmani S, Bahri M, Louzir B, Borhan K, Bahri M. Mediastinal fibrosis combined with Behcet's disease. *Rev Med Interne* 2000; 21 (4): 330-336.
- Dechambre S, Dorzee J, Fastrez J, Hanzen C, Van Houtte P, d'Odemont JP. Bronchial stenosis and sclerosing mediastinitis: an uncommon complication of external thoracic radiotherapy. *Eur Respir J* 1998; 11 (5): 1188-1190.
- Lee JY, Kim Y, Lee KS, Chung MP. Tuberculous fibrosing mediastinitis: radiologic findings. *Am J Roentgenol* 1996; 167 (6): 1598-1599.
- Rodriguez E, Soler R, Pombo F, Requejo I, Montero C. Fibrosing mediastinitis: CT and MR findings. *Clin Radiol* 1998; 53: 907-910.
- Urschel HC, Jr, Razzuk MA, Netto GJ, Disiere J, Chung SY. Sclerosing mediastinitis: improved management with histoplasmosis titer and ketoconazole. *Ann Thorac Surg* 1990; 50: 215-221.
- Dodds GA III, Harrison JK, O'Laughlin MP, Wilson JS, Kisslo KB, Bashore TM. Relief of superior vena cava syndrome due to fibrosing mediastinitis using the Palmaz stent. *Chest* 1994; 106: 315-318.
- Garrett HE, Jr, Roper CL. Surgical intervention in histoplasmosis. *Ann Thorac Surg* 1986; 42: 711-722.



Pavia - Palazzo Broletto