

An unusual presentation of tuberculosis

K. Karkoulas, M. Tsiamita, E. Prodromaki, K. Spiropoulos

ABSTRACT: *An unusual presentation of tuberculosis. K. Karkoulas, M. Tsiamita, E. Prodromaki, K. Spiropoulos.*

We describe a case of a male with no symptoms and normal chest X ray, diagnosed with TB. The chest com-

puted tomography revealed a cavity formation on the upper left lobe.

Monaldi Arch Chest Dis 2004; 61: 2, 131-132.

Keywords: *cavitary tuberculosis, mantoux reaction, X Ray, CT scan.*

Division of Pulmonology Department of Internal Medicine, University Hospital of Patras Medical School.

Correspondence: Spiropoulos Kostas MD; Assoc. Professor of Pulmonology; University Hospital of Patras Medical School; Patras, 26500; Greece; e-mail: kkarkoul@freemail.gr

Introduction

Culture-positive pulmonary tuberculosis (TB) with a normal CXR is not uncommon and the incidence of this presentation is increasing.

We present this case report in order to emphasise that the diagnosis of tuberculosis can often be elusive because of the varied clinical and radiological presentations of the disease.

Case report

The patient was a 26 years old, medical assistant, non-smoker, previously in good health. He presented to the department of pulmonology for evaluation of the purified protein derivative skin test performed 48 hours ago. The mantoux reaction was positive (in duration 12 mm). He denied fever, dry cough, weight loss, and fatigue, laboratory examinations were noncontributory, and the physical examination was unremarkable. The cause of performing the mantoux reaction was an overall check up triggered by an accidental piercing with a contaminated needle during work. The exams included HIV, Hepatitis B and C testing. The patient denied BCG vaccination in the past, and did not recall the outcome of a previous tuberculin skin testing. Chest-X-ray (CXR) was normal (figure 1). Because of his high occupational risk for TB exposure, chest computed tomography (CT) and bronchoscopy were subsequently performed. Positive acid-fast bacilli were detected in bronchial washing smears and cultures. CT scan revealed distortion of the bronco vascular structures and cavity formation at the upper left lobe (figure 2). Complete antituberculous therapy was commenced -Rifampicin and Isoniazid for 9 months, and Pyrazinamide and Ethambutol for 2 months, because the radiographic findings revealed cavitary TB. No side effects during therapy were observed. Follow up bronchoscope after the completion of the antimycobacterial therapy was

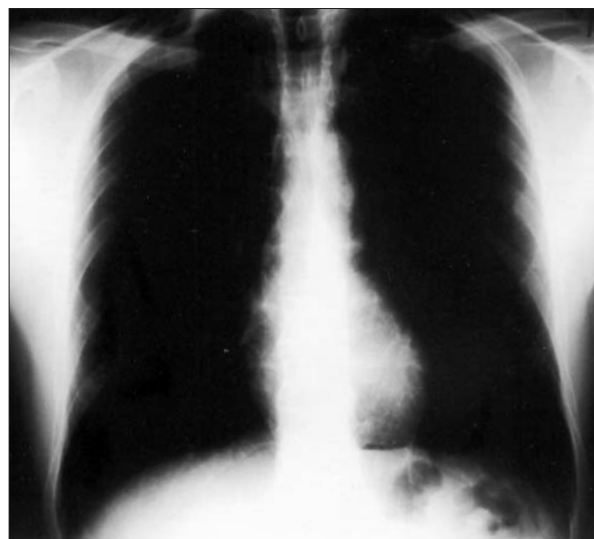


Fig. 1. - Chest X-Ray of the patient: no abnormality is visible.

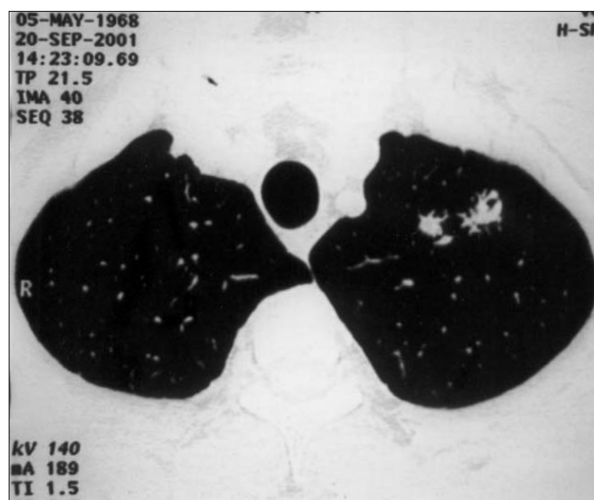


Fig. 2. - CT scan: cavity formation with thick walls at the upper left lobe.

performed and the smears and cultures were negative. CT Scan performed a year later revealed obliteration of the cavity and formation of scar tissue (figure 3).

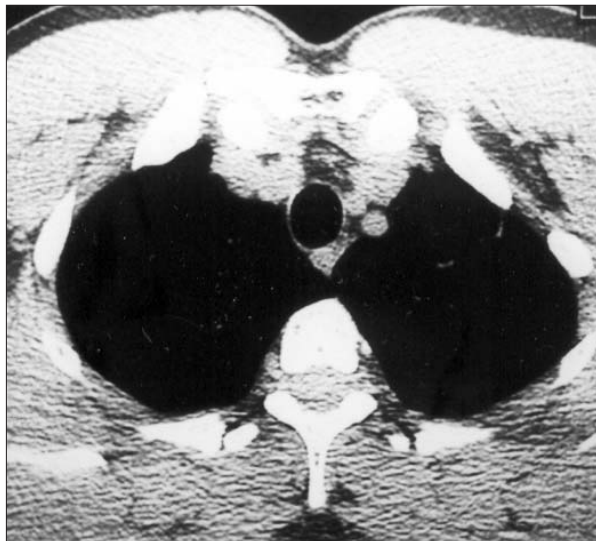


Fig. 3. - Follow up CT scan a year later. Resolution of the cavity formerly seen.

Discussion

The diagnosis of TB can often be elusive because of the varied clinical and radiological presentations of the disease. Pulmonary TB in the presence of a normal CXR has been previously described. Although this type of presentation has been infrequent, recently this mode of presentation appears to be occurring with increasing frequency [1-4].

The clinical features of pulmonary TB manifesting itself in the absence of radiographic abnormalities have not been closely examined and thus are not well known. The incidence of pulmonary TB with a normal CXR has increased in the past 10 years. The incidence of culture positive pulmonary TB was 0.7% (1988-1989) and 3.5% (1990-1991). However, more recently the incidence of culture positive pulmonary TB with a normal CXR has increased to 10% (1996-1997). The inci-

dence of culture positive pulmonary TB, CXR negative in a symptom free patient is 2% [5].

There are many possible reasons for this increasing occurrence. The incidence of HIV infection-AIDS has also increased during this period and appears that HIV infection-AIDS may be a significant factor contributing to the incidence of pulmonary TB with a normal CXR [5]. The increased alertness of clinicians for detection of TB at an early stage, of high risk patients, with or without symptoms, because of contact tracing, documented tuberculin skin test conversion, hazardous occupation, has contributed to the increased incidence of CXR negative culture positive cases.

Establishing a diagnosis of TB at an early stage is desirable. Firstly, there are fewer public health concerns when cases are not smear positive. Secondly, the patient benefits from early diagnosis and treatment in terms of outcome, and money lost from employment. Finally the clinician avoids the serious consequences of delayed diagnosis, or drug resistance by offering single drug chemoprophylaxis to a patient with current pulmonary TB.

In conclusion the high index of suspicion for TB in health care workers makes it compelling to obtain a culture specimen, because CXR alone cannot be relied on to discover all cases of pulmonary TB.

References

1. Schmidek HIT, Hardy MA. Pulmonary tuberculosis with normal chest radiographs: report of 8 cases. *Can Med Assoc J* 1967; 97: 178-8.
2. Miller WT, Miller Jr WT. Tuberculosis in the normal host: radiological findings. *Semin Roentgenology* 1993; 28; 109-18.
3. Barnes PF, Verdegem TD, Vachon LA, et al. Chest roentgenogram in pulmonary tuberculosis: new data on an old test. *Chest* 1988; 94: 316-20.
4. Cohen R, Muzaffar S, Capellan J, et al. The validity of classic symptoms and chest radiographic configuration in predicting pulmonary tuberculosis. *Chest* 1996; 109: 420-32.
5. Marciniuk D, McNab B, Martin W, and Hoepfner V. Detection of Pulmonary tuberculosis in patients with a normal Chest Radiograph. *Chest* 1999; 115: 445-452.



Pavia - Palazzo Broletto