

Clinical and prognostic significance of muscle biopsy in sarcoidosis

Halil Yanardag¹, Cuneyt Tetikkurt², Muammer Bilir¹

¹ Department of Internal Medicine Medicine, Cerrahpasa Medical Faculty, Istanbul University

² Department of Pulmonary Medicine, Cerrahpasa Medical Faculty, Istanbul University, Turkey

Abstract

The main objective of this study was to evaluate the influence of muscle involvement on the clinical features, prognostic outcome, extrapulmonary organ, and endobronchial involvement in sarcoidosis patients. The second aim was to assess the diagnostic yield of muscle biopsy for the histopathologic identification of sarcoidosis.

Fifty sarcoidosis patients participated in the study. The patients were classified into two groups according to the histopathologic presence of non-caseating granulomatous inflammatory pattern of the muscle biopsy samples and were evaluated retrospectively in regard to the clinical features, prognosis, extrapulmonary, and endobronchial disease involvement. Pathologic examination of the muscle biopsy samples revealed non-caseating granulomas in eighteen and myositis in seven patients compatible with sarcoidosis. The diagnostic yield of muscle biopsy for demonstrating non-caseating granulomatous inflammation was fifty percent.

Patients with muscle sarcoidosis showed a worse prognosis and a more severe extrapulmonary organ involvement than the patients without muscle disease. Muscle biopsy was not statistically significant to delineate diffuse endobronchial involvement while it was suggestive for endobronchial disease clinically. The results of our study reveal that muscle biopsy appears to be a useful diagnostic tool along with its

safety and easy clinical applicability. It is a rewarding utility to predict the prognostic outcome and extrapulmonary involvement in sarcoidosis patients. Positive biopsy on the other hand confirms the identification of sarcoidosis in patients with single organ involvement carrying an equivocal diagnostic clinical pattern. Muscle biopsy may be considered as the initial step for the final diagnosis of sarcoidosis in such cases.

Introduction

Skeletal muscle granulomas are frequent in sarcoidosis and muscle involvement may develop in 50 to 75% of the sarcoidosis patients [1,2]. Symptomatic muscle sarcoidosis is rare and occurs in less than one percent [3,4]. Non-caseating granulomas may be observed in the peripheral muscle biopsy of the sarcoidosis patients and thereby facilitate the diagnosis of sarcoidosis [5-7]. The contribution of muscle involvement to diagnostic and prognostic outcome is uncertain because firm data revealing the diagnostic significance of muscle biopsy and the clinical features of muscle involvement in sarcoidosis is scarce.

Identification of sarcoidosis requires a tissue biopsy in at least two organs with the exception of the rare presentations where the clinical features are highly specific for sarcoidosis. Superficial biopsy sites are employed as the initial diagnostic procedure of choice compared to visceral organs. Several biopsy sites other than the lung have been used as alternatives for the tissue biopsy diagnosis of sarcoidosis. Muscle biopsy is a simple, reliable, and a conclusive diagnostic modality although previous studies have established indeterminate results [4-8]. Skeletal muscle biopsy may be considered as a clinical implement for diagnosis if other organ biopsy sites fail to provide an accurate histopathologic verification and to determine the muscle disease in sarcoidosis.

The primary aim of our study to assess the influence of muscle disease on the clinical features, prognostic outcome, extrapulmonary organ involvement, and endobronchial disease in sarcoidosis patients. Another objective was to investigate and to determine the diagnostic utility of muscle biopsy in sarcoidosis.

Materials and Methods

This is a retrospective cohort study including fifty sarcoidosis patients who were evaluated between March 1970 and August 2017 at our center. The study has been approved by the IRB/Ethics Committee of Cerrahpasa Medical Faculty (01/03/2016, 82556). Each patient had provided informed and written consent. Patients fulfilled the American Thoracic Society/European Respiratory Society criteria of sarcoidosis [9]. All subjects underwent pulmonary function tests, carbon monoxide diffusion capacity of the lung corrected for alveolar volume (DLCO/VA), chest x-ray, abdominal ultrasound, fiberoptic bronchoscopy (FOB), thorax computed tomography (CT), and muscle biopsy. Five asymptomatic patients did not accept biopsy.

Corresponding author: Prof. Cuneyt Tetikkurt, Tanzimat Sok. Serkan Apt. No:8/16, 34728 Caddebostan, Istanbul, Turkey.
Tel. +90.216.3601977 - Fax +90.212.5870217. E-mail: tetikkurt@gmail.com

Key words: Sarcoidosis; muscle sarcoidosis; muscle biopsy; gastrocnemius muscle.

Contributions: HY, patient data collecting, epidemiologic information, data evaluation; CT, contribution to manuscript preparation, statistical analysis, study design; MB, contribution to patient follow-up, references preparation, statistical analysis.

Conflict of interest: The authors declare no conflict of interest associated with this study.

Received for publication: 25 January 2018

Accepted for publication: 19 April 2018

©Copyright H. Yanardag et al., 2018

Tipografia PI-ME Editrice, Italy

Monaldi Archives for Chest Disease 2018; 88:910

doi: 10.4081/monaldi.2018.910

This article is distributed under the terms of the Creative Commons Attribution Noncommercial License (by-nc 4.0) which permits any noncommercial use, distribution, and reproduction in any medium, provided the original author(s) and source are credited.

The patients were classified into two groups, as AMI (absence of muscle involvement), and PMI (presence of muscle involvement), according to the presence of histopathologic findings compatible with sarcoidosis. Twenty-five patients with muscle sarcoidosis were compared to twenty-five patients without muscle disease in regard to clinical findings, disease prognosis, extrapulmonary organ, and endobronchial involvement. Laboratory investigations included complete blood count, liver function, renal function tests, serum Ca, 24 h urinary Ca, erythrocyte sedimentation rate, C-reactive protein, and angiotensin-converting enzyme (ACE). Abnormal liver or renal function tests, high serum ACE, hypercalcemia, and hypercalciuria were determined to be present if they were above the normal laboratory range. For stage evaluation the DeRemee criteria were used: stage 0, normal; stage 1, bilateral hilar lymphadenopathy; stage 2, bilateral hilar lymphadenopathy and parenchymal involvement; stage 3, parenchymal involvement only; and stage 4, pulmonary fibrosis [10].

Pulmonary function tests and DLCO/VA were performed according to the ATS/ERS criteria and the results interpreted in accordance with the ATS guidelines [11]. DLCO/VA was measured with the single-breath technique that was adjusted for alveolar ventilation. Values for the pulmonary function tests and DLCO/VA were evaluated as abnormal if they were outside the 95% confidence interval of the predicted values. Restrictive disease was revealed by a reduced total lung capacity (TLC) or forced vital capacity (FVC) and a normal or a high FEV1/FVC (Forced Expiratory Volume in one second to Forced Vital Capacity ratio). Diffusion capacity indicated by a DLCO/VA <80% value was denoted as abnormal. All patients were screened by a dermatologist, neurologist, and an ophthalmologist for the evaluation systemic involvement. Involvement of central nervous system was determined to exist if neurologic examination was positive, a lesion was identified by CT or magnetic resonance imaging (MRI), and identified by a consultant neurologist.

Epidemiological, clinical, and histopathologic findings were obtained from the medical records of the patients. Bronchoscopy and muscle biopsy were done under local anesthesia. Six bronchial biopsies were taken from each patient with an abnormal mucosa. In patients with a normal appearing mucosa eight biopsies from different sites and main carenas of both lungs were taken. Muscle biopsy was performed from gastrocnemius, pectoralis major, and brachialis muscle. Muscle involvement was diagnosed by the presence of non-caseating granulomatous inflammation pattern compatible with sarcoidosis identified by the histopathologic examination of the biopsy samples. Extrapulmonary organ involvement was classified into two groups as limited extrapulmonary organ involvement (LOI) if less than three organs were involved and as extensive extrapulmonary organ involvement (EOI) when three or more organs were comprised. Endobronchial disease was denoted as limited endobronchial involvement (LEI) in the presence of one positive bronchial biopsy sample and as diffuse endobronchial involvement (DEI) if two or more samples were positive for non-caseating granulomatous inflammation. Sarcoidosis activity and outcome were evaluated in regard to progressive stage, deterioration of pulmonary function tests, permanent decline of DLCO/VA values, extrapulmonary organ involvement, and the presence of severe systemic symptoms.

Fifteen patients were treated with corticosteroids, four patients received azathioprine, and two patients were commenced on methotrexate. Laboratory investigation during the follow-up period included blood count, serum biochemistry, serum and 24 h urinary calcium. Lung function tests FEV1, FVC, TLC, and DLCO/VA were done every six months while ABG analysis was performed when indicated. The outpatient control was scheduled every three to six months according to the clinical course of the patient. The mean follow-up period was 108.2±16.4 months. Progressive persistent disease was identified

if worsening pulmonary or systemic symptoms, severe pulmonary function impairment, extrapulmonary organ involvement, and evidence of significant worsening of radiologic findings occurred. It is well known that sarcoidosis often resolves within two to five years after diagnosis and patients who had manifestations of persistent disease five years following diagnosis were classified as chronic persistent disease. Refractory active inflammation lasting more than two years from the initial diagnosis lessens the chance of spontaneous resolution substantially [12-15]. Patients with a benign course who had negligible symptoms or trivial laboratory findings three years after diagnosis were designated to acquire a stable disease.

Data variables were represented by mean ± standard deviation. Patients were classified into two groups as with muscle and without muscle sarcoidosis. Clinical findings, prognostic outcome, and endobronchial involvement were compared between the two groups. Statistical differences between patients with and without muscle disease were evaluated in regard to prognosis, limited or extensive extrapulmonary organ sarcoidosis, and limited or diffuse endobronchial involvement. The χ^2 test was used for categorical variables as appropriate. Logistic regression was applied to determine the effect of age, gender, and muscle disease on prognosis. Kruskal-Wallis test and Bonferroni corrected two-way Mann-Whitney test were used for comparison of the groups. Student's *t*-test was done to compare the differences between serum ACE, serum Ca, 24h urinary Ca, PFTs, and DLCO/VA between the two groups. Statistical analysis was evaluated using software (ver. SPSS 22.0). A threshold p-value less than 0.05 was accepted for statistical significance.

Results

Study population consisted of 50 sarcoidosis patients (26 females) with a mean age of 40.2±14.6 years. Table 1 depicts the demographic and the clinical characteristics of the patients. Tuberculin test was negative in 38 (76%) patients. Bronchoscopic examination revealed mucosal abnormalities in 64.6 % of the cases. The most common lesion was miliary infiltration (36%) followed by nodular (26%), and erythematous lesions (22%) while 18 per cent of the patients had mixed type of lesions. Non-caseating granulomatous inflammation was identified from the endobronchial biopsy samples in 16 (32%) of the patients with a normal appearing mucosa. Culture of bronchial lavage was negative for bacteria, mycobacteria, and fungus in all of the patients. Muscle biopsy was performed at a single site from gastrocnemius muscle in 48 patients (96%), from right brachial muscle (2%), and from right pectoralis major (2%) muscle in two other patients. Histopathologic examination of the muscle biopsy samples revealed non-caseating granulomatous inflammation in 18 (18/50, 36%) and myositis in 7 (7/50, 14%) patients compatible with sarcoidosis.

Diagnostic histopathologic tissue was obtained by endobronchial biopsy (EBB) in 68%, by transbronchial biopsy (TBB) 48%, by skin biopsy in 32%, *via* mediastinoscopy in 14%, and by various organ biopsies in 26% of the patients. None of the subjects had a complication associated with the biopsy procedures. There was no significant difference between the FEV1, FVC, and TLC values of the two groups while DLCO/VA was lower ($p<0.05$) in patients with muscle involvement (Table 1). Logistic regression with Kruskal-Wallis test and Bonferroni corrected two-way Mann-Whitney test revealed no statistical difference of age and gender on prognosis. Serum, and 24 h urinary Ca values were not distinct ($p<0.9$, $p<0.11$) between the two groups (Table 1). Serum ACE was higher in patients with muscle disease ($p<0.05$). The sensitivity of muscle biopsy was 50% (25/50, $p<0.16$) and the specificity was 80% (20/25, $p<0.05$) while muscle biopsy confirmed the diagnosis

of sarcoidosis in ten patients (10/50, 20%; $p < 0.14$) with only one organ involvement. Of these ten patients seven had only lung and three had only cutaneous sarcoidosis at the initial presentation.

Association of muscle sarcoidosis with prognosis, extrapulmonary organ, and endobronchial involvement is shown in Figures 1, 2, and 3. Incidence of persistent chronic sarcoidosis was significantly higher ($p < 0.01$) in patients with muscle involvement than the patients without muscle disease (Figure 1). Extensive extrapulmonary organ involvement (61.2%) (Figure 2) was more frequent ($p < 0.05$) in patients with muscle sarcoidosis. Incidence of endobronchial involvement was more common in patients with muscle sarcoidosis that was insignificant ($p < 0.18$) statistically. Likelihood ratio of extensive extrapulmonary organ involvement was significantly higher ($p < 0.01$) in patients with muscle sarcoidosis. Logistic regression analysis revealed a 1.5 times worse prognosis and a 1.4 times more frequent extensive extrapulmonary organ disease ($p < 0.05$) in patients with muscle sarcoidosis compared to patients without muscle disease.

Discussion

Clinically evident skeletal muscle involvement in sarcoidosis is rare while inactive sarcoidosis granulomas are frequently found in clinically normal muscles. Muscle biopsy may detect non-caseating granulomas in 50-75% of the patients with sarcoidosis [1,2]. None of the patients in the screening studies have symptoms relevant to muscle involvement while this symptomless clinical profile resolves in the majority of the cases [3,16-19]. The primary objective for sarcoidosis diagnosis is the identification of non-caseating granulomatous inflammation in at least two organs with a compatible clinical picture while excluding other granulomatous disorders that show similar patterns. Currently, data relevant to the clinical features and prognosis in sarcoidosis patients with muscle disease is scarce because of the silent course and the variable incidence of muscle involvement [17-19]. Absence of distinct clinical and definitive laboratory findings indicating muscle dis-

ease may have further promoted the low variable incidence of muscle disease [17-21]. Our results reveal that muscle involvement is a significant risk factor for a severe prognostic outcome in sarcoidosis patients. The second crucial point of this study is the more frequent occurrence of extensive extrapulmonary organ disease in patients with muscle sarcoidosis. The third noteworthy issue is the high incidence of diffuse endobronchial granulomas in these patients. Although the high incidence of diffuse endobronchial involvement in patients with muscle sarcoidosis was statistically insignificant, this finding may point out to the presence of diffuse endobronchial granulomas even in patients with a normal appearing airway mucosa thereby revealing a clinically discernible point. Another hallmark is the identification of sarcoidosis by muscle biopsy in approximately twenty percent of the patients who had an equivocal diagnosis relevant to the presence of non-caseating granulomatous inflammation exclusively in one organ at the initial admission. The positive muscle biopsy result provided the final diagnosis by histopathologic verification in a significant number of diagnostically equivocal or indeterminate sarcoidosis patients.

Persistent chronic sarcoidosis does not always lead to fibrotic disease. The main point in the follow-up and treatment of these patients is the identification of risk factors for a worse prognostic outcome. Our study indicates that presence of muscle involvement may be a relevant clinical marker for a severe prognosis in sarcoidosis. It is well known that the granuloma burden in sarcoidosis appears to be the hallmark of persistent and progressive disease [22]. The adverse outcome in patients associated with muscle involvement is primarily due to the presence of high granuloma load of the muscles. Serum ACE produced in the epithelioid cells of the sarcoid granuloma reflects the total granuloma load in sarcoidosis [23-25]. The excessive granuloma burden caused by muscle disease in our study is justified by the presence of significantly higher levels of ACE in these patients. Treatment strategy in sarcoidosis targets on the premise of granuloma suppression thereby preserving organ function and attenuating fibrosis [22,24]. The kinetic chain of events associated with the granuloma formation, evolution, and distribution is the fundamental mechanism designating

Table 1. Demographic and clinical characteristics of the patients.

			p-value
Demographics			
Age (years)	40.2±14.6		<0.18
Gender			<0.21
Male patients	19 (42.2%)		
Female patients	26 (57.7%)		
Radiologic stage			
	AMI	PMI	
Stage I	9	5	
Stage II	7	10	
Stage III	3	6	
Stage IV	1	4	
Pulmonary function			
	AMI	PMI	
FEV ₁ , % predicted	72.4±18.2	74.1±15.3	<0.14
FVC, % predicted	78.6±14.8	77.2±16.4	<0.12
TLC, % predicted	82.4±19.8	80.4±12.8	<0.19
DLCO/V _A , % predicted	79.8±12.6	64.6±14.2	<0.05
Laboratory			
Serum Ca, mg/dL	8.64±2.6	8.24±4.2	<0.90
Urinary Ca, mg/day	262.6±26.8	264.1±22.6	<0.11
Serum ACE, IU/L	32.4±6.4	58.4±7.1	<0.05

Data are presented as mean±SD or %. A p-value less than 0.05 is significant.

the prognostic outcome of sarcoidosis. The primary differences of prognosis and organ involvement between individual patients is due to the unstable tendency of granuloma formation and dissemination [26,27]. Our study denotes the transformation of the granuloma burden is the hallmark of sarcoidosis. The higher the granuloma burden in a sarcoidosis patient the worse is the prognosis and extrapulmonary organ involvement.

There are potential limitations of our study. The first limitation is the small sample size. Second, the biopsy site was the gastrocnemius muscle

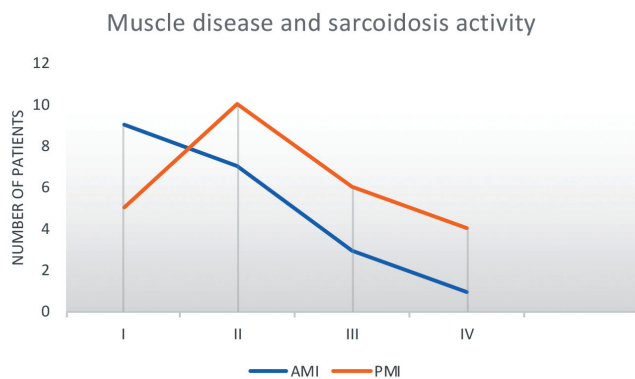


Figure 1. Muscle involvement and sarcoidosis activity.

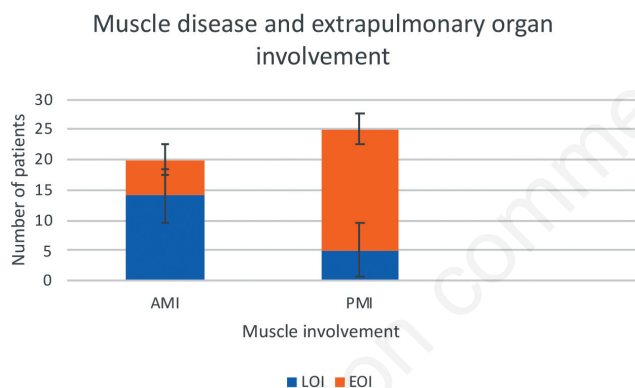


Figure 2. Muscle involvement and extrapulmonary organ sarcoidosis.

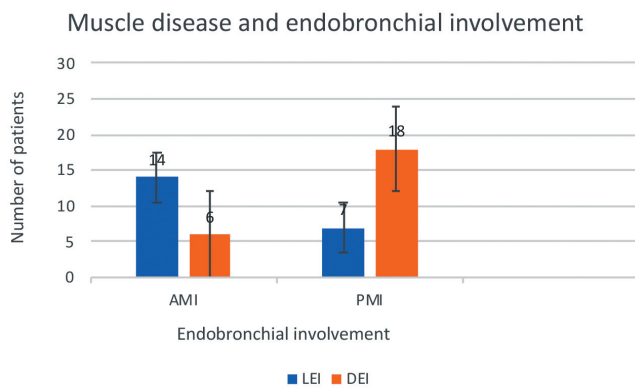


Figure 3. Muscle involvement and endobronchial sarcoidosis.

in ninety-six percent of our patients. The muscle biopsy would provide a higher diagnostic sensitivity if multiple biopsies had been performed at the same site or if more than one muscle had been targeted for biopsy. The statistical significance of the muscle biopsy sensitivity is low while the clinical significance is high especially for the identification of unequivocal sarcoidosis cases presenting with single organ involvement. The low statistical significance of sensitivity is related to the small sample size and conducting a single biopsy on one muscle site in all our patients. The sensitivity and the specificity may have been underestimated in our study due to the silent clinical profile of muscle sarcoidosis without any clinical criteria indicating muscle involvement. Third, the follow-up interval may be considered short but it is well known that most of the prognostic risk factors for progressive disease become apparent within two years of diagnosis [12-15] and patients with persistent disease after five years from diagnosis are classified as chronic disease. The mean follow-up period was approximately nine years in our study. Fourth, the bronchoscopic biopsy samples may be inadequate for the identification of the non-caseating granulomatous inflammation, especially in the normal mucosa and deeper mucosal biopsy sampling would be necessary for diagnosing endobronchial involvement. Clinical presentation and outcome of sarcoidosis patients show a considerable variation due to the different genetic factors. Our study group included only Caucasian people. It is well-known that sarcoidosis shows a great variability for clinical manifestations and prognostic outcome in regard to genetic background [9,28]. Further studies with larger sample sizes and more heterogeneous patient populations are needed to determine the exact association of muscle involvement with the clinical features and prognostic outcome of sarcoidosis.

The results of our study suggest that muscle involvement in sarcoidosis is a decisive risk factor for progressive disease. Extensive organ involvement is more common in patients with muscle sarcoidosis. The incidence of muscle involvement from sarcoidosis is highly variable because most of the patients are asymptomatic and the incidence of clinically detectable muscle sarcoidosis is low. The accurate distinction between persistent chronic and self-limited benign sarcoidosis may yield difficulties in clinical practice. Although progressive sarcoidosis does not always lead to advanced or fibrotic disease, diagnosis of such phenotypes appears to be the pivotal step for management. The statistically insignificant but the high incidence of diffuse endobronchial disease in patients with muscle involvement may draw attention to the presence of endobronchial granulomas rendering this finding as a crucial clinical criterion. Identification of muscle involvement by muscle biopsy is a useful, simple, and a noninvasive clinical tool to predict the prognostic outcome and to establish the diagnosis in equivocal cases. Optimal management of sarcoidosis depends upon the introduction of the treatment goals. Muscle biopsy appears to be a practical clinical enterprise to determine the treatment options, prognosis, and extrapulmonary organ involvement in sarcoidosis patients as a preliminary application while confirming the diagnosis of sarcoidosis in equivocal cases presenting with only one organ involvement.

References

1. Myers GB, Gottlieb AM, Mattman PE, et al. Joint and skeletal muscle manifestations in sarcoidosis. *Am J Med* 1952;12:161-9.
2. Wallace SL, Lattes R, Malia JP, et al. Muscle involvement in Boeck's sarcoid. *Ann Intern Med* 1958;48:497-511.
3. Costabel U. Skeletal muscle weakness, fatigue and sarcoidosis. *Thorax* 2005;60:1-2.
4. Otake S, Ishigaki T. Muscular sarcoidosis. *Semin Musculoskelet Radiol* 2001;5:167-70.

5. Andonopoulos AP, Asimakopoulos G, Mallioris C, et al. The diagnostic value of gastrocnemius muscle biopsy in sarcoidosis presenting with erythema nodosum and hilar adenopathy. *Clin Rheumatol* 1987;6:192-6.
6. Ost D, Yeldandi A, Cugell D. Acute sarcoid myositis with respiratory muscle involvement. Case report and review of the literature. *Chest* 1995;107:879-82.
7. Teirstein AS, Judson MA, Baughman RP, et al. The spectrum of biopsy sites for the diagnosis of sarcoidosis. *Sarcoidosis Vasc Diffuse Lung Dis* 2005;22:139-46.
8. Andonopoulos AP, Papadimitriou C, Melachrinou M, et al. Asymptomatic gastrocnemius muscle biopsy: an extremely sensitive and specific test in the pathologic confirmation of sarcoidosis presenting with hilar adenopathy. *Clin Exp Rheumatol* 2001;19:569-72.
9. Statement on sarcoidosis. *Am J Respir Crit Care Med* 1999;160:736-55.
10. DeRemee RA. The roentgenographic staging of sarcoidosis: historic and contemporary perspectives. *Chest* 1983;83:128-32.
11. [No authors listed]. Lung function testing: selection of reference values and interpretative strategies. American Thoracic Society. *Am Rev Respir Dis* 1991;144:1202-18.
12. Mañá J, Salazar A, Manresa F. Clinical factors predicting persistence of activity in sarcoidosis: a multivariate analysis of 193 cases. *Respiration* 1994;61:219-25.
13. Neville E, Walker AN, James DG. Prognostic factors predicting the outcome of sarcoidosis: an analysis of 818 patients. *Q J Med* 1983;52:525-33.
14. Chappell AG, Cheung WY, Hutchings HA. Sarcoidosis: a long-term follow up study. *Sarcoidosis Vasc Diffuse Lung Dis* 2000;17:167-73.
15. Judson MA, Baughman RP, Thompson BW, et al. Two year prognosis of sarcoidosis: the ACCESS experience. *Sarcoidosis Vasc Diffuse Lung Dis* 2003;20:204-11.
16. Rizzato G, Montemurro L. The locomotor system. In: DG James, editor. *Sarcoidosis and other granulomatous disorders*. New York: Marcel Dekker; 1994. Pp. 349-73.
17. Myers GB, Gottlieb AM, Mattman PE, et al. Joint and skeletal muscle manifestations in sarcoidosis. *Am J Med* 1952;12:161-9.
18. Wallace SL, Lattes R, Malia JP, et al. Muscle involvement in Boeck's sarcoid. *Ann Intern Med* 1958;48:497-511.
19. Dempsey OJ, Paterson EW, Kerr KM, Denison AR. Sarcoidosis. *Br Med J* 2009;339: 3206.
20. Brancaleone P, Perez T, Robin S, et al. Clinical impact of inspiratory muscle impairment in sarcoidosis. *Sarcoidosis Vasc Diffuse Lung Dis* 2004;21:219-27.
21. Moore SL, Teirstein A, Golimbu C. MRI of sarcoidosis patients with musculoskeletal symptoms. *AJR Am J Roentgenol* 2005;185:154-9.
22. Petrache I, Moller DR. Mechanisms of therapy for sarcoidosis. In: RP Baughman, editor. *Sarcoidosis*. New York: Taylor & Francis; 2006. Pp. 671-87.
23. Lynch JP, Kazerooni EA, Gay SE. Pulmonary sarcoidosis. *Clin Chest Med* 1997;18:755-86.
24. Baughmann RP, Costabel U, du Bois RM. Treatment of sarcoidosis. *Clin Chest Med* 2008;29:533-48.
25. Lazar CA, Culver DA. Treatment of sarcoidosis. *Semin Respir Crit Care Med* 2010;31:501-18.
26. Yanardag H, Tetikkurt C, Bilir M, Yılmaz E. Association of HLA antigens with the clinical course of sarcoidosis and familial disease. *Monaldi Arch Chest Dis* 2017;87:835.
27. Tetikkurt C, Yanardag H, Pehlivan M, Bilir M. Clinical features and prognostic significance of splenic involvement in sarcoidosis. *Monaldi Arch Chest Dis* 2017;87:893.
28. Fingerlin T, Hamzeh N, Maier LA. Genetics of sarcoidosis. *Clin Chest Med* 2015;36:569-84.